

# Demyelination in newly-diagnosed leprosy neuropathy

## Abstract

**Introduction:** Neural damage may occur at any time during the course of leprosy. Some patients present a neuropathy with a paucity of symptoms, known as silent neuritis.

**Case reports:** All patient nerves were altered on the sensory nerve conduction study (sNCS). Also, all the studied motor nerves of the patients presented a predominance of demyelinating lesion patterns associated with secondary axonal degeneration.

**Conclusion:** These cases stress the vital importance of more precisely understanding the pathophysiology of leprosy neuropathy so that new, more effective drugs could be developed to both prevent and/or stymie the progression of disabilities.

Volume 8 Issue 2 - 2018

Pitta Izabela Jardim Rodrigues,<sup>1,2</sup> Andrade Ligia Rocha,<sup>1,2</sup> Silveira Raquel Custódio,<sup>1,2</sup> Giesel Louise Mara,<sup>1,2</sup> Antunes Sergio Luiz Gomes,<sup>2</sup> Sarno Euzenir Nunes,<sup>2</sup> Jardim Marcia Rodrigues<sup>1,2,3</sup>

<sup>1</sup>Programa de Pós Graduação em Neurologia (PPG Neuro), Unirio (Federal University of the state of Rio De janeiro), Brazil

<sup>2</sup>Instituto Oswaldo Cruz (IOC), Fiocruz (Oswaldo Cruz foundation), Brazil

<sup>3</sup>Universidade do Estado do Rio de Janeiro, Brazil

**Correspondence:** Pitta Izabela Jardim Rodrigues, Rua Mariz e Barros 775, Rio de Janeiro, RJ, Brazil, Email [izabelap@gmail.com](mailto:izabelap@gmail.com)

**Received:** March 06, 2018 | **Published:** April 25, 2018

## Introduction

Neural damage caused by leprosy commonly presents itself as easily recognizable and treatable acute neuritis, which may occur at any time during the course of the disease.<sup>1</sup> However, some leprosy patients present what is known as “silent neuritis”, which, due to a paucity of overt symptoms, often remains unnoticed until extensive nerve damage has taken place, particularly in the multi-bacillary (MB) leprosy forms.<sup>1-5</sup>

## Case report

The three patients (two males and one female), between 40-61 years of age, then in attendance at the National Referral Center for Leprosy Treatment of the Oswaldo Cruz Foundation in Rio de Janeiro, RJ, had positive skin smears. Subsequent to being diagnosed with lepromatous leprosy (LL), multidrug therapy (MDT) for MB leprosy was initiated. They all had clinical signs of small fiber injury while one also showed large fiber injury. All three patients had normal deep tendon reflexes. None were found to have distal or proximal weakness and they did not had nerve enlargement.

The three patients were also tested via the nerve conduction study (NCS) during their first two months of MDT without any leprosy reactions at that time. Despite their exhibiting scarce clinical neural symptoms, extensive neurophysiologic nerve damage was evident. The sensory nerve conduction study (sNCS) revealed that the three patients had overall nerve alterations and an asymmetrical pattern of nerve damage. Most of the nerves studied were unresponsive and only a few had axonal or demyelinating lesions (Figure 1). In the motor nerve conduction study (mNCS), all the nerves under study presented dysfunction in an asymmetric pattern (mosaic-like polyneuropathy) as well and showed a predominance of demyelinating lesion patterns associated with secondary axonal degeneration (Figure 2).

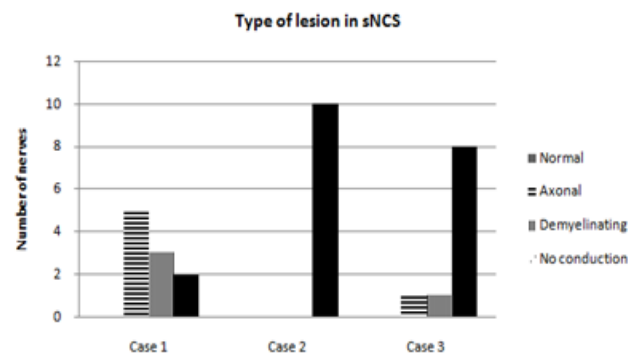


Figure 1 Type of lesion in the sensory nerve conduction studies.

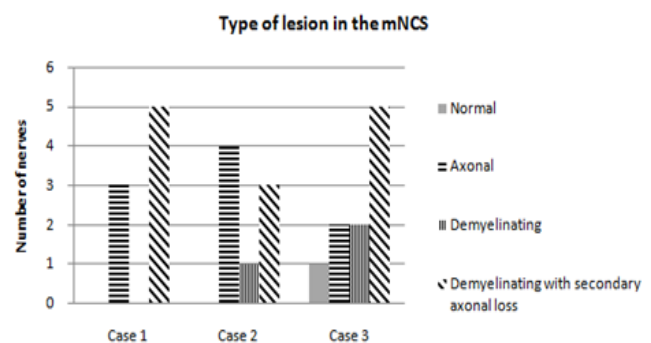


Figure 2 Type of lesion in the motor nerve conduction studies.

## Discussion

Leprosy nerve damage may occur with or without any apparent symptoms since the beginning of infection.<sup>4</sup> Early detection and treatment of nerve function impairment (NFI) are of overriding importance in leprosy in an attempt to reverse malfunction.<sup>6</sup> At leprosy diagnosis, the above patients already presented extensive, predominantly demyelinating, neuropathy accompanied by secondary axonal loss.

The symptoms of leprosy neuropathy may erupt at any point in the natural course of the disease. Defined as a painful thickening of the nerve in association with sensory impairment with or without motor symptoms, acute neuritis causes severe nerve damage. Contrariwise, nerve function impairment, or silent neuritis, has been known to take place in the total absence of acute pain.<sup>7</sup>

Early recognition of silent neuritis based on certain clinical parameters is of utmost importance in preventing disabilities, which ultimately mean the progressive worsening of neurological functions. NCS is highly useful in detecting and evaluating the extension of leprosy neuropathy,<sup>2</sup> as verified by a number of studies.<sup>5</sup> It could, for example, be used as a complementary test in an effort to detect early neuritis.

Despite the severe nerve function impairment evidenced by NCS, the patients never complained of acute pain in the affected nerves nor did they experience any nerve enlargement or tenderness, all characteristics of neuritis. They may, in fact, have had silent neuritis, in which any possible nerve injury or loss of function might be clinically determined at a later stage in the disease.<sup>8</sup>

Acute episodes of neuritis should consistently be treated with high doses of corticosteroids. However, treatment of the silent neuritis with its paucity of symptoms identified by NCS has yet to be well established.<sup>9</sup> There is evidence that these MB patients do not respond to corticosteroids as well as those with acute neuritis. These cases stress the vital importance of more precisely understanding the pathophysiology of leprosy neuropathy so that new, more effective drugs could be developed to both prevent and/or stymie the progression of disabilities.

## Acknowledgements

None.

## Conflict of interest

The author declares no conflict of interest.

## References

1. Van Brakel WH, Nicholls PG, Das L, et al. The INFIR Cohort Study: assessment of sensory and motor neuropathy in leprosy at baseline. *Lepr Rev.* 2005;76(4):277–295.
2. Van Brakel WH, Nicholls PG, Wilder-Smith EP, et al. Early diagnosis of neuropathy in leprosy--comparing diagnostic tests in a large prospective study (the INFIR cohort study). *PLoS Negl Trop Dis.* 2008;2(4):e212.
3. Capadia GD, Shetty VP, Khambati FA, et al. Effect of corticosteroid usage combined with multidrug therapy on nerve damage assessed using nerve conduction studies: a prospective cohort study of 365 untreated multibacillary leprosy patients. *J Clin Neurophysiol.* 2010;27(1):38–47.
4. Vital RT, Illaramendi X, Nascimento O, et al. Progression of leprosy neuropathy. *Brain Behav.* 2012;2(3):249–255.
5. Jardim MA, Vital RT, Hacker MA, et al. Leprosy neuropathy evaluated by NCS is independent of the patient's infectious state. *Clini Neurol Neurosurg.* 2015;131:5–10.
6. Khambati FA. Correlation between clinical and electrophysiological tests. *Lepr Rev.* 2009;80:34–50.
7. Nery JAC, Vieira LMM, Matos HJ, et al. reactional States in multibacillary disease patients during multidrug therapy. *Rev Inst Trop Sao Paulo.* 1998;40(6):363–370.
8. Jardim MR, Illaramendi X, Nascimento O, et al. Pure neural leprosy: steroids prevent neuropathy progression. *Arq Neuropsiquiatr.* 2007;65(4A):969–973.
9. Foss NT, Souza CS, Goulart IMB, et al. Projeto diretrizes. Hanseníase: Episódios Reacionais. Sociedade Brasileira de Hansenologia, Sociedade Brasileira de Dermatologia: Springer; 2003.