

Bilateral subdural hygroma in a case with sylvian arachnoid cyst

Abstract

Arachnoid cysts are congenital lesions developing from arachnoid membrane. The incidence of arachnoid cysts in the general population is around 0.1% and their most common place is middle fossa. Arachnoid cysts usually present during childhood and are identified incidentally. When symptomatic, the most common presentation includes headache and seizure. The popular treatment for this lesion is surgery. In this case report, we describe a 12-year-old boy with a middle cranial fossa arachnoid cyst presenting with progressive headache, and bilateral subdural hygroma following a trivial trauma.

Keywords: Bilateral Subdural Hygroma, Arachnoid cyst, Trauma

Volume 5 Issue 3 - 2016

Morteza Motaghdifard,¹ Ahmad Talebian,² Esmaeil Fakharian,³ Saeed Banaee,³ Amirhossein Jafarian¹

¹General physician, Kashan University of Medical Sciences, Iran

²Department of Pediatrics, Kashan University of Medical Sciences, Iran

³Department of Neurosurgery, Kashan University of Medical Sciences, Iran

Correspondence: Saeed Banaee, Assistant professor of neurosurgery, Department of Neurosurgery, Kashan University of Medical Sciences, IR Iran, Email banaee@gmail.com

Received: April 23, 2016 | **Published:** November 18, 2016

Introduction

Arachnoid cysts are congenital lesions developing within the arachnoid membrane. They are non-neoplastic, benign lesions filled with cerebrospinal fluid (CSF) or a fluid similar to it.¹ Their most common place is in the middle fossa. They are enclosed by the arachnoid membrane.^{2,3}

Arachnoid cysts are relatively rare. Their incidence in the general population is around 0.1% on the base of autopsy studies, with an estimated incidence between 0.5% and 1.6%.⁴ Arachnoid cysts most commonly present during childhood and are usually identified incidentally. About 75% of intracranial arachnoid cysts presented before 3 years of age in one series.⁵ The most common symptoms include headache and seizures.

When there is hydrocephalus or intracranial hypertension the common treatment is surgery.⁶

Intracranial hypertension secondary to arachnoid cyst rupture especially in the subdural space is a rare clinical entity.^{7,8}

In this case report, we describe a 12 year old boy with bilateral subdural hygroma and a middle cranial fossa arachnoid cyst presenting with progressive headache following a trivial head trauma. Based on our best knowledge this is not reported in the literature.

Case presentation

A 12-year-old boy had a falling down while playing about 40 days before his admission to the hospital. His occiput was injured in the event.

He had only dizziness immediately after trauma for 2-3 minutes but had no laceration, bleeding, nausea, vomiting, loss of consciousness (LOC), seizure, post-traumatic amnesia (PTA), etc. He had mild, left parietal beating headache that gradually changed to a generalized one associated with nausea and progressive non bloody vomiting, 3 days after trauma. Vomiting was correlated with eating.

He was referred to neurosurgery clinic. On neurological examination his optic disk was flat and cranial nerves were normal.

His meningeal signs were positive. Computed tomographic (CT) scan of brain (Figure 1) showed a hypo-dense lesion in left middle cranial fossa with some squeezing of the ventricular system without midline shift. Brain magnetic resonance imaging (MRI) showed the lesion in the same place, widening Sylvian fissure, compressing temporal lobe and squeezing lateral ventricles. It had the same intensity as cerebrospinal fluid (CSF). There was also fluid collection in both frontal subdural spaces hypo-intense on T1 Figure 2 and hyper-intense on T2 images Figure 3. The findings were suggestive of Sylvian fissure arachnoid cyst and bilateral subdural hygroma.

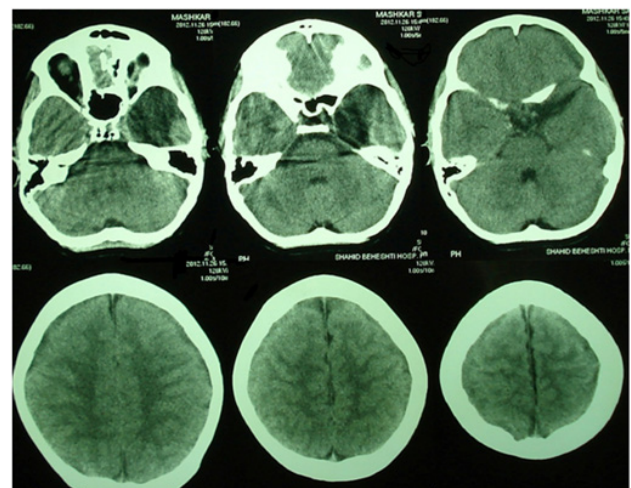


Figure 1 Brain CT scan revealed an extra-axial cystic lesion in the left middle cranial fossa and Sylvian fissure suggestive of arachnoid cyst.

He was admitted to hospital for craniotomy, fenestration and marsupialization of the cyst into subarachnoid spaces, and evacuation of hygroma. Postoperative imaging Figure 4 showed resolution of subdural hygroma with small extracranial collection of CSF. He discharged from hospital in good condition with disappearance of all of his complains. In follow up visit, he had no meningeal signs. His neurologic examination was also normal.

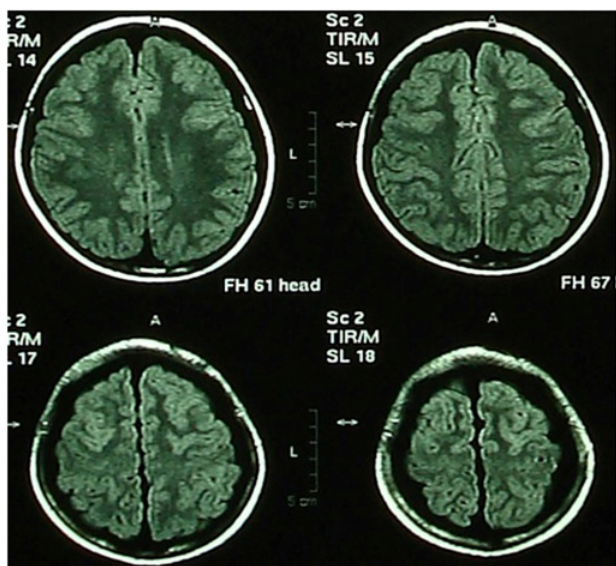


Figure 2 Magnetic resonance imaging of brain showed T1W subdural hypointensity in the left middle fossa compressing temporal lobe and bilateral fronto-parietal convexities.

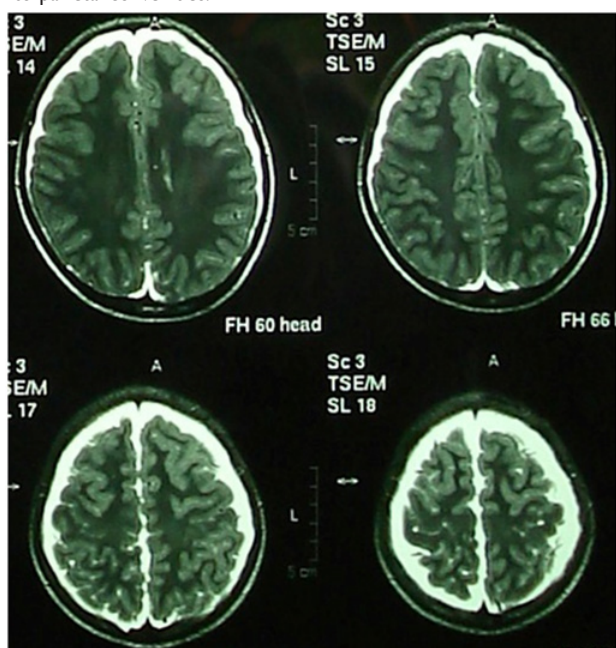


Figure 3 Magnetic resonance imaging of brain. showed T2W subdural hyperintensity in the temporal region and bilateral convexities compressing temporal lobe on the left side.

Discussion

Intracranial arachnoid cysts are congenital malformations that form by the splitting of the arachnoid membranes due to an increased pulsation of the CSF.⁹

They are considered intra arachnoidal in location and account for 1% of the intracranial mass lesions.¹⁰ They are located in the middle cranial fossa in 25-80% of cases. Almost all of these cysts are unilateral, with a slight predilection for the left side.¹¹

A progressive increase in cyst volume may occur in many cases.¹² Intra-cystic hemorrhage, an osmotic gradient allowing a passive fluid-diffusion into the cyst, a ball-valve mechanism or an active secretion

from the cyst wall and pulsation of intracystic fluid of venous or arterial origin are some theories for explaining the cyst growth.^{10,13,14}

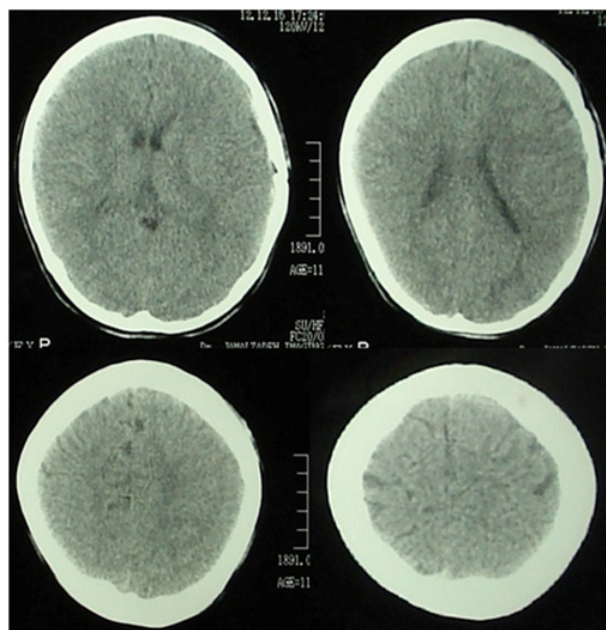


Figure 4 Post-op brain CT scan revealed resolution of bilateral subdural hygroma with small extracranial collection of the CSF.

Surgical indications and techniques should be based on the type of arachnoid cyst (communicating or non-communicating), growth of the cyst, compression or displacement of the surrounding neurovascular structures, and most importantly the patient's symptomatology and on-going clinical course.

Sixty to ninety percent of arachnoid cysts present during childhood.^{15,16} Clinical presentation varies primarily by age and location of the lesion. Some arachnoid cysts remain asymptomatic throughout life.

The most common presenting symptom is headache, which may be due to local mass effect, high intracranial pressure (ICP), or hydrocephalus.¹⁷ Arachnoid cysts of the middle cranial fossa may be associated with hemorrhage, but this complication has been considered very infrequent. Hemorrhage into or around an arachnoid cyst is primarily precipitated by minor trauma and, very rarely, can be spontaneous. Several reports have been published on the association of arachnoid cysts with subdural hygroma and subdural hematoma after minor head injuries.^{7,8,16,20}

Arachnoid cysts may cause cognitive disorders and deficits of any aspect of psychologic system.¹⁸

Even a trivial trauma can cause rupture of the cyst as seen in the presented case, where a simple falling down while playing resulted in the formation of hygroma.

The indication for surgery and the mode of surgical treatment are still a matter of debate. Different types of surgical approaches can be performed. Cyst fenestration, stereotactic puncture, endoscopic cyst fenestration, cystoperitoneal shunt, cyst marsupialisation into the subarachnoid space and complete or partial resection of the cyst wall are the main options.¹⁹

Although the risk of hemorrhage of arachnoid cyst is very low but when the hemorrhage occurs it is treated by hematoma evacuation in most cases, but sometimes there is a need for fenestration of the cyst

into basal cisterns by endoscopy, microsurgical or cystoperitoneal shunt.²⁰

In our case, patient age, minority of trauma and symptomatology were similar to what is reported in literature, but formation of subdural hygroma in both sides of the brain where falx cerebri acts as a barrier cannot be explained and this is the interesting point in our report which mandates specific attention to this quaint case.

Conclusion

In patients with arachnoid cyst it is important to keep in mind that a trivial event can produce a significant intracranial complication, in both sides of the brain.

Acknowledgments

None.

Conflicts of interest

None.

References

1. Van B, Sarioglu AC, O Donnell HD. Supratentorial arachnoid cyst with intracystic and subdural hematoma. *Neurochir*. 1992;35(6):199–203.
2. Kotil K, Balci N, Bilge T. Intracranial Symptomatic Giant Arachnoid Cyst of the Interhemispheric Fissure Presenting With Frontal Lobe Syndrome. *Tur Neurosur*. 2007;17(2):147–51.
3. Yamasaki F, Kodama Y, Hotta T, et al. Interhemispheric arachnoid cyst in the elderly: case report and review of the literature. *Surg Neurol*. 2003;59(1):68–74.
4. Schievink WI, Huston J III, Torres VE, et al. Intracranial cysts in autosomal dominant polycystic kidney disease. *J Neurosurg*. 1995;83(6):1004–1007.
5. da Silva JA, Alves A, Talina M, et al. Arachnoid cyst in a patient with psychosis: Case report. *Ann Gen Psychiatry*. 2007;6:16.
6. Gelabert Gonzalez M. Intracranial arachnoid cysts. *Rev Neurol*. 2004;39(12):1161–1166.
7. Rajesh A, Bramhaprasad V, Purohit AK. Traumatic rupture of arachnoid cyst with subdural hygroma. *J Pediatric Neuroscience*. 2012;7(1):33–55.
8. Kertmen H, Güreş B, Yilmaz ER, et al. Chronic subdural hematoma associated with an arachnoid cyst in a juvenile taekwondo athlete: a case report and review of the literature. *Pediatr Neurosurg*. 2012;48(1):55–58.
9. Haberkamp TJ, Monsell EM, House WF, et al. Diagnosis and treatment of arachnoid cysts of the posterior fossa. *Otolaryngol Head Neck Surg*. 1990;103(4):610–614.
10. Laribi S, Chakroun O, Segal N. *Intracranial symptomatic giant arachnoid cyst*, Signa Vitae. 2012;7(1):43–45.
11. Iaconetta G, Esposito M, Maiuri F, et al. Arachnoid cyst with intracystic hemorrhage and subdural hematoma: case report and literature review. *Neurol Sci*. 2006;26(6):451–455.
12. Berens P, Ostertag CB. Zystische Fehlbildungen des Gehirns: Stereotaktische Diagnostik und Therapie. *Nervenarzt*. 1992;63:725–730.
13. Cao GX. Intracranial arachnoid cyst: report of 23 cases. *Zhonghua Wai Ke Za Zhi*. 1989;27(7):426–427.
14. Rengachary SS, Watanabe I. Ultra structure and pathogenesis of intracranial arachnoid cysts. *J Neuropathol Exp Neurol*. 1981;40(1):61–83.
15. Higashi S, Yamashita J, Yamamoto Y, et al. Hemifacial spasm associated with cerebellopontine angle arachnoid cyst in a young adult. *Surg Neurol*. 1992;37(4):289–292.
16. Prabhu VC, Bailes JE. Chronic subdural hematoma complicating arachnoid cyst secondary to soccer-related head injury: Case report. *Neurosurgery*. 2002;50(1):195–198.
17. Clemenceau S, Carpenter A. Intracranial arachnoid cyst. *Rev Neurol*. 1999;155(8):604–608.
18. Bidaki R, Amin MA. Case of Conversion Disorder Associated With an Arachnoid Cyst. *ASEAN Journal of Psychiatry*. 2012;13(1).
19. Bourekas EC, Raji MR, Dastur KJ, et al. Retroclival arachnoid cyst. *AJNR Am J Neuroradiol*. 1992;13(1):353–354.
20. Meshkini A, Meshkini M. Two case series reports: 8 cases of Arachnoid Temporoparietal cysts (Middle Fossa & Sylvian fissure) and 2 cases of chronic subdural hematoma: Injury & violence journal. 2012;4(3 Suppl 1).