

# Evaluation of Late Onset Congenital Aqueductal Stenosis Hydrocephalus

## Abstract

Early onset hydrocephalus due to congenital aqueductal stenosis is well known and fully studied. However, late onset one is not so. The present study is a trial to give spotlight on the late onset type which may be clinically confusing with other syndromes leading sometimes to mismanagement.

Our study included 25 patients with late onset congenital aqueductal stenosis hydrocephalus. They verified into 18 males (72%) and 7 females (28%). Their ages ranged from 5 years to 64 years. They presented with headache in 19 cases (76%), visual disturbance in 11 cases (44%), gait disturbance in 8 cases (32%) and disturbed level of consciousness in 4 cases (16%). Ventriculoperitoneal shunts were done for all cases with improvement in 20 cases (80%), no improvement in 3 cases (12%) and deterioration in 2 cases (8%). Post-shunt complications occurred in 9 cases (32%) and include 6 cases with subdural hematoma (24%), 2 cases with infection (8%) and one case with shunt obstruction (4%).

Late onset aqueductal stenosis hydrocephalus is not uncommon cause of hydrocephalus in our locality. Proper diagnosis and management of such patients depended on the well manifest clinical data confirmed with the neuroimaging studies became easy.

**Keywords:** Ventriculoperitoneal shunt, Aqueductal stenosis

Volume 5 Issue 1 - 2016

**Hassan Mohammed, Abd elhakim abd elsatar, Mahmoud Ragab, Ahmed Alghriany**  
 Neurosurgery Department, Assiut University Hospital, Assiut, Egypt

**Correspondence:** Hassan Mohammed, Neurosurgery Department, Assiut University Hospital, Assiut, Egypt, Email h\_moh\_h@yahoo.com

**Received:** December 19, 2015 | **Published:** July 11, 2016

## Introduction

Aqueductal stenosis is responsible for 20% of cases of hydrocephalus. Its incidence ranges from 0.5 to 1.0 in 1,000 births, with a recurrence risk in siblings of 1.0% to 4.5%. The onset of symptoms is usually insidious and can occur at any time from birth to adulthood. Associated malformations in neighboring structures are common. The presence of these malformations helps to explain the intellectual, cognitive, and motor handicaps even after the hydrocephalus is compensated by shunting. Aqueductal obstruction constitutes three percent of adult hydrocephalus.<sup>1</sup>

According to the histopathological classification of Russell,<sup>1</sup> non-tumoral aqueduct stenosis can be subdivided into four types: Stenosis, Forking, Septum formation and Gliosis. Congenital aqueductal stenosis can present later in adult age due to compensation of CSF flow dynamics during childhood and normalization of clinical symptoms are more important in evaluating the benefits of treatment than in the decrease in ventricular size.

Hydrocephalus secondary to aqueductal stenosis may present at any age. Clinical course may vary, according to the patient's age and the anatomical deformation of the ventricular system. Imaging with CT and MRI will show dilated third and lateral ventricles with marked upward bowing of corpus callosum. Treatment of hydrocephalus secondary to aqueductal stenosis can be achieved with implantation of extracranial shunt, such as ventriculo-peritoneal (VP) or ventriculoatrial shunts, or by the means of neuroendoscopy (ETV).<sup>1</sup>

The most common shunt complications include: infection, obstruction and overdrainage. Prognosis of patients with aqueductal stenosis does not depend only on promptness and efficacy of surgical treatment. Better outcome is observed in post-natal than congenital hydrocephalus.<sup>1</sup>

This study evaluates hydrocephalus due to late onset congenital aqueductal stenosis regarding preoperative patients' characteristics

(demographic data and clinical presentations), operative management, and postoperative patients' characteristics (complications and outcome).

## Patients and methods

This study included 25 patients with late onset congenital Sylvius aqueductal stenosis admitted to the neurosurgery department in Assiut University Hospital from March 2012 till March 2013. In this study, the patients were subjected to the following inclusion and exclusion criteria

### A-Inclusion criteria:

- Patient complaining of manifestation of increased intracranial pressure, gait disturbance, urinary troubles, visual deterioration and/or disturbance of the conscious level.
- (Age of the patient should exceed 4 years of age as there is no universal agreement on the age of late onset aqueductal stenosis).

### B-Exclusion criteria:

- Post meningitic and post encephalitic aqueductal stenosis.
- Post traumatic aqueductal stenosis.
- Post hemorrhagic aqueductal stenosis.
- Patients having brain tumors compressing the aqueduct of Sylvius.

All patients included in this study were subjected to the following:

1. full general and neurological history and examination.
2. History: Presenting concerns:
3. Headache, vomiting, visual disturbance, somnolence
4. Physical Examination

- Vital signs: In advanced acute hydrocephalus, Cushing triad (hypertension, reflex bradycardia, respiratory irregularities).
  - Mental status: behavioral changes in children (acute or chronic)
  - Motor: Gait ataxia; spastic paraparesis in chronic hydrocephalus related to pressure on white matter tracts surrounding the ventricles
  - Reflexes: Increased in chronic hydrocephalus
5. Fundus examination
  6. Neuroimaging studies:
    - Unenhanced CT of the brain.
    - MRI.
  7. Routine lab investigations:
    - Complete blood picture.
    - Prothrombin time and concentration.
    - Renal function tests.
    - Blood sugar level.
  8. Surgical treatment:
  9. External ventricular shunt, where ventriculoperitoneal shunts were done for all patients and all shunt devices were PS whatever the pressure valves (Meditronic Neurosurgery 125 cermon Drive, Goleta, Cag3117USA)

## Results

Our study included 25 patients with late onset congenital aqueductal stenosis hydrocephalus.

In Table 1, patients were divided into 3 age groups. The highest incidence of late onset aqueductal stenosis was in the age group between (41-60) (44%) followed by the age group between (5-20) (36%), while the age group which showed least figures was the age group between (21-40) (20%).

Table 1, also showed sex predilection, where the highest incidence was in males in general (72%) while the females were just (28%). Females showed a significant peak in the age group between 5-20 years (44.4%) whereas the males were dominant in all the age groups especially the age group between 41-60 years (81.8 %) (Figure 1).

**Table 1** Relation between sex and age groups

Age group	Male No.(%)	Female No.(%)	P value
Age group 5-20 years	5 (55.6%)	4 (44.4%)	0.15
Age group 25-40 years	4 (80%)	1 (20%)	
Age group 40-64 years	9 (81.8%)	2 (18.2%)	
Total	18 (72%)	7 (28%)	

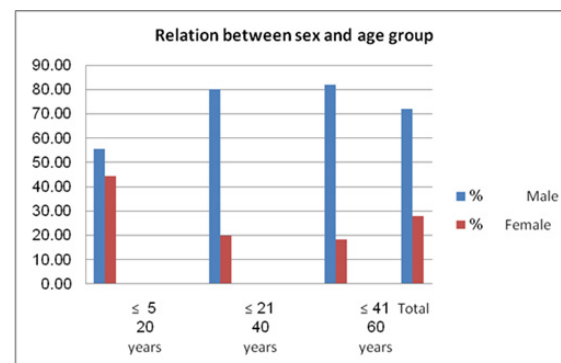
Table 2, shows the demographic distribution as 64% of the patient were from Assiut city itself, whereas only 36% of the patient were from other cities, also shows that majority of cases were married (64%) while only (36%) were singles. Regarding occupation, there was a significant percent of the patient who don't work (72%) while only (28%) were working (p=0.03) (Figure 2).

**Table 2** Numbers and percent of cases in relation to demographic data

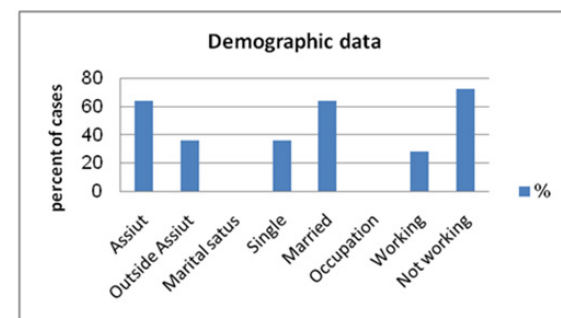
Demographic data	No.(%)
<b>Residence</b>	
Assiut	16 ( 64 %)

Table Continued...

Demographic data	No.(%)
Outside Assiut	9 (36%)
<b>Marital status</b>	
Single	9 (36%)
Married	16 (64%)
<b>Occupation</b>	
Working	7 (28%)
Not working	18 (72%)



**Figure 1** Relation between sex and age groups.



**Figure 2** Numbers and percent of cases in relation to demographic data.

Table 3 shows significant longer duration of illness among the age group (21-40) in comparison to the duration of the other age groups.

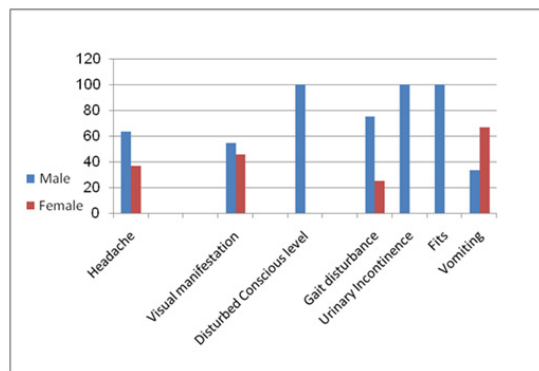
Table 4 showed that the headache as a presenting manifestation has the highest incidence (76%) followed by visual manifestation (44%) whereas the urinary incontinence showed the least incidence (4%) (Figure 3).

**Table 3** Relation between age group of the cases and duration of manifestation

	Duration (months)	Mean±SD	Range
Total group (years) 5-60	50.2±62.8		1-270
Age group 5-20	56±88.2		7-270
Age group 21-40	60.8±86.8		2-210
Age group 41-60	50.8±6.9		3-120
P value	0.04		

**Table 4** Clinical manifestation of the studied patients. N.B: Most of the patients had more than one clinical presentation

	Total No. (%) No=25	Male No=18	Female No=7
Headache	19(76%)	12(63.2%)	7(36.8%)
Visual manifestation	11(44%)	6(54.6%)	5(45.5%)
Disturbed Conscious level	4(16%)	4(100%)	0(0%)
Gait disturbance	8(32%)	6(75%)	2(25%)
Urinary Incontinence	1(4%)	1(100%)	0(0%)
Fits	2(8%)	2(100%)	0(0%)
Vomiting	3(12%)	1(33.3%)	2(66.7%)

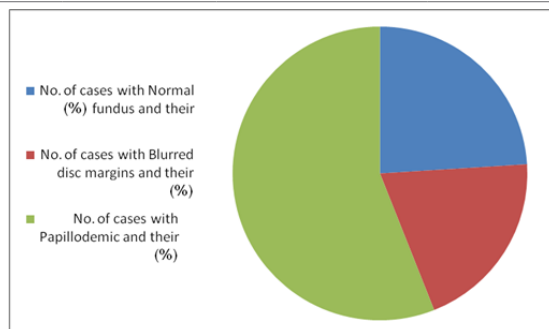


**Figure 3** Clinical manifestation of the studied patients. N.B: Most of the patients had more than one clinical presentation.

Table 5 showed that there is relationship between affection of fundus and late onset congenital aqueductal stenosis (Figure 4).

**Table 5** Relation between late onset congenital aqueductal stenosis and fundus examination

Total No. of cases	No. of cases with Normal fundus	No. of cases with Blurred disc margins	No. of cases with Papilloedema
25	6	5	14

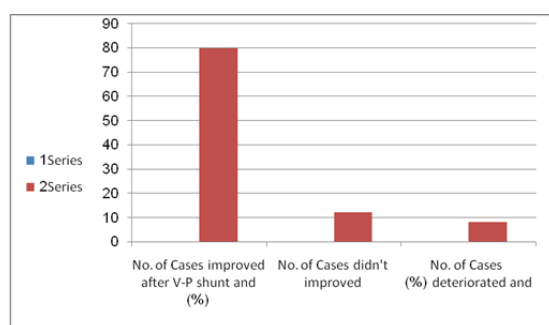


**Figure 4** Relation between late onset congenital aqueductal stenosis and fundus examination.

Table 6 showed the marked improvement of the cases after application of the shunt in 80% whereas only 12% of the cases didn't improve, and just 8 % showed deterioration (Figure 5).

**Table 6** Outcome of the patients after V-P shunt insertion

Total No. of the cases of late onset congenital aqueductal stenosis	No. of Cases improved after V-P shunt and (%)	No. of Cases didn't improved after V-P shunt and (%)	No. of Cases deteriorated and (%)
25	20(80%)	3(12%)	2(8%)



**Figure 5** Outcome of the patients after V-P shunt insertion.

Table 7 showed that only 36 % of the cases showed postoperative complications.

**Table 7** Schedule showing the incidence of the complications after shunt operation

No. of cases passed without any complications after shunt insertion and their percent (%)	No. of cases developed complication after shunt insertion and their percent (%)			Total No. of cases treated with V-P shunt
	Shunt obstruction	Shunt Infection	Subdural hamaetoma	
16(64%)	1(4%)	2(8%)	6(24%)	25

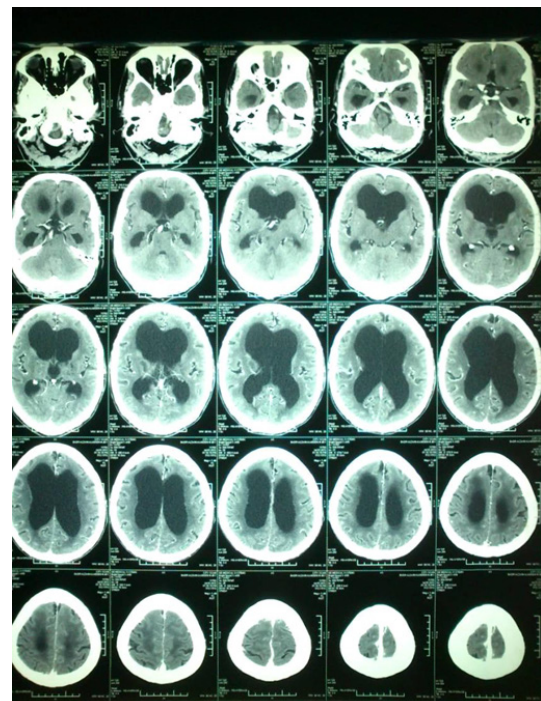
## Case presentations

### Case 1

A fifty eight years old male patient presented with urinary incontinence, ataxia, and headache of 4 month duration. Fundus examination showed blurred disc margins. The CT scan showed dilatation of lateral and 3rd ventricles. A ventriculoperitoneal shunt was inserted, but the patient didn't improve and moreover became comatose. The CT scan was done and showed bilateral chronic subdural haematomas which were surgically evacuated via 4 burr holes with upgrading of shunt device and the patient afterward improved (Figure 6 & 7).

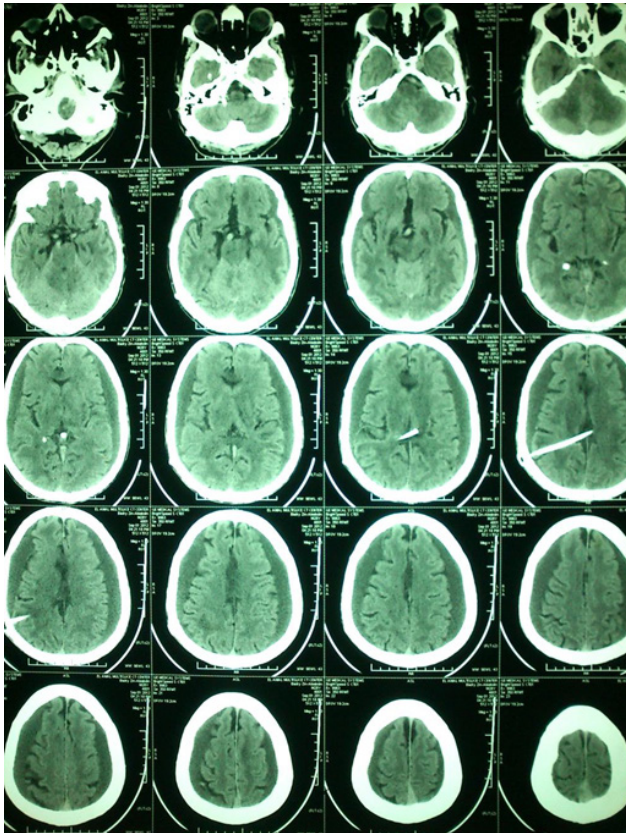
### Case 2

Female patient, 16 years old presented with headache and decreased intellectual performance. MRI revealed dilated 3<sup>rd</sup> and lateral ventricles. Ventriculoperitoneal shunt was done with no postoperative improvement. The patient presented one month later by the disturbed level of consciousness, left sided hemiparesis and urine incontinence. CT brain showed development of bilateral subdural hematoma and patient improved after evacuation of the hematoma and shunt upgrading (Figure 8-10).

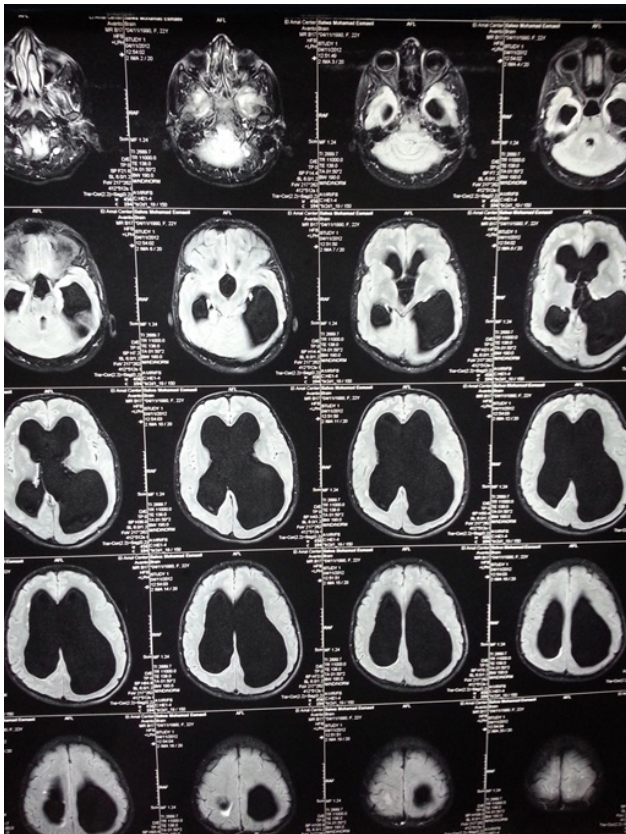


**Figure 6** Preoperative CT showing late onset congenital aqueductal stenosis where there are dilatation of the lateral and 3rd ventricles while the 4th ventricle is normal.

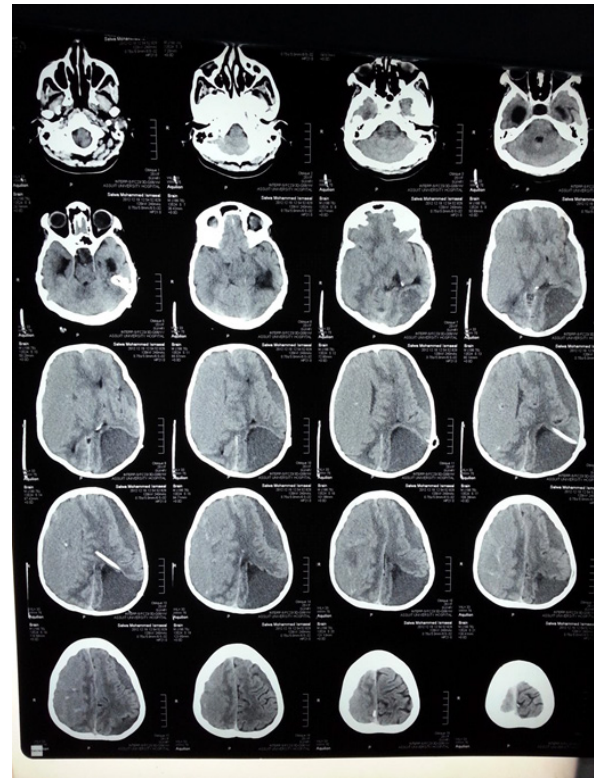




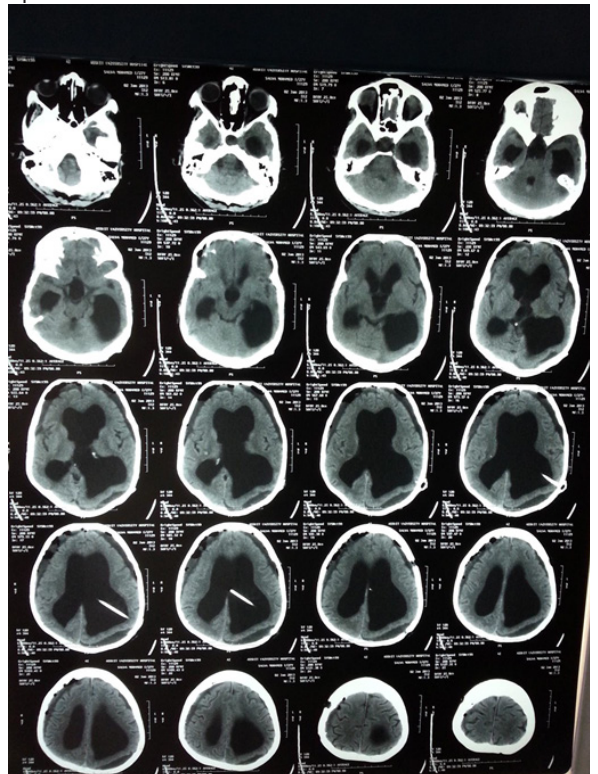
**Figure 7** Postoperative CT showing development of bilateral subdural haematoma after shunt insertion as a result of overdrainage Case No. 1.



**Figure 8** Preoperative MRI brain of case No. 2.



**Figure 9** Postoperative CT brain of case No.2 showed postshunting developed subdural hematoma at the same side.



**Figure 10** Case 2: CT Brain after evacuation of bilateral SDH.

## Discussion

Aqueductal obstruction constitutes 3% of adult hydrocephalus.<sup>2</sup> Aqueductal Stenosis is usually a malformation occurring as a sporadic



developmental anomaly. There are 4 main types of aqueductal obstruction.

- The aqueduct is narrowed or obliterated, and ependyma lines the lumen without gliosis of the surrounding tissue. In cases of “simple stenosis”, an abnormally small aqueduct with normal cells is present. In cases of “congenital atresia”, the aqueduct may not be discernible on gross inspection. This is the form most probably due to “developmental” errors in which abnormal infolding of the neural plate results in narrowing of the neural tube with the cleaning of the lumen.<sup>3</sup>
- Forking. The aqueduct is divided into two or more separate channels. These channels can communicate with each other, can enter the ventricle independently, or end blindly. This condition, that results from incomplete fusion of the median fissure, usually reduces aqueductal lumen and/or perturb the laminar flow of CSF.<sup>3</sup>
- Septum formation. The aqueduct is totally or in part obstructed by a gliotic membrane. This is usually located at the lower end of the aqueduct and occurs when the glial overgrowth is restricted to the lower end of the aqueduct, that gradually becomes a tiny sheet from prolonged pressure and dilatation of the canal above.<sup>4</sup>
- Gliosis. Gliotic stenosis is characterized by proliferation of glial cells and overproduction of glial fibers. The residual lumen is not outlined by ependyma. Glial proliferation is usually a reaction to irritant agents, such as hemorrhage, infection, or toxic agents, and is often part of a widespread ependymitis of the ventricles. Obstruction of the aqueduct by reactive gliosis has to be distinguished from subependymal astrocytomas.<sup>3</sup>

Despite its’ congenital origin, the alterations of the CSF dynamics can remain compensated and undiagnosed for several years.<sup>2</sup> Clinical features in the compensated stage include episodes of headache and nausea, that are more severe in the morning because CSF is drained less in the recumbent position and is relieved by sitting up. There may be an even development of cognitive function with changes in behavior.

The patient may also present with an endocrine disorder due to the distraction of the hypothalamus and pituitary stalk by a grossly dilated third ventricle. The patient may also present with failure of upward gaze and accommodation due to pressure on the tectal plate.

In the late acute decompensated stage, the patient may present with vomiting, drowsiness and episodes of graying out of vision due to increased intracranial pressure. The patient may also have a spastic weakness of lower limbs with gait disturbance due to stretching of pyramidal tract around dilated third ventricle.

On physical examination, head circumference may be normal or only slightly increased. Imaging with CT and MRI will show dilated 3rd and lateral ventricles with a marked upward bowing of corpus callosum. The normal aqueductal CSF flow void in MRI cine phase contrast won’t be seen, indicating obstruction to CSF flow through the aqueduct.<sup>5</sup>

Interstitial edema around the dilated ventricles will not be seen in the compensated stage of obstruction. MRI offers better morphological definition of the ventricles and shows some causal lesion like web.

MRI with cine phase CSF velocity study has improved diagnosis of this type of hydrocephalus by illustrating the aqueductal stenosis.<sup>5</sup>

The treatment option in the compensated stage is with drugs like acetazolamide and frusemide to limit the evolution of hydrocephalus by decreasing fluid secretion by choroid plexus.<sup>6,7</sup>

In late decompensated stage, the treatment option is surgical. In cases of shunt procedures CSF flow velocity imaging by MRI can show the patency of the shunt.

The present study included 25 patients with late onset congenital sylvius aqueductal stenosis admitted and managed at the neurosurgery department in Assiut university hospital from March 2010 till march 2011. In these patients, the cause of the hydrocephalus was the late onset aqueductal stenosis.

In the present study, we divided the age group into 3 subgroups and found that the highest incidence of late aqueductal stenosis was in the age group between 41-64 years (44%) followed by the group between 5-20 years (36%), while the age group which showed least figures was the age group between 21-40 years (20%).

When we compared the sex predilection in this study, we found that the higher incidence occurs in males in general (72%) while the females were just (28%). The females showed a significant rise in the age group between 5-20 years with a percent of (44.4%) whereas the males were dominant in all the age groups, especially the age group between 41-64 years with a percent of (81.8%).

The demographic distribution showed that there was a significant percent of the patients who don’t work (72%) while only (28%) were working (p=0.03). In the present study, headache as a presenting manifestation has the highest incidence (76%) followed by visual manifestation (44%), whereas the urinary incontinence showed the least incidence (4%).

Other studies showed that headache occurs in approximately 50% of adult patients.<sup>8</sup> It has been suggested to be caused by raised intracranial pressure because of impaired flow within the ventricular system and may be associated with other unspecific signs of elevated intracranial pressure, such as transient visual scotomas, diplopia, tinnitus and papilloedema.<sup>9</sup>

The present study showed the marked improvement of the cases after application of the shunt 80%, whereas only 12% of the cases didn’t improve, and just 8% showed deterioration. The present study showed that only 36% of the cases showed postoperative complications (4% of the cases showed shunt obstruction and 8% showed shunt infection, and 24% showed post shunting subdural haematoma).

Other study<sup>10</sup> showed that mechanical obstruction had occurred in 14% of cases. This may occur at either or both ends, but usually due to obstruction of ventricular catheter by entrapped choroid plexus tissue, intraventricular debris or gliosis around the catheter tip. This incidence is highest in early postoperative period and decreases with time. We had proximal obstruction in six of the seven cases. Distal obstruction is due to accumulation of debris in the slit valve. The dead space beneath the slit valve favors this accumulation. Debris is composed of acellular fibrin clumps surrounded by a large number of macrophages, lymphocytes and fibroblasts. We had one patient with peritoneal end blockage by tissue debris.

The second most common complication of these procedures is infection. This occurs in 5 to 10% of the cases and is usually the result of prior infection of CSF or infection introduced during surgery. Ventriculitis, meningitis and local wound infection are the most common clinical manifestations. The infection rate in that study is 12%. Infection is generally due to organisms of low virulence, most commonly *Staphylococcus epidermidis*.<sup>11</sup> *Staphylococcus aureus*, Gram negative bacilli and mixed pathogens are the next most common agents encountered. The organism cultured in our series was predominantly the *Staphylococcus* species.

The most common complication was post shunting subdural haematoma. This occurred in 6 patients (24%). This possibly happened due to rapid drainage of the CSF with ventricular collapse, so we recommend intraoperative measuring of intraventricular pressure to select proper shunt pressure, otherwise we recommend to insert a high pressure valve.

## Conclusion

Our study included 25 patients with late onset congenital aqueeductal stenosis. The highest incidence of late onset aqueeductal stenosis was in the age group range between 41-60 years (44%) followed by the age group between 5-20 (36%). Late onset hydrocephalus were more frequent among males (72%) than females (28%). Headache as a presenting manifestation has the highest incidence (76%) followed by the visual manifestation (44%) whereas the urinary incontinence showed the least incidence (4%).

Marked improvement of the cases after application of the shunt 80%, whereas only 12% of the cases didn't improve, and just 8% showed deterioration. Complication of the operation were recorded in 36% of the cases (4% of the cases showed shunt obstruction, 8% showed shunt infection, and 24% showed post shunting subdural haematoma). The most common complication was post shunting subdural haematoma. This possibly happened due to rapid drainage of the CSF with ventricular collapse. Infection was the second most common complication of these procedures it may be related to prior infection of CSF or infection introduced during surgery. Ventriculitis, meningitis and local wound infection are the most common clinical manifestations.

## Recommendations

Late onset aqueeductal stenosis, congenital hydrocephalus is not uncommon cause of the hydrocephalus in our locality. Detection and management of such patients with the well manifest clinical data confirmed with the neuroimaging studies became easy. We recommend detailed multicentric studies to overcome our restricted number of cases which were studied in short time (one year).

## Acknowledgments

None.

## Conflicts of interest

None.

## References

1. Russell DS. Observations on the pathology of hydrocephalus. Medical Research Council special report series, no. 265. London: His Majesty's Stationery Office. *Ulster Med J.* 1949;18(1):107-108.
2. Rekalte HL. The definition and classification of hydrocephalus: a personal recommendation to stimulate debate. *Cerebrospinal Fluid Res.* 2008;5:2.
3. Jellinger G. Anatomopathology of nontumoral aqueeductalstenosis. *J Neurosurg Sci.* 1986;30(1-2):1-16.
4. Turnbull IM, Drake CG. Membranous occlusion of the aqueduct of Sylvius. *J Neurosurg.* 1966;24:24-33.
5. Tofts P. Quantitative MRI of the brain: *Measuring changes caused by disease.* John Wiley & Sons, USA. 1999.
6. Carrion E, Hertzog JH, Medlock MD, et al. Use of acetazolamide to decrease cerebrospinal fluid production in chronically ventilated patients with ventriculopleural shunts. *Arch Dis Child.* 2001;84(1):68-71.
7. Aimard G, Vighetto A, Gabet JY, et al. Acetazolamide: an alternative to shunting in normal pressure hydrocephalus? *Preliminary results.* *Rev Neurol (Paris).* 1990;146(6-7):437-439. [Article in French].
8. Tisell M, Edsbacke M, Stephenson H, et al. Elastance correlates with outcome after endoscopic thirdventriculostomy in adults with hydrocephalus caused by primaryaqueeductal stenosis. *Neurosurgery.* 2002;50(1):70-77.
9. Fukuhara T, Luciano M. Clinical features of late-onsetidiopathic aqueeductal stenosis. *Surg Neuro.* 2001;55(3):132-137.
10. Ahmed A, Sandlas G, Kothari P, et al. Outcome analysis of shunt surgery in hydrocephalus. *J Indian Assoc Pediatr Surg.* 2001;14(3):875-916.
11. Bayston R. Epidemiology, diagnosis, treatment, and prevention of cerebrospinal fluid shunt infections. *Neurosurg Clin N Am.* 2001;12(4):703-708.