

Adult variant of ophthalmologic migraine with recurrent 6th cranial nerve palsy in 25yrs old ethiopian patient: case report

Abstract

According to ICHD-3 ophthalmoplegic migraine (OM) is classified under Painful Cranial Neuropathies and other Facial Pains and the name is changed from Ophthalmoplegic migraine to Recurrent Painful Ophthalmoplegic Neuropathy (RPON). First described by Gubler in 1860, who described a patient who had recurrent episodes of 3rd Cranial nerve Paresis during otherwise typical migraine attacks. The paresis persisted beyond the headache phase of the attack, as evidence support more than 24hrs. After three decades in 1890, Charcot called this condition "Ophthalmoplegic Migraine". It's characterized by repeated attacks of paresis of one or more ocular cranial nerves (commonly the oculomotor Nerve), occasionally cranial IV and VI with ipsilateral headache. Ophthalmoplegic 'migraine' incidence was rare in the general population, more happened in children, with incidence of 0.7 per 1,000,000 in general population. Different pathogenesis is postulated currently including, ischemia, compressive and demyelinating causes. Though frequent involvement of 6th cranial nerve is not common according to previously published articles, we report a 25yrs old female patient who presented with two episode of 6th cranial nerve palsy preceded by unilateral throbbing type of headache in which the first episode occurs 6yrs back and resolve within 4 weeks, the current left side abducent palsy is preceded by 3 days history of ipsilateral throbbing headache pain, in which patient complexly recovered after 10 weeks treatment of amitriptyline 25mg daily.

Keywords: Ophthalmoplegic migraine, Painful cranial neuropathies and other facial pains, Recurrent painful ophthalmoplegic neuropathy

Volume 4 Issue 6 - 2016

Biniyam Alemayehu Ayele, Getahun Mengistu, Abdinasir Wako Abo

Department of Neurology, Addis Ababa University, Ethiopia

Correspondence: Biniyam Alemayehu Ayele, Department of Neurology, Addis Ababa University, Ethiopia, Tel 2510939934785
Email biniyam.7@gmail.com

Received: May 25, 2016 | **Published:** June 24, 2016

Presentation of the case

A 25- years- old female patient with a history of migraines like headaches since ten years back, presented to Black lion specialized hospital Neurology Referral clinic with a three week history of the left temporal throbbing type of headache, with associated photophobia, but no associated nausea and vomiting. The patient denies preceding aura. Three days following the headache patient developed double vision and difficulty moving left eye laterally. She visited a different physician for her current condition, but didn't have improvement where she was finally referred to us. Six years back patient had the same episode of headache associated with double vision, which improved by itself within 4 weeks. Since then she had an episodic unilateral headache 3-4 times annually otherwise she has no dropping of eyelids, decreased vision, extremity weakness or numbness of extremity. She denies having vomiting, loss of consciousness or abnormal body movement. Her mother had the migraine like headache, but not frequently bothering her. The patient never took any anti-migraine and Prophylactic treatment.

Examination

The patient is comfortable, but complaining of mild left side temporal throbbing type of headache otherwise not in any form of distress. BP was 110/70mmHg, and height of 158cm, weight was 51kg, BMI of 20.4. On extra ocular muscle examination patient had difficulty abducting the left eye (left side abducent palsy), normal oculomotor and trochlear nerves. Normal sized and reactive pupil bilaterally, no ptosis, and the rest of cranial nerves are normal. Fundoscopic examination was unremarkable and there was no exophthalmos. Normal cognitive function deficit, normal motor and sensory function in all extremities. Normal coordination and gait. She has Negative meningeal signs.

Laboratory work up

Complete blood counts, erythrocyte Sedimentation rate, blood sugar, liver function, renal function were in normal limits. Serology for HIV and VDRL were negative. CSF analysis were non remarkable. MRI of the brain (plain and with contrast) were normal (Figure 1). The patient was put on migraine prophylaxis; Amitriptyline 25mg po nocturnal, after 10 weeks follow up patient diplopia completely resolved and 6th cranial nerve palsy resolved.

Discussion

Gubler in 1860 describe the first case; a 19-year-old female with repeated episodes of headache and third nerve palsy, but it was Charcot who use the term "migraine ophthalmoplegique" in 1890 to describe the series of cases with this feature¹⁻³ Ophthalmoplegic migraine was a rare condition, which commonly occurs in children as recurrent migraine headache followed by ophthalmoplegia⁴⁻⁶ In ophthalmoplegic migraine (OM) third cranial nerve is commonly involved with pupillary dilation but in adult cases pupillary involvement is uncommon. Sixth and fourth cranial nerve can be involved rarely, but other cranial nerve involvement has not been reported.^{1,4,5,7} According to The International Classification of Headache Disorders, 3rd edition (ICHD-3), the name ophthalmoplegia migraine was replaced by recurrent painful ophthalmoplegia neuropathy (RPON) and categorized under Painful cranial neuropathies and other facial pains category rather than being under migraine headache.⁶

The term OM was rejected because this syndrome is not migrainous, but rather a recurrent painful neuropathy, which may be due a recurrent demyelinating, because different recent data suggest that headache can develop days to 2 weeks prior to ocular motor paresis and enhancement or nerve thickening of Nerve root exit can

be demonstrated using MRI^{2,8,9} OM was removed from category of migraine at 2004 on ICHD-II.¹⁰ Diagnosis of OM according to ICHD-3, At least two attacks fulfilling,

- a. Unilateral headache accompanied by
- b. ipsilateral paresis of one, two or all three ocular motor nerves
- c. Orbital, parasellar or posterior fossa lesion has been excluded by appropriate investigation
- d. Symptoms Not better accounted for by another ICHD- 3 diagnosis.⁶

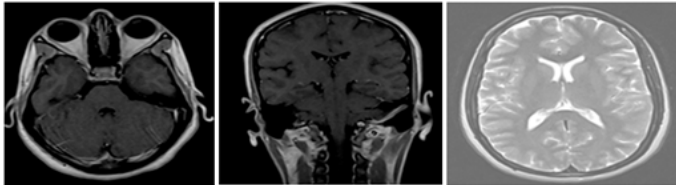


Figure 1 MRI of the patient, post contrast T1 Weight axial and coronal view and T2 axial view showing normal MRI study.

Lal et al.⁴ after review of many literature, suggested that OM, could be subdivided as, Adult variant and Childhood variant, of which both have different characteristics and imaging features.⁴ OM is uncommon disorder with an annual incidence rate of 0.7 per 1,000,000 population.¹¹ Lal et al.¹² reported from tertiary care hospital in India from the cohort of 7,000 patients with migraine seen at the center only 62 adult patients with OM were seen.¹² According to study done by Friedman et al.¹³ Out of 5000 migraine patients only 8 of them have OM.¹³

The pathogenesis is said to be due to either, compression, ischemia or demyelinating lesion, according to review by Lal et al.⁴ ischemic breakdown of the blood-neural barrier, due to ischemia associated with migraine as a result of vasoconstriction of internal carotid artery located in cavernous sinus, which result in vasogenic edema of the nerve at the root entry zone where, especially in children, the barrier is deficient, which in turn correlated with the reversible failure of the barrier to magnetic resonance imaging (MRI) findings and suggested that enlargement and enhancement of the nerve.^{3,4,12} We could not demonstrate any enhancement of the nerve root exit on brain MRI in our patient, This finding probably strengthens the idea that enhancement is common in children not in adult.^{4,8}

Even though there is no case serious from Ethiopia, to our knowledge this is the second case report from Ethiopia. The first being reported by Belachew et al. 2009, reported a case of OM with oculomotor palsy.³ Even though many literatures support the idea that 3rd cranial nerve is commonly involved and 4th and 6th cranial nerves involved rarely, according cohort of Lal et al.⁴ out of 62 OM patient, 35 (56.5%) had Isolated abducens at Presentation, which suggested that 6th cranial nerve palsy is not uncommon as been reported in previous literatures.^{4,14,15} A biological blood test, including FBS, CBC, LFT, RFT, VDRL and ANA to rule out common cause of ischemia, it's also important to analyze patient CSF and an MRI and MRA will help the treating to rule out any structural abnormality and MRI may show reversible enhancement of affected cranial nerve, a phenomenon which is uncommon in adults.^{7,8,9}

Bharucha et al.⁹ Reported the benefit of steroid for those patient present early, by both accelerating recovery from palsy and prevent the permanent palsy sometimes seen in patient who had recurrent palsy.⁹ according to study by Levin et al.¹⁶ Migraine prophylactic therapy with b-blocker or calcium channel blocker medication for patients

with recurrent attacks may be beneficiary considering the pathology could be related to migraine.¹⁶ Lal et al.,⁴ suggested botulinum toxin A or surgical realignment had a good effect for short or long-term management of ophthalmoplegia in this patient.⁴

In Ethiopia even if different study estimated annual incidence of migraine to be 6.2%,^{17,18} there is only one case report on OM till now, but considering the increasing number of population in Ethiopia in which currently population number is >92 million its obvious that more cases of OM could be reported or bigger studies could be done to estimate the annual incidence of OM in Ethiopia.³

Since our patient came late, steroid is avoided and patient was put on migraine prophylaxis; amitriptyline 25mg daily, in which patient have complete resolution after 10 weeks.

We believe, this case may add a few things in our effort to understand this disorder and in understanding of OM among different race and geographical distribution in Africa, especially in sub-Saharan where the incidence of migraine is somewhat lower than the west though the reason is not clear.¹⁹⁻²¹

Consent

Written informed consent was obtained from the patient for publication of this case report and any accompanying images. A copy of the written consent is available for review by the Editor-in-Chief of this journal.

Acknowledgements

Department of Neurology, Addis Abeba University, Ethiopia.

Conflicts of interest

None.

References

1. Daroff RB. Random comments: neurologists and neuro-ophthalmology; the "ocular motor" system; and update on ophthalmoplegic migraine. *Sem Neurol.* 2000;20:145–149.
2. Arasho BD. Ophthalmoplegic migraine in a 15-year-old Ethiopian: Case report and literature review. *J Headache Pain.* 2009;10(1):45–49.
3. Zhou J, Qingqing Huang, Jian Qin. A Case of Ophthalmoplegic Migraine and Literature Review. *J Pharmacovigilance.* 2015;3(2):162.
4. Lal V. Ophthalmoplegic migraine: past, present and future. *Neurol India.* 2010;58(1):15–19.
5. Chen PK, Wang SJ. Ophthalmoplegic migraine: Migraine variant or cranial neuralgia? *Cephalalgia.* 2012;32(7):515–517.
6. Headache Classification Committee of the International Headache Society (IHS). The International Classification of Headache Disorders, 3rd edition (beta version). *Cephalalgia.* 2013;33(9):629–808.
7. Vargas BB. Resident and fellow section. Teaching case: ophthalmoplegicmigraine. *Headache.* 2008;48(9):1396–1398.
8. Dudani A, Chudgar DV, Goudinho S. Ophthalmoplegic migraine. *Journal of the Bombay Ophthalmologists'.* 2001;11(3):95–98.
9. Bharucha DX, Campbell TB, Valencia I, et al. MRI findings in pediatric ophthalmoplegic migraine: a case report and literature review. *Pediatr Neurol.* 2007;37:59–63.
10. Headache Classification Subcommittee of the International Headache Society. The International Classification of Headache Disorders: 2nd edition. *Cephalalgia.* 2004;24(Suppl 1):1–160.

11. Hansen SL, Borelli-Moller L, Strange P, et al. Ophthalmoplegic migraine: Diagnostic criteria, incidence of Hospitalization and possible etiology. *Acta Neurol Scand.* 1990;81(1):54–60.
12. Lal V, Sahota P, Singh P, et al. *Ophthalmoplegia with migraine in adults: Is it ophthalmoplegic migraine?* *Headache.* 2009;49(6):838–850.
13. Friedman AP, Harter DH, Merritt HH. Ophthalmoplegic migraine. *Arch Neurol.* 1962;7:320–327.
14. Lee TG, Choi WS, Chung KC. Ophthalmoplegic migraine with reversible Enhancement of intra-parenchymal abducens nerve on MRI. *Headache.* 2002;42:140–141.
15. Verhagen WI, Prick MJ, van Dijk Azn R. Onset of ophthalmoplegic Migraine with abducens palsy at middle age? *Headache.* 2003;43(7):798–800.
16. Levin M, Ward TN. Ophthalmoplegic migraine. *Curr Pain Headache Rep.* 2004;8(4):306–309.
17. Takele GM, Tekle Haimanot R, Martelletti P. Prevalence and burden of primary headache in Akaki textile mill workers, Ethiopia. *J Headache Pain.* 20089(2):119–128.
18. Tekle Haimanot R, Seraw B, et al. Migraine, chronic tension type headache, and cluster headache in an Ethiopian rural community. *Cephalalgia.* 1995;15(6):482–488.
19. Granado L, Guillen G. Treatment options for ophthalmoplegic migraine. *J Postgrad Med.* 2009;55(3):231–232.
20. Charcot JM. Sur un cas de migraine ophthalmoplegique (paralysie oculomotrice periodique) (32:99–102). *Prog Med (Paris).* 1890;31:83–86.
21. Roy M, Ghosh J, Deb S, et al. Childhood steroid-responsive ophthalmoplegic migraine. *J Pediatr Neurosci.* 2011;6(1):69–71.