

# Promoting neuroplasticity in a developing brain: integrated neurorehabilitation (inra) for children with cerebral palsy - a protocol description and case report

## Abstract

Cerebral palsy (CP) is the commonest cause of physical disability in children, but optimal rehabilitative protocols have yet to be determined, and progress in developing novel interventions has been slow. Neuroplasticity is no longer thought to be fixed in childhood, but instead develops throughout life; however, the best way to exploit the remodeling brain has yet to be determined. Here we present a novel multimodal integrative medicine protocol for the management of children and adolescents with CP termed Integrated Neurorehabilitation (INRA). The basic INRA protocol combines physical therapy, magnetostimulation, and a nutraceutical regimen to provide endogenous and exogenous neurorestorative stimuli to damaged corticospinal pathways on a background of an optimized neuronal microenvironment. We illustrate the protocol with the case of a 13-year-old boy showing marked improvements in gross motor function (GMFM-88 score 82% from 59%), speech (TOM score 3 from 0), and cognition (TOEM score 3 from 1) after four years of therapy. Epileptiform activity on EEG was reduced. We describe the protocol in full and the scientific rationale for its implementation. INRA can be used alongside existing medical and rehabilitative regimens to promote neuroplasticity and synaptogenesis.

**Keywords:** Cerebral palsy, Neurorehabilitation, Neuroplasticity, Nutraceutical, Magnetostimulation

Volume 4 Issue 4 - 2016

Maja Roje Novak  
www.dr-roje.com

**Correspondence:** Dr. Maja Roje Novak, M.D., M.S., Pavla Hatza 27, 1000 Zagreb, Croatia, Tel 091-5697825, Email snagatee@yahoo.com

**Received:** February 17, 2016 | **Published:** March 23, 2016

## Introduction

Cerebral palsy (CP), the commonest cause of physical disability in children,<sup>1</sup> is characterized by permanent disorders of the development of movement and posture.<sup>2</sup> CP results from primary brain injury before birth or during early childhood that results in aberrant neural connections.<sup>3</sup> Children with CP are managed using a variety of passive or active interventions that aim to improve movement and posture, along with secondary interventions to manage frequently encountered disturbances in sensation, perception, cognition, communication, and behavior. These elements of rehabilitation ideally consist of neuroscience evidence-based therapies for neurobehavioral impairments and medical management of primary neurological disorders such as epilepsy and spasticity. The functional deficits seen in CP have a wide-ranging impact on both patients and their caregivers by restricting many aspects of normal living including self-care, education, and recreation.<sup>4</sup> However, and despite the negative impact of physical impairment and secondary symptoms on children, optimal interventions are poorly understood. Progress in developing interventions has been slow, which has led to missed opportunities to reduce morbidity, improve the quality of life of both children and their carers, and to deliver cost-effective care.<sup>5</sup>

The management of CP must, therefore, be multidisciplinary to achieve the best outcomes. In practicality, this means that CP is managed by a combination of medical, neurological, and rehabilitative care. For instance, tone abnormalities might be managed from the rehabilitative perspective with physical therapy, task-specific practice, functional neurostimulation, serial casting, and orthotic devices; from the neurological perspective with oral medications such as dantrolene or botulinum A toxin injections;<sup>6</sup> and from the psychological

perspective through patient and family education and self-directed exercise.<sup>5</sup>

However, there is a growing appreciation that neurological plasticity – the capacity to learn, reorganize, and, in particular, recover from injury - is not fixed in childhood but can be modified throughout life.<sup>7</sup> This raises the possibility that neuroplasticity can be exploited for therapeutic benefit. Activity-dependent plasticity takes place in the motor cortex, so intensive and repetitive task-specific exercises could be used to improve motor recovery,<sup>8</sup> and indeed this has been shown to be the case in adults with stroke.<sup>9</sup> Task-specific therapies such as constraint-induced movement therapy, which forces the use of a weaker arm,<sup>10</sup> or exercise interventions to promote postural control<sup>11</sup> provide moderate evidence to support their use as part of the multidisciplinary management of CP. Furthermore, indirect external interventions such as transcranial magnetic stimulation (TMS), which excite neurotransmission to promote plasticity, have been shown to transiently<sup>12</sup> and persistently<sup>13</sup> improve motor function in adults and children with stroke. TMS has also been used in several studies of children and adolescents with cerebral palsy and is regarded as very safe.<sup>14</sup>

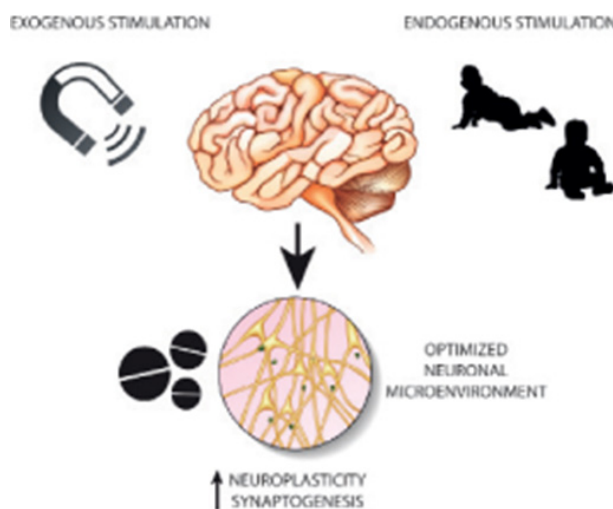
Complementary and alternative medicine (CAM) describes a diverse group of medical and health care systems, practices, and products that are not presently considered to be part of conventional medicine, where integrative medicine refers to a subset of CAMs in which there is a stronger evidence base for their use alongside conventional medicine, such as the TMS and physical therapy described above.<sup>15</sup> Although it is difficult to accurately determine exact figures, it has been reported that anywhere between 27 and 53% of adolescents and children with CP use CAM approaches, respectively,

most commonly hydrotherapy, massage, hyperbaric oxygen, and osteopathy.<sup>16,17</sup> The use of nutraceuticals (a food or product with health benefits, or a dietary supplement) in the management of cerebral palsy is less well documented, but there are a few examples of studies examining the use of vitamin supplementation in children with CP,<sup>18,19</sup> and children with CP are known to suffer from micronutrient deficiencies and anti-oxidant imbalances.<sup>20</sup> This prompted us to develop a new multimodal integrative medicine protocol for the management of children and adolescents with CP termed Integrated Neurorehabilitation (INRA) drawing on three key domains related to promoting positive neuroplasticity and nutrition: physical therapy, TMS, and a nutraceutical regimen.

## Methods

### The basic INRA protocol

The INRA protocol combines three modalities designed to promote neuroplasticity, and therefore recovery, in children with CP. The protocol has been selected to promote endogenous neuroplasticity (physical therapy), provide an exogenous stimulus for neuroplasticity (magnetostimulation), while maintaining and optimizing the neuronal milieu or microenvironment via nutraceutical therapy (Figure 1). The basic protocol comprises:



**Figure 1** A model for Integrated Neurorehabilitation (INRA). Intensive physical therapy (endogenous stimulation) and magnetostimulation (exogenous stimulation) promote positive neuroplasticity and synaptogenesis on the background of an optimized neuronal microenvironment due to the administration of nutraceuticals with anti-oxidant, pro-synaptogenic, and epigenetic effects.

**Physical therapy:** intensive physical therapy for two hours daily consisting of three minutes cycles of five exercises targeting different parts of the body: abdominal, floor rolling, back exercises, sitting, and crawling.

**Brain stimulation:** one hour of magnetostimulation daily using the Viofor JPS apparatus in active mode. The exposure was carried out with the M2P2 settings (intensity 6 degrees) corresponding to 15  $\mu$ T effective induction of a magnetic field.

#### Subcutaneous nutraceutical prescription:

- i. 500 mg vitamin C daily;
- ii. Vitamin B complex (60 mg vitamin B1, 18 mg vitamin B6, 250 mg vitamin B12) daily;

- iii. 1 vial of Cerebrum Compositum (Heel GmBH, Baden-Baden, Germany) daily;
- iv. 5 ml Cerebrolysin (Ever Pharma, Unterach, Austria) twice a week.

All agents were administered subcutaneously.

#### Oral nutraceutical prescription:

- i. 2 caplets of Focus Complex (Puritans Pride);
- ii. One caplet of NeuroPS (Puritans Pride);
- iii. One caplet of vinpocetine (Puritans Pride).

All were administered daily.

[insert Figure 1 about here]

The basic protocol can be supplemented with other complementary approaches that have been examined in CP such as hyperbaric oxygen,<sup>17</sup> functional electrical stimulation,<sup>11</sup> acupuncture,<sup>21</sup> and aromatherapy and massage.<sup>16</sup> However, here we focus on the rationale for the core components of the technique that are specifically designed to promote neuroplasticity.

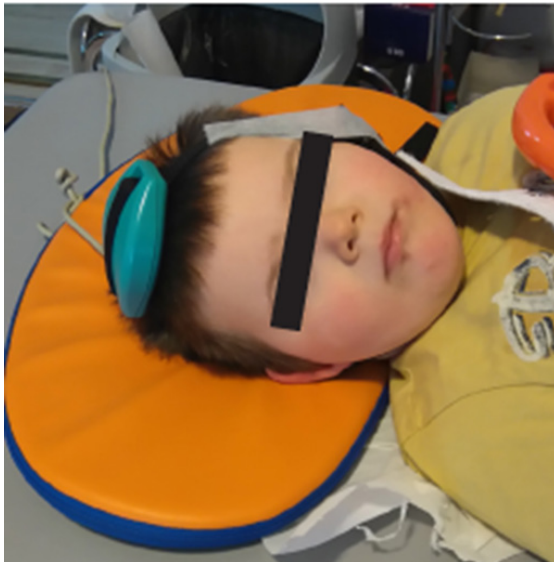### Rationale

**Physical therapy:** Children with CP show deficits in anticipatory and reactive postural adjustments and in the sensory and motor components of postural control.<sup>22-24</sup> These deficits limit skills, including gait,<sup>25</sup> reach,<sup>26</sup> and oral motor activities such as eating, swallowing, and speaking.<sup>27</sup> A number of studies have reported the effects of physical/exercise therapy for children with CP including functional electrical stimulation, gross motor task training, hippotherapy, neurodevelopment therapy, progressive resistance exercise, reactive balance training, treadmill training, and trunk-targeted training (systematically reviewed in<sup>11</sup>). There is moderate evidence supporting the use of a number of these interventions (treadmill training, hippotherapy, trunk-targeted training, reactive balance training, and gross motor task training<sup>11</sup>). Given the: (i) high clinical utility of gross motor task training, which does not require specialist or expensive equipment; (ii) favorable results from two randomized trials adopting a task-oriented, gross motor-focused approach (significantly reduced times for “timed up and go tests” and reach<sup>28,29</sup>); and (iii) the principle that task-specific practice for motor learning and functional organization (i.e., neurodevelopment) is greater when tasks are meaningful,<sup>30</sup> we developed a program of circuits of five exercises similar to real-life tasks and designed to mimic how the muscles are used in everyday activities taking normal biomechanics, core strength (especially abdominal and back exercises), balance (sitting and floor rolling), and limb function (crawling) into account. Given the relative simplicity of these exercises, they are likely to be well received by children and be motivating, which is important since participation is important for improving motor activities.<sup>31</sup>

**Magnetostimulation:** Neuroplasticity can be directly promoted via increases in excitatory neurotransmission and vice versa. In animal models, high-frequency magnetic stimulation induces long-term potentiation in the rat hippocampus via an excitatory mechanism, which is thought to promote synaptogenesis.<sup>32</sup> There have been a number of studies examining transcranial magnetic stimulation (TMS) in children with cerebral palsy, either alone or in combination with other modalities,<sup>14</sup> most of which report improvements in both motor and cognitive-related connectivity and function,<sup>33,34</sup> increased size and activation of motor areas,<sup>35</sup> or a reduction in spasticity.<sup>36</sup> Traditional TMS uses strong magnetic fields with induction values between 0.5

and 2 T and repetition rates near 1 Hz. However, weaker variable magnetic fields (1 nT – 100 mT), called magnetostimulation, although not yet tested in cerebral palsy has shown promise in the treatment of multiple sclerosis,<sup>37</sup> Parkinson's disease,<sup>38</sup> Alzheimer's disease,<sup>39</sup> and depression.<sup>40</sup> These favorable results, the non-invasive methodology, safety of the procedure, and putative positive mechanistic effect on neuroplasticity prompted us to adopt this exogenous stimulation method to complement the endogenous promotion of neuroplasticity from physical therapy (Figure 2).

[insert Figure 2 about here]



**Figure 2** Magnetostimulation device attached to the child's head. The intervention is non-invasive and comfortable.

**Nutraceutical regimen:** As noted above, evidence and clinical trials supporting the use of nutraceuticals in CP are lacking. However, the synaptogenesis that underpins neuroplasticity must be supported an adequate supply of nutrients, and indeed multi-nutrient combinations containing, amongst other compounds, phospholipids and choline have been shown to promote locomotor recovery and reduce the size of lesions in animal models of spinal cord injury.<sup>41</sup> Furthermore, children with severe CP have significant differences in micronutrient levels (lower zinc, glutathione reductase, and superoxide dismutase (SOD) and higher red cell folate) than in healthy controls<sup>20</sup> and redox imbalance (such as that caused by a reduction in critical antioxidant enzymes such as SOD) in the neurogenic microenvironment might reduce neurogenesis and hence plasticity.<sup>42</sup> We therefore sought to optimize the neurogenic microenvironment to promote neuroplasticity with vitamin C (a well-known antioxidant with neurophysiological effects including neuronal development, maturation, and survival<sup>43</sup>); vitamin B complex (an epigenomic regulator that influences neuronal survival and differentiation<sup>44</sup>); Cerebrum compositum (a homeopathic preparation prescribed for mental fatigue); Cerebrolysin (a mixture of neuropeptides and free amino acids used in the treatment of stroke, neurodegenerative disease, and traumatic brain injury to promote neural regeneration<sup>45</sup>); Focus Complex (a proprietary blend of vitamins and minerals including the anti-oxidants vitamins C and E, selenium and zinc); NeuroPS (a phosphatidylserine supplement; phosphatidylserine is an integral component of the cell membrane and might have a protective effect against neurodegeneration<sup>46</sup>); and vinpocetine (a semi-synthetic alkaloid derived from the lesser periwinkle plant and thought to promote neurological recovery after ischemia<sup>47</sup> or protect against neurodegeneration<sup>48</sup>).

## Case report

A 13-year-old boy with cerebral palsy was referred to clinic with severe motor, intellectual, and speech deficits. The child was born 4 weeks prematurely from a twin pregnancy; his sibling was born (and remains) healthy. On neurological examination on presentation, his GCS was 15 and he had normal pupillary reflexes and cranial nerves. His head was normal without any malformations, there was no scoliosis, and his upper limbs, although not malformed and functional with satisfactory coordination and no tremor, exhibited signs of slow movement, delayed fine motor function, and hypertonia (2/5). He showed diffuse weakness of the pelvic muscles with a restricted range of movements. His lower limbs were not malformed, but again, there was hypertonia (2/5) and brisk reflexes and bilateral positive Babinski sign. Sensory function was normal.

His Gross Motor Function Method (GMFM-88) score on referral was 59%.<sup>49</sup> He was unable to crawl or sit independently, although he could maintain an upright posture and walk with assistance. He wore diapers since sphincter control was not established. He was scored as "0" for speech impairment and "1" for cognitive impairment, according to Therapy Outcome Measures for health professionals scoring.<sup>50</sup> His IQ was 24 at presentation. His mother provided consent for treatment and the publication of these findings.

An EEG has taken prior to therapy showed basal cerebral activity in the slow alpha range (12-18 Hz) with diffuse theta activity across the frontal regions. There was no pronounced blocking, asymmetry, or spontaneous paroxysms. After photic stimulation and hyperventilation, small clusters of high-voltage, short spikes were observed above the frontotemporal regions bilaterally, suggesting paroxysmal/epileptiform tendencies in this region. Magnetic resonance imaging (MRI) showed cortical and corpus callosum atrophy with mild optic nerve and chiasma atrophy but no other significant abnormalities.

He was started on an IRNA protocol consisting of daily three-hour sessions of:

- i. Two hours of intensive physical therapy according to the main protocol with exercises organized into modules of three minutes each of five essential exercises (abdominal, floor rolling, back exercises, sitting, crawling); and
- ii. One hour of medical therapy consisting of magnetic stimulation and nutraceutical injections. He was prescribed Focus Complex, vinpocetine, and NeuroPS orally to be taken at home.

He attended therapy daily on weekdays for four years. After this time, his outcome measures had improved: his GMFM-88 score was 82% (from 59%), his speech impairment was 3 (from 0), and his cognitive impairment was 3 (from 1). His IQ had improved to 37. Subjectively, his performance had improved from only being able to say individual words like "mummy" and "daddy" to having context-dependent conversations with a limited vocabulary. For example, in response to being asked "Are you hungry", he could now reply "Mummy, I am, but would rather have a steak instead of this muffin". Post-therapy he was able to floor roll, flex his hips and knees to pull himself into the sitting position, and crawl. Although he remained unable to stand independently, he could stand for up to one minute and walk for short distances assisted. He remained hypertonic but to a lesser degree (1/5).

His post-therapy EEG was essentially normal with basal cerebral activity in the alpha range (14-20 Hz) and only rare slow waves. No EEG abnormalities were noted with photic stimulation and hyperventilation. His MRI was unchanged.

## Discussion

Here we present the case of a 13-year-old boy with cerebral palsy (CP) causing severe motor, intellectual, and speech deficits to illustrate the efficacy of our novel Integrated Neurorehabilitation protocol (INRA). INRA is a multimodal integrative medicine approach that combines endogenous (physical therapy) and exogenous (magnetostimulation) practices on a background of a neurorehabilitative nutraceutical regimen to promote positive neuroplasticity. After four years of INRA therapy, the child showed excellent improvements in motor function, with a 23-percentage point increase in GMFM-88 score. Although subject to the patient, care giver, and therapist interpretation, a gain of 5 to 7 GMFM percentage points is regarded as a “medium” positive change according to validation data;<sup>51</sup> a 23-percentage point increase may, therefore, reasonably be regarded as excellent. Furthermore, objective measures of speech and cognitive impairment improved markedly from very severe or severe impairment to moderate impairment after therapy. There was also a slight increase in his IQ and a decrease in epileptiform activity on EEG.

It is well accepted that the clinical management of CP requires a multidisciplinary approach<sup>5</sup> with rehabilitative, medical, and team-based approaches that address the main deficits faced by children with CP: motor, tone, cognitive, seizure-related, psychosocial, and oromotor. Since most (if not all) of these deficits may be addressed by capitalizing on the growing realization that the brain is plastic throughout life, here we adopt practices that promote positive neuroplasticity and synaptogenesis to produce a positive impact on the rehabilitation of children with CP. INRA draws experience from both mainstream (physical therapy) and complementary (magnetostimulation and nutraceutical) approaches to promote positive neuroplasticity in a safe protocol that sits alongside standard CP treatments such as anti-epileptic medicines, anti-spasmodics, orthotics, and education and counseling. Indeed, the intensive application of the protocol over a sustained period of time, which it likely to be necessary to produce durable changes, allows the practitioner and their teams to monitor progress in real-time and respond to complications as they arise.

The INRA protocol adopts a triple approach to promoting neuroplasticity: endogenous stimulation of motor pathways (via physical/exercise therapy), exogenous stimulation of motor pathways (via magnetostimulation), and support of the neuronal microenvironment with nutraceuticals. Therapy is intensive and prolonged, consistent with other neurorestorative experiences in CP<sup>5</sup> and diseases such as adult stroke and traumatic brain injury<sup>52</sup> suggesting that intensive models of therapy achieve modest to strong effects compared to usual care.<sup>53</sup> However, there is a knowledge gap on the time course and underlying pathobiology of corticospinal development that is reflected in uncertainty over the optimal timing, dose, and duration of therapy in CP and the best application of stage-specific rehabilitation strategies. Nevertheless, given that INRA in the older child appears to be effective (as shown here), there is an expectation that earlier application in younger children may yield even more favorable results. This hypothesis requires testing in a formal clinical trial.

Here we have presented the basic INRA protocol. However, we expect the protocol to evolve as other complementary and integrative therapies gain an evidence base. For example, acupuncture has been tested in children with CP in a number of randomized clinical trials regarded of “moderate” quality both as an adjunct to conventional therapy and rehabilitation therapy and alone,<sup>21</sup> and functional electrical stimulation (FES) has shown some efficacy in children with CP, although data are weak and sometimes conflicting.<sup>11</sup> Here we have

focused on the basic protocol since it is easily applied in practice with only minimal investment required in terms of equipment or training of new expertise. Although initially designed for the CP setting, we would envisage that the principles of neurorestoration exploited by the protocol would be similarly effective in other acquired brain injuries.

## Conclusion

Here we present a novel intensive, integrated neurorehabilitative protocol, the INRA, which adopts a multimodal triple neurorestorative approach to promote neuroplasticity and synaptogenesis. We illustrate the protocol's efficacy with a case report demonstrating excellent motor, cognitive, and speech progression in a child with severe CP. Further testing of the protocol is required in a prospective clinical trial.

## Acknowledgments

None.

## Conflicts of interest

None.

## References

1. Oskoui M, Coutinho F, Dykeman J, et al. An update on the prevalence of cerebral palsy: a systematic review and meta-analysis. *Dev Med Child Neurol*. 2013;55(6):509–519.
2. Rosenbaum P, Paneth N, Leviton A, et al. A report: the definition and classification of cerebral palsy April 2006. *Dev Med Child Neurol Suppl*. 2007;109:8–14.
3. Bax MC, Flodmark O, Tydeman C. Definition and classification of cerebral palsy. From syndrome toward disease. *Dev Med Child Neurol Suppl*. 2007;109:39–41.
4. Imms C. Children with cerebral palsy participate: a review of the literature. *Disabil Rehabil*. 2008;30(24):1867–1884.
5. Aisen ML, Kerkovich D, Mast J, et al. Cerebral palsy: clinical care and neurological rehabilitation. *Lancet Neurol*. 2011;10(9):844–852.
6. Whelan MA, Delgado MR. Practice parameter: pharmacologic treatment of spasticity in children and adolescents with cerebral palsy (an evidence-based review): report of the quality standards subcommittee of the american academy of neurology and the practice committee of the child neurology society. *Neurology*. 2010;75(7):669.
7. Holt RL, Mikati MA. Care for child development: basic science rationale and effects of interventions. *Pediatr Neurol*. 2011;44(4):239–253.
8. Dobkin BH. Neurobiology of rehabilitation. *Ann N Y Acad Sci*. 2004;1038:148–170.
9. Lo AC, Guarino PD, Richards LG, et al. Robot-assisted therapy for long-term upper-limb impairment after stroke. *N Engl J Med*. 2010;362(19):1772–1783.
10. Boyd R, Sakzewski L, Ziviani J, et al. INCITE: A randomised trial comparing constraint induced movement therapy and bimanual training in children with congenital hemiplegia. *BMC Neurol*. 2010;10:4.
11. Dewar R, Love S, Johnston LM. Exercise interventions improve postural control in children with cerebral palsy: a systematic review. *Dev Med Child Neurol*. 2015;57(6):504–520.
12. Talelli P, Greenwood RJ, Rothwell JC. Exploring Theta Burst Stimulation as an intervention to improve motor recovery in chronic stroke. *Clin Neurophysiol*. 2007;118(2):333–342.
13. Kirton A, Chen R, Friefeld S, et al. Contralesional repetitive transcranial magnetic stimulation for chronic hemiparesis in subcortical paediatric stroke: a randomised trial. *Lancet Neurol*. 2008;7(6):507–513.

14. Krishnan C, Santos L, Peterson MD, et al. Safety of noninvasive brain stimulation in children and adolescents. *Brain Stimul.* 2015;8(1):76–87.
15. Oppenheim WL. Complementary and alternative methods in cerebral palsy. *Dev Med Child Neurol.* 2009;51(Suppl 4):122–129.
16. Hurvitz EA, Leonard C, Ayyangar R, et al. Complementary and alternative medicine use in families of children with cerebral palsy. *Dev Med Child Neurol.* 2003;45(6):364–370.
17. Majnemer A, Shikako-Thomas K, Shevell MI, et al. Pursuit of complementary and alternative medicine treatments in adolescents with cerebral palsy. *J Child Neurol.* 2013;28(11):1443–1447.
18. Le Roy C, Meier M, Witting S, et al. Effect of supplementation with a single dose of vitamin D in children with cerebral palsy. Preliminary randomised controlled study. *Rev Chil Pediatr.* 2015;86(6):393–398.
19. Zhu X, Jiao R, Tu M, et al. The effect of vitamin D auxiliary rehabilitation therapy in children with cerebral palsy and language dysfunction. *Minerva Pediatr* [Epub ahead of print]. 2015.
20. Schoendorfer NC, Vitetta L, Sharp N, et al. Micronutrient, antioxidant, and oxidative stress status in children with severe cerebral palsy. *JPEN J Parenter Enteral Nutr.* 2013;37(1):97–101.
21. Yang C, Hao Z, Zhang LL, et al. Efficacy and safety of acupuncture in children: an overview of systematic reviews. *Pediatr Res.* 2015;78(2):112–119.
22. Bigongiari A, de Andrade e Souza F, et al. Anticipatory and compensatory postural adjustments in sitting in children with cerebral palsy. *Hum Mov Sci.* 2011;30(3):648–657.
23. Lowes LP, Westcott SL, Palisano RJ, et al. Muscle force and range of motion as predictors of standing balance in children with cerebral palsy. *Phys Occup Ther Pediatr.* 2004;24(1–2):57–77.
24. Nashner LM, Shumway-Cook A, Marin O. Stance posture control in select groups of children with cerebral palsy: deficits in sensory organization and muscular coordination. *Exp Brain Res.* 1983;49(3):393–409.
25. Woollacott MH, Shumway-Cook A. Postural dysfunction during standing and walking in children with cerebral palsy: what are the underlying problems and what new therapies might improve balance? *Neural Plast.* 2005;12(2–3):211–219;discussion.263–272.
26. van der Heide JC, Fock JM, Otten B, et al. Kinematic characteristics of postural control during reaching in preterm children with cerebral palsy. *Pediatr Res.* 2005;58(3):586–593.
27. Larnert G, Ekberg O. Positioning improves the oral and pharyngeal swallowing function in children with cerebral palsy. *Acta Paediatr.* 1995;84(6):689–692.
28. Katz-Leurer M, Rotem H, Keren O, et al. The effects of a ‘home-based’ task-oriented exercise programme on motor and balance performance in children with spastic cerebral palsy and severe traumatic brain injury. *Clin Rehabil.* 2009;23(8):714–724.
29. Salem Y, Godwin EM. Effects of task-oriented training on mobility function in children with cerebral palsy. *NeuroRehabilitation.* 2009;24(4):307–313.
30. Bayona NA, Bitensky J, Salter K, et al. The role of task-specific training in rehabilitation therapies. *Top Stroke Rehabil.* 2005;12(3):58–65.
31. Bartlett DJ, Palisano RJ. Physical therapists’ perceptions of factors influencing the acquisition of motor abilities of children with cerebral palsy: implications for clinical reasoning. *Phys Ther.* 2002;82(3):237–248.
32. Tokay T, Holl N, Kirschstein T, et al. High-frequency magnetic stimulation induces long-term potentiation in rat hippocampal slices. *Neurosci Lett.* 2009;461(2):150–154.
33. Guo Z, Xing G, He B, et al. Dynamic modulation of rTMS on functional connectivity and functional network connectivity to children with cerebral palsy: a case report. *Neuroreport.* 2016;27(4):284–288.
34. Flamand VH, Schneider C. Noninvasive and painless magnetic stimulation of nerves improved brain motor function and mobility in a cerebral palsy case. *Arch Phys Med Rehabil.* 2014;95(10):1984–1990.
35. Bleyenheuft Y, Dricot L, Gilis N, et al. Capturing neuroplastic changes after bimanual intensive rehabilitation in children with unilateral spastic cerebral palsy: A combined DTI, TMS and fMRI pilot study. *Res Dev Disabil.* 2015;43–44:136–149.
36. Valle AC, Dionisio K, Pitskel NB, et al. Low and high frequency repetitive transcranial magnetic stimulation for the treatment of spasticity. *Dev Med Child Neurol.* 2007;49(7):534–538.
37. Sandyk R. Long term beneficial effects of weak electromagnetic fields in multiple sclerosis. *Int J Neurosci.* 1995;83(1–2):45–57.
38. Sandyk R. The effects of external picotesla range magnetic fields on the EEG in Parkinson’s disease: a follow up study. *Int J Neurosci.* 1994;76(3–4):227–229.
39. Sandyk R. Alzheimer’s disease: improvement of visual memory and visuoconstructive performance by treatment with picotesla range magnetic fields. *Int J Neurosci.* 1994;76(3–4):185–225.
40. Sobis J, Jarzab M, Hese RT, et al. Therapeutic efficacy assessment of weak variable magnetic fields with low value of induction in patients with drug-resistant depression. *J Affect Disord.* 2010;123(1–3):321–326.
41. Pallier PN, Poddighe L, Zbarsky V, et al. A nutrient combination designed to enhance synapse formation and function improves outcome in experimental spinal cord injury. *Neurobiol Dis.* 2015;82:504–515.
42. Huang TT, Zou Y, Corniola R. Oxidative stress and adult neurogenesis—effects of radiation and superoxide dismutase deficiency. *Semin Cell Dev Biol.* 2012;23(7):738–744.
43. Figueroa-Mendez R, Rivas-Arancibia S. Vitamin C in Health and Disease: Its Role in the Metabolism of Cells and Redox State in the Brain. *Front Physiol.* 2015;6:397.
44. Gueant JL, Caillerez-Fofou M, Battaglia-Hsu S, et al. Molecular and cellular effects of vitamin B12 in brain, myocardium and liver through its role as co-factor of methionine synthase. *Biochimie.* 2013;95(5):1033–1040.
45. Ziganshina LE, Abakumova T. Cerebrolysin for acute ischaemic stroke. *Cochrane Database Syst Rev.* 2015;(4):CD007026.
46. Wang S, Cu Y, Wang C, et al. Protective Effects of Dietary Supplementation with a Combination of Nutrients in a Transgenic Mouse Model of Alzheimer’s Disease. *PLoS One.* 2015;10(11):e0143135.
47. Jincai W, Tingfang D, Yongheng Z, et al. Effects of vinpocetine and ozagrel on behavioral recovery of rats after global brain ischemia. *J Clin Neurosci.* 2014;21(4):661–663.
48. Gupta S, Singh P, Sharma BM, et al. Neuroprotective Effects of Agomelatine and Vinpocetine Against Chronic Cerebral Hypoperfusion Induced Vascular Dementia. *Curr Neurovasc Res.* 2015;12(3):240–252.
49. Russell DJ, Rosenbaum PL, Cadman DT, et al. The gross motor function measure: a means to evaluate the effects of physical therapy. *Dev Med Child Neurol.* 1989;31(3):341–352.
50. Enderby P. Outcome measures in speech therapy: impairment, disability, handicap and distress. *Health Trends.* 1992;24(2):61–64.
51. Boyce W, Gowland C, Rosenbaum P, et al. Gross motor performance measure for children with cerebral palsy: study design and preliminary findings. *Can J Public Health.* 1992;83(Suppl 2):S34–S40.
52. Corbett D, Nguemini C, Gomez-Smith M. How can you mend a broken brain? Neurorestorative approaches to stroke recovery. *Cerebrovasc Dis.* 2014;38(2014):233–239.
53. Sakzewski L, Gordon A, Eliasson AC. The state of the evidence for intensive upper limb therapy approaches for children with unilateral cerebral palsy. *J Child Neurol.* 2014;29(8):1077–1090.