

Surgical Outcome of Ulnar Nerve Lesions: Not Always Disappointing

Abstract

Background: This study was embraced to examine surgical outcomes for ulnar nerve repairs, so as to help for the optimal management of these lesions.

Methods: We identified 116 patients with ulnar nerve injury who were referred to our brachial plexus and peripheral nerve Injury center and underwent surgery. The demographic data about age, gender, level of injury (arm, elbow or wrist level), type of injury (penetrating or blunt), mechanisms of injury, time interval between onset of injury and surgery and functional outcomes were recorded.

The functional outcomes were scored, taking into account Louisiana State University Health Sciences Center criteria, prior and then afterward the surgery. Type of repair (neurolysis, direct repair, or repair using graft), and length of graft (if any) were gathered.

Results: The most widely recognized mechanism of injury was laceration in all levels. In 95 cases (81%) good functional outcome (Grade 3 or better) was achieved. The best prognosis achieved in the neurolysis (86%) and direct suture (84%), respectively. Good functional outcome was achieved in 86% of patients with nerves in continuity, and 80 % of lesions not in continuity. Overall good functional outcome was achieved in 81% (95 cases) of procedures.

Conclusion: Ulnar nerves injuries are inclined to recuperate if undergo proper surgical intervention, and surgical results were for the most part better for lesions in continuity. In lesions not in continuity end-to-end direct suture showed a better prognosis than nerve graft repairs. Knowing the internal topography of ulnar nerve helps to suture more precisely which in turn may be the cause for achieving the best outcome at each level.

Keywords: Ulnar Nerve; Repair; Injury; Outcome

Research Article

Volume 3 Issue 6- 2015

Mohammadreza Emamhadi¹, Babak Alijani² and Shervin Ghadarjani³

¹Associate Professor of neurosurgery, Guilan University of Medical Sciences, Iran

²Assistant professor of neurosurgery, Guilan University of medical sciences, Iran

³Neurosurgery Resident, Guilan university of medical sciences, Iran

***Corresponding author:** Babak Alijani, Assistant professor of neurosurgery, Guilan University of medical sciences, Rasht, Iran, Email: drbabakalij@gmail.com

Received: December 11, 2015 | **Published:** December 28, 2015

Introduction

The hand is the most often harmed some portion of human body and is the prevalent part treated in hospital emergency departments. In 30-40% of injury occasions, the upper extremity is included [1]. Ulnar nerve injuries can bring about paresthesia, dysesthesia, and muscle weakness in the injured hand. Ulnar nerve injury was the most frequent significant upper extremity peripheral nerve injury resulting in hospital admission, compared with median, radial, and brachial plexus injuries [2].

The ulnar nerve is a mix of motor and sensory nerves, making nerve repair more troublesome and functional recovery less unsurprising than pure sensory nerves. Ulnar nerve injury speaks to a stand-out amongst the most difficult issues in micro-neurosurgery. The clinical advancements have enhanced the accuracy of the operation, yet the outcomes in terms of motor and sensory function are still frustrating [3].

Nerve injuries caused by transection, contusion, stretch, traction, and avulsion are for the most part occurred when medium-to high-energy force is applied directly or indirectly to nerves, though, injuries such as compressive neuropathy have a tendency to happen when nerves are subjected to chronic

or repetitive low-energy force. Nerve injuries from injection and from radiation and thermal energy include a somewhat heterogeneous blend of different injuring factors and can be gathered together as a complex group of nerve injuries [4].

There is expanding proof that various variables are connected with the motor and sensory recovery after peripheral nerve injuries. For instance, repair of nerve compression injuries has preferred results over repair of nerve rupture injuries [5,6].

Various reports have endeavored to display different variables that can influence the outcomes. Gender, age, level of education, number of harmed arteries and structures, damaged nerve, location of the injury, type of the nerve injury, post traumatic stress in 1 to 3 months after repair of the peripheral nerve injury and mechanism of injury can be the predictors of functional recuperation [1].

For better results, ulnar nerve injuries require an early repair, compared with other peripheral nerve injuries [2,7]. Repair of this nerve regularly brings about inadequate recovery with functional results that are much less than those achieved after radial nerve and median nerve repair [2,8,9].

In this study the functional results of nerve repair in patients with ulnar nerve injury was surveyed and contributing elements on the outcome were assessed.

Between 2005 and 2010, 116 patients with ulnar nerve injury, underwent surgical exploration in our center, based on physical examination and electro-diagnostic findings indicating ulnar nerve lesions. The demographic data of this population were gathered. The data bank also included the time interval between onset of the injury to surgery, mechanisms of injury and level of injury. The functional outcome before and after the surgery were scored based on Louisiana State University Health Sciences Center Muscle Grading System (Table 1). Preoperative and postoperative EMG studies were performed in all patients.

The type of surgical interventions were neurolysis, end-to-end direct suture, or graft repair. External neurolysis was used for all cases, but internal neurolysis was done for lesions in continuity, when the injury was more severe on one portion of the nerve than the other or if nerve action potential (NAP) was transmitted across the lesion. In a lesion in continuity when no NAP was recorded, resection and repair of the injured nerve was mostly indicated.

In cases with sharp transection injuries, end-to-end epineurial interrupted suture with 7-0 and 8-0 prolene was used. And, finally, in cases with transection and nerve contusion that the distance between two ends of the injury site after nerve debridement was so far to allow end-to-end suture, nerve grafts were used for repair. Good outcome was consider muscle force Grade M3or better and bad outcome was determined muscle force grade M0 to M2.

Surgical anatomy: internal topography

The topography of the intraneural fascicular groups must be comprehended to have a successful recovery especially for lacerations of the major nerves at the wrist and distal half of the forearm [10]. It was believed that an exact anatomical realignment of fascicles in the repair of lacerated peripheral nerves is impossible, but knowledge of the internal topography of the nerve is important and supportive for the best treatment of transection and other types of nerve injuries.

Sunderland pointed out that the cross-sectional arrangement of nerve components changes from along its length [11]. By using electrical stimulation, it is possible to distinguish between sensory and motor fascicles in the distal nerve end.

The ulnar nerve is made out of different size of funiculi at each level, which has a large number of small funiculi at the wrist [12]. Above the epicondyle the nerve is oval in shape and presents superficial, or medial, and deep, or lateral surfaces with anterior and posterior margins. In the epicondylar groove the surfaces of nerve are posterior, superficial, and anterior, deep.

At the elbow, the motor fascicles to the flexor carpi ulnaris (FCU) and the intrinsics of the hand are centrally located, whereas the sensory fibers are superficially located [13]. The proximal motor branches to the FCU, the single bundle of the distal branch to the FCU, enter the lateral margin of the nerve. There are two branches to the flexor digitorum profundus and each is composed of a single funiculus, which joins and proceeds

along postero-lateral aspect of ulnar nerve [12].

At the level of the mid-forearm, 9cm proximal to the radial styloid, there are three distinct fascicular groups, two sensory groups and motor fascicles [10] which lie dorsomedial to the sensory fascicles [11]. At the wrist, ulnar nerve has a maximum of 25 fascicles and is divided into a volar sensory component and a dorsal motor component. The nerve is medial to the ulnar artery underneath the FCU muscle [14].

Results and Discussion

There were totally 116 patients in this study (74 males and 42 females), in whom lesions were classified based of the site of injury into the Arm, Forearm, and Wrist levels. Lesions in each level based on the cause of the injury is shown in Table 2.

Ages of the Patients ranged from 5 to 70 years. The average follow-up period was 22 months. Time interval to surgery was between 3 days and 6 months. Figures 1 to 3 shows surgical exposure of three of our patients.

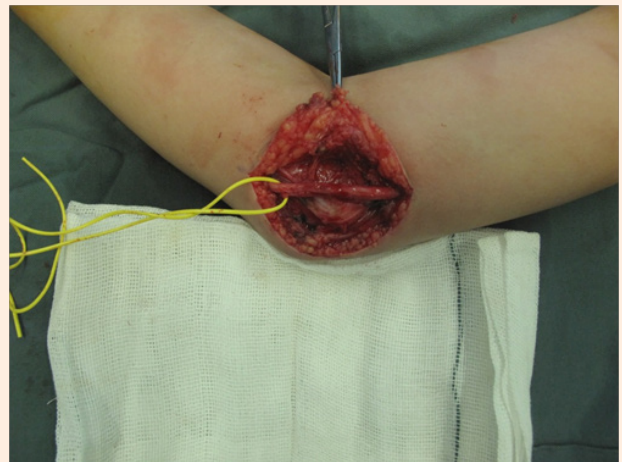


Figure 1: Tardive ulnar palsy in a 7 years old boy after being in a long time coma.

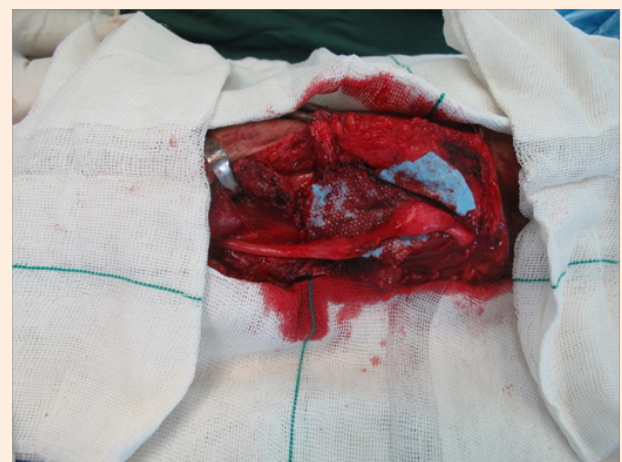

Figure 2: Ulnar Nerve Injury with Neuroma Formation.

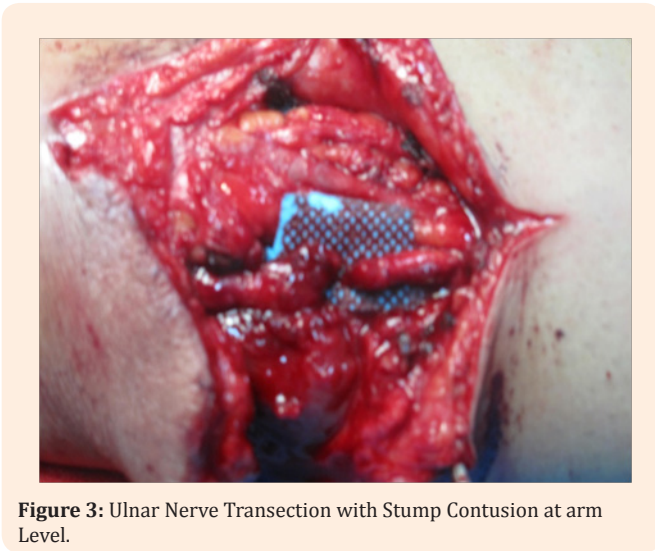

Figure 3: Ulnar Nerve Transection with Stump Contusion at arm Level.

Nerve Injury at the Arm Level

Seven cases (77.7%) of all 9 patients injured with laceration whom underwent direct suture repair had a good outcome (Grade 3 or better). The only one case injured with gunshot and repaired with a nerve graft did not achieve good outcomes. Patients with Fracture/dislocation in arm level, one had continuity with a NAP positive lesion that underwent neurolysis, and regained Grade 4 function according to LSUHSC criteria. Another case with fracture whom is needed to repair with a

nerve graft did not achieved the good outcomes. Among 12 cases of ulnar nerve injury at arm level, 8 cases (66.6%) had a good outcome.

Nerve Injury at the Forearm Level

Among all 64 patients in this group, 49 cases (76.56%) did not have nerve in continuity (complete transection) and in 15 cases (23.43%) it had continuity with recording NAP across lesions.

Among 44 patients injured with laceration, 33 cases (75%) underwent direct end-to-end suture repair, from which 28 cases (84.8%) had good outcomes and 5 of them (15.15%) had worse outcomes. Eleven cases (25%) underwent repair with nerve graft, where 9 cases (81.81%) had good outcomes.

Among 12 cases injured with fracture and dislocation 7 cases (58.33%) underwent neurolysis and 5 cases (41.66%) underwent repair with nerve graft, where 9 cases (75%) regained grade 3 and more functional outcomes.

All 7 cases injured with stretching and contusion underwent neurolysis and 5 cases (71.42%) had good function after surgery.

The only case with electrical injury at the forearm, involving the median and ulnar nerves, underwent surgery (neurolysis) after 3 months and achieved good functional outcome.

All of the ulnar nerve that repaired with direct end-to-end suture underwent nerve transposition to reduce tension on repaired nerve.

Table 1: The Louisiana State University Health Sciences Center Criteria for Grading Ulnar Nerve injury.

| Grade | Description |
|---------------|--|
| 0 (absent) | No muscle contraction; absent sensation |
| 1 (poor) | Proximal muscles such as FCUM & FDPM-V contract, not against gravity; sensory grade is 1 or 0 |
| 2 (fair) | Proximal muscles (FCUM & FDPM-V) contract against gravity & distal intrinsic muscles do not contract; sensory grade, if applicable, is usually ≤2 |
| 3 (moderate) | Proximal muscles (FCUM & FDPM-V) contract against gravity with some resistance; some distal muscles, usually hypothenar muscles & occasionally lumbrical muscles, contract against little resistance; sensory grade is usually 3 |
| 4 (good) | All proximal & some distal intrinsic muscles of the hand, such as the interosseous & lumbrical muscles to the little & ring finger, contract against pressure with some resistance; sensory grade is ≥3 |
| 5 (excellent) | All muscles, including intrinsic muscles of the hand, contract against moderate resistance; sensory grade is ≥4 |

*FDPM-V=Flexor digitorum profundus to the little finger; *FCUM=Flexor carpi ulnaris muscle.

Table 2: Lesions in each level based on the case of the injury.

| | Laceration | Fracture/Dislocation | Stretch/Contusion | Iatrogenic | Gunshot | Electrical | Total |
|-----------------|-------------|----------------------|-------------------|------------|-----------|------------|-------------|
| Arm | 9 | 2 | 0 | 0 | 1 | 0 | 12 (10.34%) |
| Forearm / Elbow | 44 | 12 | 7 | 0 | 0 | 1 | 64 (55.17%) |
| Wrist | 33 | 1 | 0 | 6 | 0 | 0 | 40 (34.48%) |
| Total | 86 (74.13%) | 15 (12.93%) | 7 (6.03%) | 6 (5.17%) | 1 (0.86%) | 1 (0.86%) | 116 |

Injury at the Wrist Level

None of the cases with laceration at this level did not have continuity and were repaired with end-to-end direct suture. Twenty-eight of them (84.84%) after surgery had good outcomes.

In the 6 iatrogenic cases in which the nerve was compressed superficially against bony prominence because the casts applied on them were too tight. They underwent exploratory surgery. The time interval between injury and surgery was less than 2 months and during surgery epineurial fibrosis was seen and neurolysis were done for all patients, and all of them (100%) had good outcomes.

The single case with injury after dislocation underwent neurolysis and was assigned Grade 5 level of function.

In our study the most common mechanisms of injury were laceration, fracture and dislocation, contusion, and stretch, in descending order. Woo et al. [2] studied the mechanisms of injury in order of frequency including laceration, stretch and contusion. Kim et al. [15] found the most common mechanism was laceration. In the muravic study, the 5 leading Mechanisms in upper extremity nerve injuries included laceration, stretch/contusion, GSW, compression/entrapment, and fracture in varying numbers and levels, depending on the nerve [9].

We had 86 cases with laceration for mechanism of injury (74.13%). None of them had nerves in continuity and all of them underwent repair with suture. Seventy-two cases (83.72%) after surgery had good neurological function and 14 cases (16.27%) had not good outcome. Kim et al. [15] and colleagues reported lesions which were not in continuity and were caused by a sharp laceration could be repaired with an end-to-end suture within 72 hours of injury (primary repair) and usually regained Grade 3 or better outcomes. This was seen in 16 (73%) of 22 patients. In patients for whom a delay occurred in their repair, resulted in Grade 3 or better functional outcomes for 11 (69%) of 16 patients was achieved. Only five cases (56%) in 9 patients who needed graft repair after laceration, achieved Grade 3 function.

another cause of ulnar nerve injury was fracture and dislocation that was seen in 15 cases (12.93%), and 6 cases (40%) suffered from transection and 9 cases (60%) had nerve in continuity in these cases, 11 patients (73.33%) achieved good outcomes after surgery and 4 cases (26.66%) did not have good outcomes.

Seven of our patients (6.03%) had ulnar nerve injury due to stretch and contusion and all of them underwent neurolysis. All of these injuries occurred at forearm and elbow level and 5 cases (71.42%) had good outcomes after surgery. Kim et al. [15] showed that stretch and contusion were most often seen at the elbow and forearm level of the ulnar nerve. In his study, 86% of patients with severe preoperative deficits without significant improvement achieved Grade 3 or better function based on clinical and electrophysiological criteria after neurolysis [15].

We had one case injured after gunshot trauma that underwent repair with nerve graft and did not have good outcome. In Secer et al. [16] series who suffered gunshot and shrapnel wound good

outcome achieved 49.68% in low level, 29.6% in intermediate level and, 15.06% in high level injuries.

In six (5.17%) patients, compression on ulnar nerve after casting was the mechanism of injury and all of them underwent neurolysis and all of them had good outcomes. We couldn't find any report of ulnar nerve injury after casting. One patient suffered from electrical injury and underwent neurolysis and had good outcome.

In our study 75 cases (80.64%) from 93 patient with ulnar nerve transection had good outcomes after surgery, and 20 cases (86.95%) from 23 patients with nerve in continuity had good outcomes after surgery. Sixty-eight cases (90.66%) from 75 patients that underwent direct suture had good outcomes, and 7 cases (38.88%) among 18 cases that underwent nerve graft repair had good outcomes after operation, and 20 cases (86.95%) of 23 cases that underwent neurolysis had good outcome after surgery.

In muravic study, the lesions not in continuity at all levels in the ulnar nerve with primary suture repairs, satisfactory outcomes were found in 16 of 22 ulnar nerves (73%). Ulnar nerve secondary suture repairs resulted in good outcomes in 11 of 16 cases (69%). Neurolysis for lesions in-continuity with positive NAPs achieved good results in 80 of 85 patients (94%) [9].

Kim and colleagues, in a study of 654 ulnar nerve lesions, have shown that functional recovery of Grade M3 or better is greatest when the injury requires only neurolysis (92% of patients), followed by primary repair (72% of patients), and then those injuries requiring nerve grafting (67% of patients) [15]. A recent study showed 59% of workers were able to return to employment at an average of 30 weeks following isolated ulnar nerve injuries. Higher educational status, compliance with therapy, distal injuries, and better postoperative grip and pinch strengths tended to be positive predictors for earlier return to work [17].

In our study, the patients who underwent surgery, 66.66% at the arm level, 81.25% at the elbow and forearm and 87.5% at the wrist level had good functional outcomes. Kilinc et al. [18] showed after repair of the ulnar nerve at the wrist, 29% of the cases had an ulnar claw hand. Saur et al. [19] described 46% of 13 ulnar nerve lesions at the distal forearm improved motor function after 3 years postoperative evaluation. In Vordemvenne et al. [8] study, on average 60% recovery in ulnar nerve lesions at the wrist level was achieved.

Conclusion

These data shows that the most common mechanism of injury was laceration at all levels, and surgical results were generally better for lesions in continuity compared to lesions not in continuity. End-to-end direct suture had better prognosis than nerve graft repairs. Knowing the internal topography of ulnar nerve helps to suture more precisely which in turn may be the cause for achieving the best outcome at each level. The results in our series indicate that the outcome could be promising when repairing ulnar nerve injuries.

Conflict of Interest

We declare that there is no conflict of interest.

References

- Hundepool CA, Ultee J, Nijhuis TH, Houpt P, Research Group 'ZERO', et al. (2015) Prognostic factors for outcome after median, ulnar, and combined median-ulnar nerve injuries: a prospective study. *J Plast Reconstr Aesthet Surg* 68(1): 1-8.
- Woo A, Bakri K, Moran SL (2015) Management of ulnar nerve injuries. *J Hand Surg Am* 40(1): 173-181.
- Pfaeffle HJ, Waitayawinyu T, Trumble TE (2007) Ulnar nerve laceration and repair. *Hand clinics* 23(3): 291-299, v.
- Youmans JR, Winn HR (2001) Youmans neurological surgery. Saunders/Elsevier, Philadelphia, USA.
- He B, Zhu Z, Zhu Q, Zhou X, Zheng C, et al. (2014) Factors predicting sensory and motor recovery after the repair of upper limb peripheral nerve injuries. *Neural Regen Res* 9(6): 661-672.
- Vanderhooft E (2000) Functional outcomes of nerve grafts for the upper and lower extremities. *Hand clin* 16(1): 93-104, ix.
- Lad SP, Nathan JK, Schubert RD, Boakye M (2010) Trends in median, ulnar, radial, and brachio-plexus nerve injuries in the United States. *Neurosurgery* 66(5): 953-960.
- Vordemvenne T, Langer M, Ochman S, Raschke M, Schult M (2007) Long-term results after primary microsurgical repair of ulnar and median nerve injuries. A comparison of common score systems. *Clin Neurol Neurosurg* 109(3): 263-271.
- Murovic JA (2009) Upper-extremity peripheral nerve injuries: a Louisiana State University Health Sciences Center literature review with comparison of the operative outcomes of 1837 Louisiana State University Health Sciences Center median, radial, and ulnar nerve lesions. *Neurosurgery* 65(4 Suppl): A11-A17.
- Chow JA, Van Beek AL, Meyer DL, Johnson MC (1985) Surgical significance of the motor fascicular group of the ulnar nerve in the forearm. *J Hand Surg Am* 10(6 Pt 1): 867-872.
- Williams HB, Jabaley ME (1986) The importance of internal anatomy of the peripheral nerves to nerve repair in the forearm and hand. *Hand Clin* 2(4): 689-707.
- Sunderland S (1945) The intraneural topography of the radial, median and ulnar nerves. *Brain* 68: 243-299.
- Watchmaker GP, Lee G, Mackinnon SE (1994) Intraneural topography of the ulnar nerve in the cubital tunnel facilitates anterior transposition. *J Hand Surg Am* 19(6): 915-922.
- Slutsky DJ (2005) A practical approach to nerve grafting in the upper extremity. *Atlas Hand Clin* 10: 73-92.
- Kim DH, Han K, Tiel RL, Murovic JA, Kline DG (2003) Surgical outcomes of 654 ulnar nerve lesions. *J Neurosurg* 98(5): 993-1004.
- Secer HI, Daneyemez M, Gonul E, Izci Y (2007) Surgical repair of ulnar nerve lesions caused by gunshot and shrapnel: results in 407 lesions. *J Neurosurg* 107(4): 776-783.
- Bruyns CN, Jaquet JB, Schreuders TA, Kalmijn S, Kuypers PD, et al. (2003) Predictors for return to work in patients with median and ulnar nerve injuries. *J Hand Surg Am* 28(1): 28-34.
- Kilinc A, Ben Slama S, Dubert T, Dinh A, Osman N, et al. (2009) Results of primary repair of injuries to the median and ulnar nerves at the wrist. *Chir Main* 28(2): 87-92.
- Saur K, Bartos R, Sames M (2004) Results of reinnervation after peripheral nerve repair by a microsurgical technique used in 1996-1998. *Acta Chir Orthop Traumatol Cech* 71(5): 297-302.