

Thoracic spinal cord angiomatous malformation mimicking intramedullary tumor, associated with neurofibromatosis I (NF-1) and advanced scoliosis

Abstract

Spinal angiomas are very rare vascular malformations that are clinically presented by slowly progressive myelopathy or sudden neurological deterioration when they bleed. Early diagnosis and surgical removal is mandatory before a re-bleeding or a devastating lesion of the cord can occur.

A 35-year old man with severe thoracic scoliosis since late teenage and neurofibromatosis type I (NF-1) was gradually deteriorating, manifesting a spastic tetraparesis that was misinterpreted. Magnetic resonance images showed a space occupying lesion at D2-D5 level resembling an ependymoma or astrocytoma. The patient underwent surgical treatment and histology revealed an intramedullary angioma of venous type.

Keywords: Spinal angioma, Intramedullary, Scoliosis, Neurofibromatosis type I (NF-1), Intraoperative neuromonitoring (IONM)

Volume 2 Issue 6 - 2015

Kourtopoulos H, Derdilopoulos A, Andrikopoulou A, Kaklamanis L

Department of neurosurgery, neurophysiology and histopathology, Mediterraneo general Hospital, Greece

Correspondence: Kourtopoulos H, Department of neurosurgery, neurophysiology and histopathology, Mediterraneo general Hospital, Glyfada, Greece, Email hkourtopoulos@yahoo.com

Received: June 25, 2015 | **Published:** September 11, 2015

Introduction

Spinal vascular malformations account 3-12% of spinal space occupying lesions and include vertebral, extradural, dural, subpial and intramedullary angiomas which occur as isolated or complex vascular anomalies and may involve various covering layers at the same level.¹ They are either a/capillary telangiectasias with extra- or intradural and rarely intramedullary locations b/cavernomas, mainly in vertebral bodies/ venous angiomas, mainly in vertebral bodies and extradural spaces and d/ AVMs, the commonest type, which can affect the pial and radicular vessels that can penetrate the cord.

When angiomas bleed, depending on their location, can cause extradural, intradural, or subarachnoid hemorrhage, hematomyelia and thus compression lesions of the cord and ischemic changes resulting in progressive radiculo-myelopathy.

Chronic damage of the cord is due to pressure effects from space occupying lesions and thrombosis of the pathological/abnormal vessels.

Neurofibromatosis type I

Neurofibromatosis (von Recklinghausen) type 1 (NF-1) is a multisystem disease that may manifest as abnormalities of the nervous system, bones, soft tissue and skin. Persons who carry the gene eventually exhibit some clinical feature of the disease such as skeletal abnormalities and spinal deformities such as scoliosis or kyphosis, at least six or more café-au-lait spots, (>15mm in post pubertal individuals), first degree relative (parent, sibling or offspring) with NF-1, Lisch bodies in iris.²

Neurofibromatosis is also associated with tumors. Most tumors found in patients with NF-1 are benign skin tumors which grow on nerves throughout the body. Very seldom NF-1 is associated with malignant tumors. Neurofibromatosis is considered as member of the neurocutaneous syndromes called phakomatoses which in addition include tuberous sclerosis, Sturge-Weber syndrome and Von Hippel-Lindau disease.³

Scoliosis

Scoliosis is a medical condition in which a person's spinal axis has a three-dimensional deviation.⁴ It is typically classified as either congenital (15%) idiopathic (65%) or secondary (10%) to a primary condition. Secondary scoliosis can be the result of a neuromuscular condition (e.g. spina bifida, cerebral palsy, spinal muscular atrophy or physical trauma) or syndromes such as Chiari malformation, neurofibromatosis and tumors.⁵⁻⁷ Secondary scoliosis due to neuropathic or myopathic conditions can result in a loss of muscular support for the spinal column that can be pulled in abnormal directions. It is defined when the curvature is more than 10° to the right or left, is confirmed by x-rays, measured by a scoliometer and assessment of the Cobb angle (the angle between two lines, drawn perpendicular to the upper endplate of the uppermost vertebra involved and lower endplate of the lowest vertebra involved).

Intraoperative neuromonitoring (IONM)

Intraoperative neuromonitoring (IONM) is currently, a well established and an irreplaceable surgical tool in neurosurgery, especially in spinal cord operations. It gives important information to the surgeon for the neural tissue function and largely contributes to the best medical outcome and intraoperative safety since the best way to deal with a neurological damage is to prevent it.

The most common procedure for spinal cord neuromonitoring is by using evoked potentials in both directions, centrifugal as well as centripetal. The somatosensory evoked potentials (SEPs) can be measured after stimulation at the ankles or wrists and recording over the neck or scalp, depending on the spinal cord level involved. By this way, the spinal cord and the lemniscal sensory pathways are being continuously evaluated and the neurosurgeon can take the right decisions for the extend of the surgery. The use of SEPs have been shown to reduce postoperative neurological deficits associated with spinal surgery.^{8,9} However, the information derived from the SEPs is mediated only by the dorsal column pathways within the spinal cord and may be preserved despite damage to the ascending motor pathways. In addition motor evoked potentials (MEP) allows ongoing assessment of motor tract function during the operative procedure.

Presentation of the case

A 35-year old man, was admitted complaining of medium intensity back pain and progressive weakness of both lower extremities, worse on the left side. He had occasionally experienced 'pins and needles' sensation in the thoracic/abdominal region along with periods of gait disturbance. He was diagnosed by the age of 17 having a dextroscoliosis with Cobbs angle 24°. Several different bracing attempts had been made but with no improvement and he was told that the weakness of his left leg and atrophy was due to the increasing scoliosis. More than one and a half year before admission, his scoliosis had progressed with Cobbs angle advancing to 44° (Figure 1 & 2).

An attempt with a Regnier-Cheneau brace was tried but made him worse along with sudden spasticity, so, he was finally properly examined with an MRI of his thoracic spine. This showed an intramedullary lesion at D2-D5 level, with cranio-caudal length of 7 cm and cord width of 1,8cm (Figure 3 & 4).

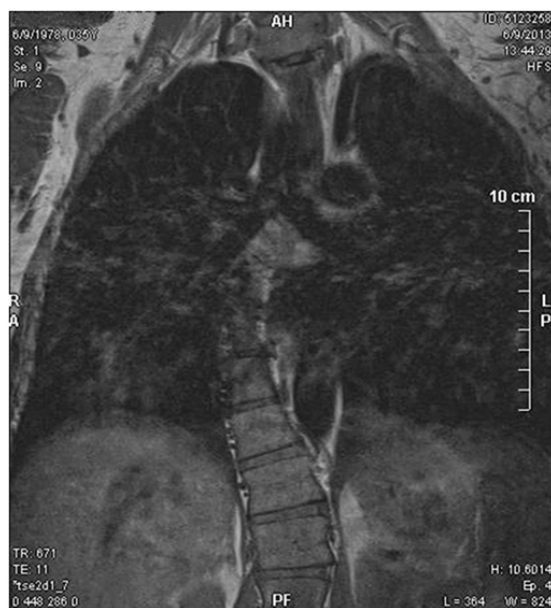

Figure 1

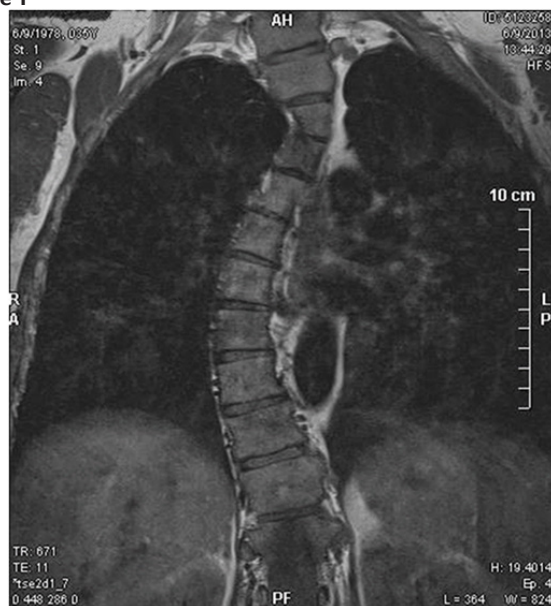

Figure 2

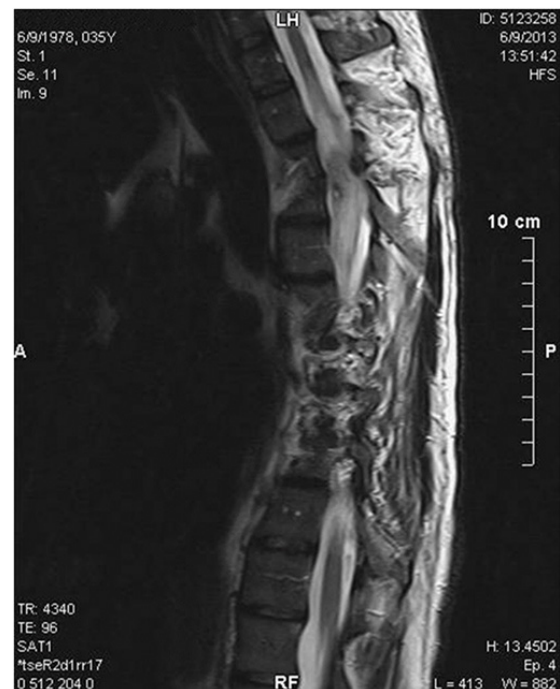

Figure 3

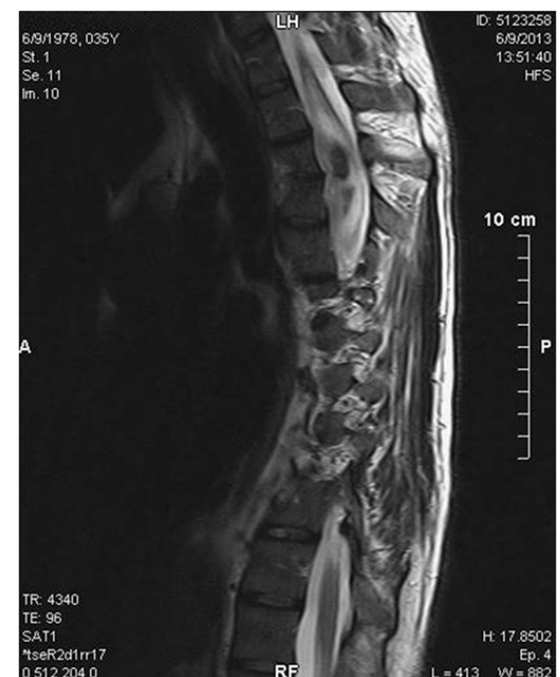

Figure 4

He was then told that this was probably an ependymoma or astrocytoma and since it looked slow growing, he could wait and see (!). He was also told that an attempt to remove it, should end up with a disaster and complete paraplegia. An MRI of his brain was also done showing signs of hydrocephalus with dilatation of the entire ventricular system.

Neurological examination in our institution revealed spastic paraparesis, especially left side, atrophy of his entire left leg, decreased pin-pricksensation below D3 and Babinski sign. Electromyogram

performed confirmed the clinical picture. The patient had an advanced kyphoscoliosis and his skin was covered with numerous wide (more than 15mm in diameter) café-au-lait spots. He had no Lisch bodies. His father and younger brother had also NF-1 manifestations. After a complementary 3D computerized tomography of his spine, the patient was brought to the operating theater and through a laminectomy at D2-D5 level the spinal cord was exposed showing a swelling due to an intramedullary lesion. The laminectomy was performed without muscle relaxants, thus allowing neuromonitoring of SEPs and MEPs. The dura was intact but tense and one could see through, a swollen cord and a cyst-like formation on the posterior aspect. By opening the arachnoid membrane a CSF containing cyst was emptied and dark green-bluish lesion appeared on the posterior and left aspect of the cord (Figure 5-8).

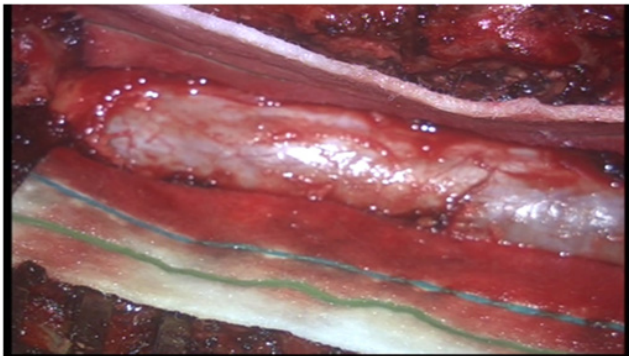


Figure 5 Before opening the dura.

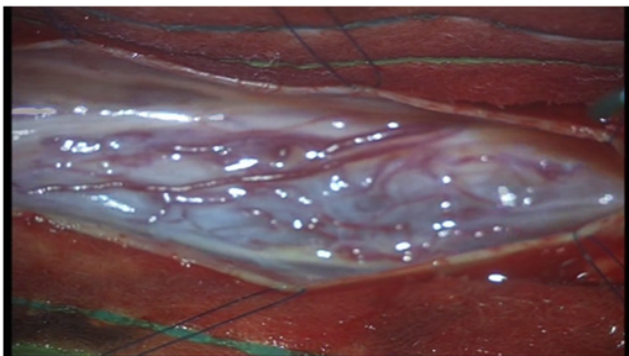


Figure 6 After opening the dura.

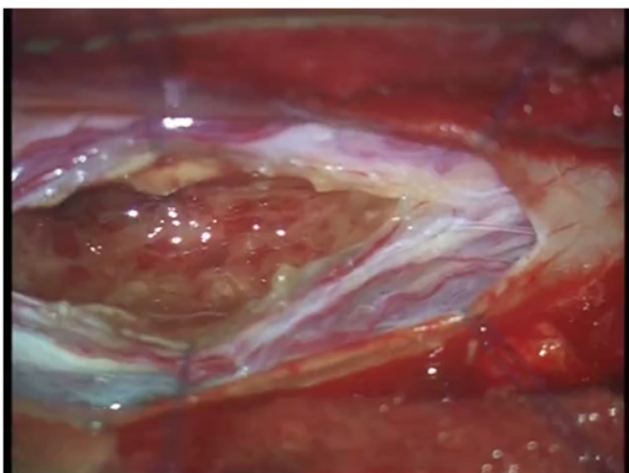


Figure 7 Dissection.

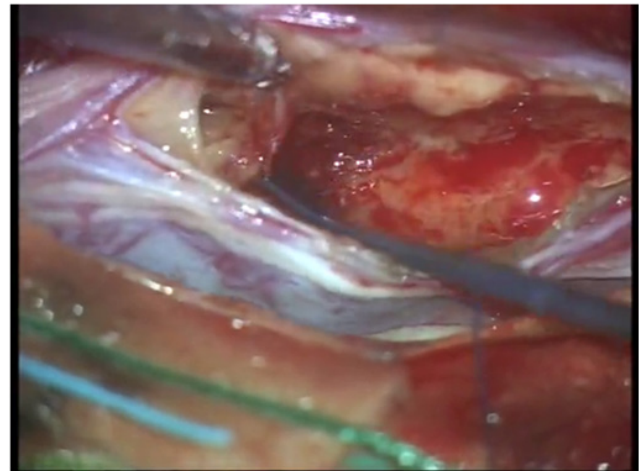


Figure 8 Removal.

With microsurgical technique and the use of cavitron ultrasonic aspiration, the lesion was carefully dissected out and totally removed, measuring approximately 5cm. Histological examination showed a vascular malformation, hemangioma of venous type (Figure 9 & 10).

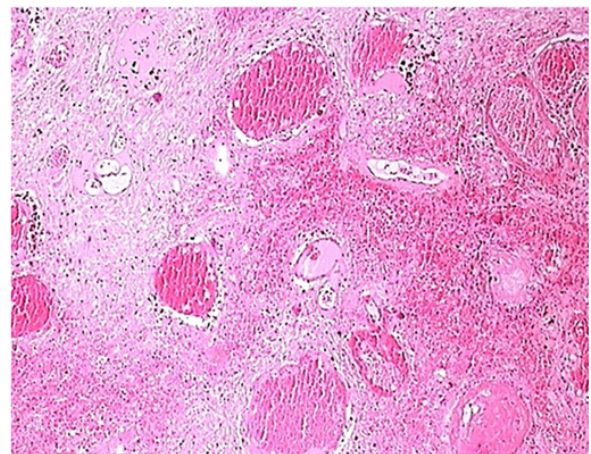


Figure 9 Haemangioma of venous type.

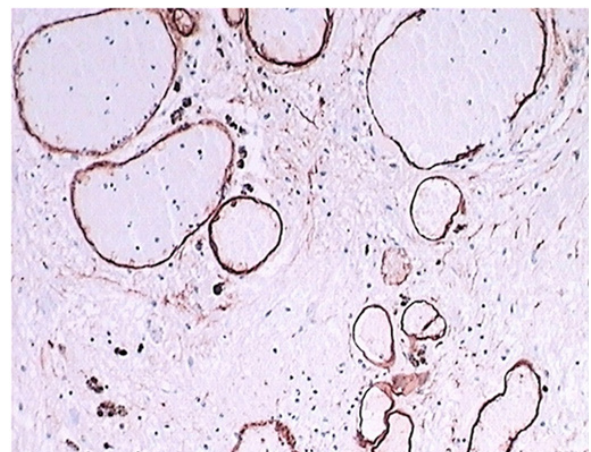


Figure 10 CD31 antibody staining the endothelial cells of the vessels.

As mentioned before, in the present case with the intramedullary lesion at Th2-Th5 level, the intraoperative neuromonitoring was done using a Nicolet Endeavor (CR) with : 1/ SEPs with stimulation of both posterior tibial nerves and recording at the paramedian

postcentral region at the skull and 2/ MEPs with transcranial electrical stimulation gradually at 100, 200, 300 and 400V, and recording at both sides of quadriceps, anterior tibial and gastrocnemius muscles. At the beginning no sensory or motor potentials were recorded. After the opening of the dura and the decompression, sensory evoked potentials were recorded (Figure 11 & 12).

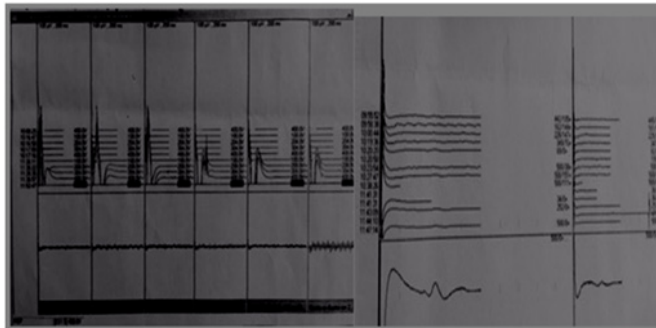


Figure 11 After opening the dura.

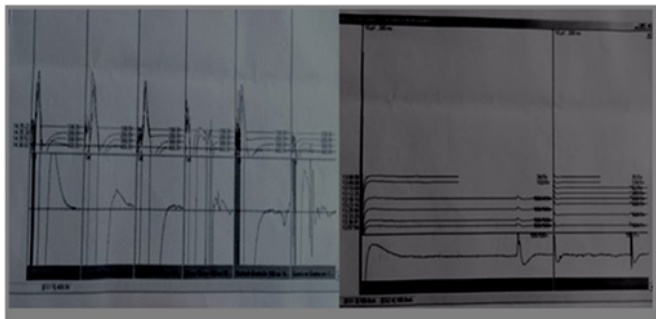


Figure 12 After partial removal of the lesion.

As well as motor potentials from the right anterior tibial muscle, the rightgastrocnemius muscle and less from the left gastrocnemius muscle. After partial resection of the tumorlike mass SEPs disappear, possibly because of subdural collection of air, while MEPs remained the same until the end of the operation.

The immediate postoperative course was uneventful and the patient was discharged on the 5th postoperative day with slightly increased weakness of the left leg but on re-examination a month postoperatively the patient had improved to almost normal ambulatory ability (McCormick scale II) walking carefully with no support.

Discussion

Vascular malformations of the central nervous system are usually slow-growing lesions that may enlarge by small bleedings, often clinically silent. They are built up by closely, abnormal thin walled sinusoidal spaces and veins, lined up by single layer of endothelium with no intervening nervous tissue.¹ After a bleeding they cause hemosiderin deposition in the surrounding neural tissue. The existence of cryptic veins together with small cavernous angiomas has been reported in the literature.¹⁰ Although there are no previous reports on venous angiomas inside the cord, such as in our patient, reports on cavernous angiomas showed that approximately 50% of the patients presented with progressive deficits while the remaining presented with acute or recurrent symptomatology.¹¹ Progressive neurological deterioration can be confused with demyelinating pathologies, myelitis, intramedullary tumors and spinal arteriovenous malformations.^{11,12} The co-existed neurofibromatosis (NF-I) with the big café-au-lait spots and the advanced scoliosis that increased from initially 24° to 44° made early diagnosis not possible although one

should expect that such an increase should raise natural suspicions! Neurofibromatosis is usually associated with tumors, muscle skeletal abnormalities and hydrocephalus so in this particular patient a correct diagnosis should have been made earlier but apparently it was not taken in consideration. However, the neuroradiological diagnosis was not easy. The advanced scoliosis did not make things easy for the radiologist and the suspicion of the lesion being a tumor was inevitable. Certainly, the decision to explore the lesion was mandatory in order to decompress the cord and get the right diagnosis.

The use of neuromonitoring is in all spinal surgery procedures mandatory. As SEPs and MEPs are mediated by different neural pathways within distinct vascular territories, monitoring of both can provide a more complete assessment of the spinal function. Furthermore, contemporary monitoring of both SEPs and MEPs provides an important measure of redundancy, as intraoperative injury often compromises both sensory and motor pathways.¹³ We keep in mind of course for technical factors such as electrical interference and the effect of anesthetic drugs. The importance of MEPs at this point has to be emphasized, because as long as they remained, it was safe for the surgeon to continue with the tumor resection, without putting the neurological integrity of the patient in danger. This could be confirmed later, postoperatively, by clinical evaluation.

Thus conclusively, intraoperative neuromonitoring is an essential tool for the surgeon in such operations, so that it can be stated, that intramedullary surgery without neuromonitoring, is a medical malpractice.

The appropriate treatment of spinal intramedullary angiomas depends on understanding the natural history of vascular malformations including the annual rate of hemorrhages and the importance of avoiding an increased deposition of hemosiderin, which may have neurotoxic effect with alteration of the surrounding microcirculation.¹⁰ Intramedullary lesions, e.g. tumors or vascular malformations, whenever diagnosed, should be surgically removed.

Acknowledgments

None.

Conflicts of interest

None.

References

1. Jellinger K. Vascular Malformations of the central nervous system: A morphological overview. *Neurosurg Rev.* 1986;9(3):177–216.
2. Crawford AH, Herrera-Soto J. Scoliosis associated with neurofibromatosis. *Orthop Clin North Am Oct.* 2007;38(4):553–662.
3. Fisher C. *USMLE, Master the Board, Step 2.* Kaplan Books pp.2010;287. ISBN.978–1–60714–653–7.
4. Trobisch P, Suess O, Schwab F. Idiopathic Scoliosis. *Deutsch Artzebl Int.* 2010;107(49):875–884.
5. Mc Aviney, Jeb. *Never Miss or Misdiagnose a Scoliosis Again.* Scolicare Chiropractors Assoc, Australia. 2014;pp.15–16.
6. Kouwenhoven JW, Castelein RM. *The pathogenesis of adolescent idiopathic scoliosis: review of the literature.* *Spine.* 2008;33(26):2898–2908.
7. Agabegi ED, Agabgi SS. *Step-Up to Medicine (step-up-series).* Lippincott Williams & Wilking, Hagerstown MD, USA. 2008;p.90.

8. Nuwer MR, Dawson EG, Carlsson LG et al. Somatosensory evoked potential spinal cord monitoring reduces neurological deficits after scoliosis surgery: results of a large multicenter survey. *Electroencephalogr Clin Neurophysiol*. 1995;96(1):6–11.
9. Staudt LA, Nuwer MR, Peacock WJ. Intraoperative monitoring during selective posterior rhizotomy: technique and patient outcome. *Electroencephalogr Clin Neurophysiol*. 1995;97(6):296–309.
10. Vishteh AG, Sankhla S, Anson JA, et al. Surgical resection of intramedullary spinal cord cavernous malformations: delayed complications, long-term outcomes, and association with cryptic venous malformations. *Neurosurgery*. 1997;41(5):1094–1100.
11. Kasukurthi R, Ray WZ, Blackburn SL, et al. Intramedullary capillary hemangioma of the thoracic spine: case report and review of the literature. *Rare Tumors*. 2009;1(1):e10.
12. Chung SK, Nam TK, Park SW, et al. Capillary hemangioma of the thoracic spinal cord. *J Korean Neurosurg Soc*. 2010;48(3):272–275.
13. Nagle KJ, Emerson RG, Adams DC, et al. Intraoperative monitoring of motor evoked potentials: a review of 116 cases. *Neurology*. 1996;47(4):999–1004.