

Rapid spontaneous resolution of acute cranial subdural hematomas - two case reports

Abstract

Acute cranial subdural hematoma (aSDH) is the consequence of traumatic brain injury, which most of them require immediate surgical intervention, especially when they have more than 10 mm of thickness. There are, however, reports of spontaneous resolution in some cases who were considered for conservative treatment. Two important mechanisms explained for this spontaneous resolution are “blood push-out” and “blood wash-out”. In this article, we discuss two cases of spontaneous resolution of acute cranial SDH, in addition to the reviewing proposed theories. It is possible to consider conservative management with ICU care for such patients if clinical and para-clinical conditions support this decision.

Keywords: Acute, Redistribution, Spontaneous resolution, Subdural hematoma, Cranial

Volume 1 Issue 6 - 2014

Mohammadreza Emamhady,¹ Shervin Ghadarjani²

¹Guilan University of Medical Sciences, Iran

²Department of Neurosurgery, Guilan University of Medical Sciences, Iran

Correspondence: Shervin Ghadarjani, Department of Neurosurgery, Poursina Hospital, Guilan University of Medical Sciences, Rasht, Iran, Tel -3227379, Email shervin.gh@gmail.com

Received: September 19, 2014 | **Published:** October 03, 2014

Abbreviations: aSDH, acute Subdural Hematoma; GCS, Glasgow Coma Scale; CT, Computed Tomography; MRI, Magnetic Resonance Imaging; ICU, Intensive Care Unit

Introduction

Acute Subdural Hematoma (aSDH) is the consequence of major trauma and occurs in 10-20% of all trauma cases, with a mortality rate of 50 to 85%.¹ The most common sites for aSDH are: fronto-parietal convexity, middle cranial fossa, and inter-hemispheric fissure.² Approach to an aSDH can be made based on the features of the hematoma on CT scan (i.e. A hematoma with a thickness greater than 10 mm or a midline shift greater than 5 mm almost always needs emergent surgery).^{3,4} On the other hand, conservative treatment is considered for aSDH with 3 mm or less in diameter. There is, however, controversy for an intermittent group of patients, in whom the hematoma has a thickness of 5–10 mm and their Glasgow Coma Scale is between 9 and 13.

Most of these intermittent cases will undergo urgent neurosurgical intervention,² but there are rare reports of spontaneous resolution of an acute SDH,⁵⁻²⁰ hence, a true estimate of their incidence is not available. The time required for spontaneous resolution in these reports differed between a few hours and a few days after injuries.^{5-16, 18-21} There are also reports of spontaneous resolution in patients with chronic SDHs.^{22,23}

In this article, we represent two cases of adult patients with post-traumatic aSDH, which were spontaneously resolved. We will also review some mechanisms described for this phenomenon.

Case presentation

Case 1

A 17 years old man was transferred to our hospital with a GCS score of 13 with the history of recent high-speed motor vehicle accident. The head CT scan demonstrated an aSDH with 1 cm thickness in the left fronto-temporal area with 1 mm midline shift (Figure 1A).

Based on the general status of the patient and the relative high GCS score, he was considered for close monitoring. Another head CT scan was obtained approximately 6 hours later, which showed almost complete resolution of the SDH. The level of consciousness of

the patient, also, maintained constant (Figure 1B). On next days, he progressively became more alert and was discharged, 7 days after his admission, without neurological deficits. He was visited at follow-up clinic two weeks later with no neurological deficits.

Case 2

A 17-year-old female was admitted to the emergency room after being involved in a high-speed motor vehicle accident with the initial GCS score of 12. Her regular blood work-up were within normal range. A head CT scan showed a right-sided fronto-temporal SDH (10 mm in its largest diameter) (Figure 1C), which was completely resolved in the control CT scan obtained 6 hours later (Figure 1D).

She became progressively more alert and finally discharged from the hospital ambulatory and neurologically intact seven days after her admission.

Discussion

The presence of an aSDH with a thickness more than 10 mm needs emergent surgical intervention, especially in the presence of loss of consciousness, mydriasis, or other neurological deficits.³⁻⁵ But there are reports of some spontaneous resolutions of acute SDH which happened between first 2 and 72 hours after the initial diagnosis.^{5-15, 18-21, 24-30} There are generally two important theories explaining this phenomenon: “CSF wash-out effect” through a tear in the arachnoid membrane,²⁷ and “hematoma push-out” via a tear in Dura.²⁶

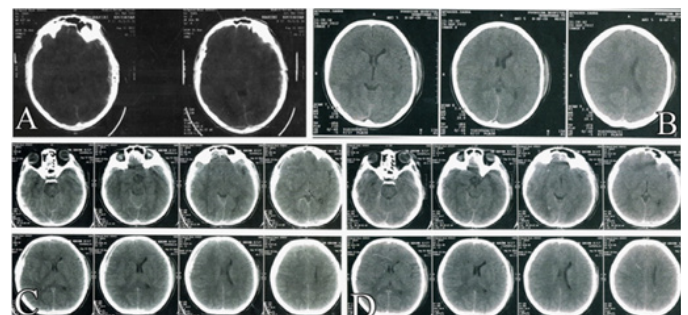


Figure 1 A. Case 1 Brain CT on admission and B. at 6 hours later. C. Case 2 Brain CT on admission and D. at 6 hours later.

It has been demonstrated that most cases of acute SDHs also have arachnoid tears permitting the CSF to transfer into the subdural space.³¹ The former theory explains that CSF comes out from these tears, washes the clots out, and this liquefied blood clot is redistributed to the subdural and subarachnoid spaces.^{12,15,24,27,31} This is shown by the presence of a low-density band between the subdural hematoma and inner table of the skull, and could be considered as a useful sign for a good prognosis.²¹ This mechanism is also supported by MRI findings^{27,31,32} that, redistribution of subdural hematoma was seen over both the cerebral convexities and the tentorium, forming a very thin and sharply demarcated layer.^{15,27} Some studies demonstrated a sub-acute spinal SDH after the spontaneous resolution of an acute cranial SDH.^{6,7} There is electron microscopic evidence of anatomical continuity of the intracranial and spinal subdural spaces.³³ These support the theory of redistribution of “blood clot-CSF” mixture to more dependent areas.^{6,7} We had not, unfortunately, an MRI confirmation for our patients to assess this theory.

The latter theory explains that the aSDH is being forced out of the subdural space via a tear in overlying Dura,^{20,26} or even to extracranial space via a fracture in the skull.^{16,34} The force for exiting the hematoma is made by the edema which has been shown to occur within 20–60 min after a severe head injury.^{35,36} In our series, however, no skull fractures were seen on the obtained CT scans.

Factors in favor of spontaneous resolution of subdural hematomas are: less than 30 mL of volume, fronto-temporal or temporo-parietal hematomas near the Sylvian fissure, association with iso-dense or hypo-dense space between the hematoma and the intracranial wall on CT scan, and association with cerebral edema and/or contusion and laceration, in neurologically stable patients of young age.³ It has been suggested that the young elastic brain parenchyma facilitates forcing out of the subdural brain clot,^{7,15,18} although, the presence of cortical atrophy is considered as a facilitator factor.^{8,9,15,32}

For the patients planned to undergo conservative management, close monitoring in an ICU is of importance. In addition, serial head CT scans are necessary for detecting any changes in the size of the SDH or finding any other concomitant brain injuries. It is apparent that any deterioration in the clinical neurological examination or changes in the appearance of the SDH on CT scan represents strong indications for emergent surgery.

Acknowledgments

None.

Conflicts of interest

None.

References

- Osborn A. *Diagnostic Neuroradiology*. St. Louis, Mosby, MO, USA, pp.1994;205–207.
- Tsui EY, Fai Ma K, Cheung YK, et al. Rapid spontaneous resolution and redistribution of acute subdural hematoma in a patient with chronic alcoholism: a case report. *Eur J Radiol*. 2000;36(1):53–57.
- Maas AI, Dearden M, Teasdale GM, et al. EBIC—guidelines for management of severe head injury in adults. European Brain Injury Consortium. *Acta Neurochir(Wien)*. 1997;139(4):286–294.
- Rockswold GL, Pheley PJ. Patients who talk and deteriorate. *Ann Emerg Med*. 1993;22(6):1004–1007.
- Abe T, Imaizumi Y, Mukasa A, et al. Acute subdural hematoma with rapid resolution: report of three cases. *No Shinkei Geka J*. 1999 ;(8):675–99.
- Ahn ES, Smith ER. Acute clival and spinal subdural hematoma with spontaneous resolution: clinical and radiographic correlation in support of a proposed pathophysiological mechanism. Case report. *J Neurosurg*. 2005;103(2 Suppl):175–179.
- Bortolotti C, Wang H, Fraser K, et al. Subacute spinal subdural hematoma after spontaneous resolution of cranial subdural hematoma: causal relationship or coincidence? Case report. *J Neurosurg*. 2004;100(4 Suppl Spine):372–374.
- Cohen JE, Eger K, Montero A, et al. Rapid spontaneous resolution of acute subdural hematoma and HIV related cerebral atrophy: case report. *Surg Neurol*. 1998;50(3):241–244.
- Edwards RJ, Britz GW, Critchley GR. Spontaneous resolution of an acute subdural haematoma. *Br J Neurosurg*. 2002;16(6):609–610.
- Fujioka S, Hamada J, Kaku M, et al. [Rapid resolution of acute subdural hematoma. Report of two cases]. *Neurol Med Chir(Tokyo)*. 1990;30(11 Spec No):827–831.
- Horimoto C, Yamaga S, Toba T, et al. A case of acute subdural hematoma with rapid resolution. *Nihon Kyukyū Igokukōi Zasshi*. 1993 ;(17):854–865.
- Inamasu J, Nakamura Y, Saito R, et al. Rapid resolution of traumatic acute subdural hematoma by redistribution. *Am J Emerg Med*. 2002;20(4):376–377.
- Izumihara A, Orita T, Tsurutani T, et al. [Natural course of non-operative cases of acute subdural hematoma: sequential computed tomographic study in the acute and subacute stages]. *No Shinkei Geka*. 1997;25(4):307–314.
- Joki T, Hashimoto T, Akachi K, et al. [Rapid resolution of acute subdural hematoma; report of two cases]. *No Shinkei Geka*. 1992;20(8):915–919.
- Kato N, Tsunoda T, Matsumura A, et al. Rapid spontaneous resolution of acute subdural hematoma occurs by redistribution – two case reports. *Neurol Med Chir(Tokyo)*. 2001 ;(41):140–143.
- Kundra SN, Kundra R. Extracranial redistribution causing rapid spontaneous resolution of acute subdural hematoma. *Neurol India*. 2005;53(1):124.
- Kuroiwa T, Tanabe H, Takatsuka H, et al. Rapid spontaneous resolution of acute extradural and subdural hematomas. Case report. *J Neurosurg*. 1993;78(1):126–128.
- Matsuyama T, Shimomura T, Okumura Y, et al. Rapid resolution of symptomatic acute subdural hematoma: case report. *Surg Neurol*. 1997;48(2):193–196.
- Mirzai H, Yaldiz C, Eminoglu M, et al. Neurological Picture. Ultra fast resolution of acute post-traumatic subdural haematoma. *J Neurol Neurosurg Psychiatry*. 2005;76(12):1738.
- Niikawa S, Sugimoto S, Hattori T, et al. Rapid resolution of acute subdural hematoma—report of four cases. *Neurol Med Chir(Tokyo)*. 1989;29(9):820–824.
- Suzuki Y, Kawamata T, Matsumoto H, et al. [A resolving sign of acute subdural hematoma: from report of two cases]. *No Shinkei Geka*. 1998;26(11):1025–1029.
- Gelabert-Gonzalez M, Iglesias-Pais M, Garcia-Allut A, et al. Chronic subdural hematoma:surgical treatment and outcome in 1000 cases. *Clin Neurol Neurosurg*. 2005;107(3):223–229.
- Voelker J. Nonoperative treatment of chronic subdural haematoma. *Neurosurg Clin N Am*. 2000;11(3):507–513.
- Aoki N. Acute subdural hematoma with rapid resolution. *Acta Neurochir(Wein)*. 1990;103(1–2):76–78.
- Arai H, Obba M, Obnuma T. Rapid spontaneous resolution of acute infantile subdural hematoma—a report of two cases. *Shoni No Shinkei*. 1990;(15):155–159.

26. Makiyama Y, Katayama Y, Ueno Y, et al. Acute subdural hematomas spontaneously disappearing within 3 days following closed head injury: report of two cases. *Nihon Univ J Med.* 1985;(27):123–127.
27. Polman CH, Gijssbers CJ, Heimans JJ, et al. Rapid spontaneous resolution of an acute subdural hematoma. *Neurosurgery.* 1986;19(3):446–448 .
28. Sato M, Nakano M, Sasanuma J, et al. Rapid resolution of traumatic acute subdural haematoma in the elderly. *Br J Neurosurg.* 2005;19(1):58–61.
29. Lee CH, Kang DH, Hwang SH, et al. Spontaneous rapid reduction of a large acute subdural hematoma. *Journal of Korean Medical Science.* 2009;24(6):1224–1226.
30. Rivas JJ, Dominguez J, Avila AP, et al. [Spontaneous resolution of an acute subdural hematoma]. *Neurocirugia(Astur).* 2002;13(6):486–490.
31. Wu MC, Liu JX, Luo GC, et al. Rapid natural resolution of intracranial hematoma. *Chin J Traumatol.* 2004;7(2):96–100.
32. Tsui EY, Fai Ma K, Cheung YK, et al. Rapid spontaneous resolution and redistribution of acute subdural hematoma in a patient with chronic alcoholism: a case report. *Eur J Radiol.* 2000;36(1):53–57.
33. Reina MA, De Leon Casasola O, Lopez A, et al. The origin of the spinal subdural space: ultrastructure findings. *Anesth Analg.* 2002;94(4):991–995.
34. Lou X, Yang R. Spontaneous resolution of acute subdural hematoma in 3 cases. *Chin J Traumatol.* 2000;(16):526.
35. Kobrine A, Timmins E, Rajjoub R, et al. Demonstration of massive traumatic brain swelling within 20 minutes after injury. Case report. *J Neurosurg.* 1977;46(2):256–258.
36. Waga S, Tochio H, Sakakura M. Traumatic cerebral swelling developing within 30 minutes after injury. *Surg Neurol.* 1979;11(3):191–193.