

Hepatic arterial mapping by ct angiography, cone beam ct and digital subtraction angiography

Abstract

Objectives: To determine the imaging modality that provided the greatest detail of the hepatic vasculature.

Background: Due to the embryonic origin of the hepatic vasculature, variations can occur. Accurate knowledge of the hepatic arterial anatomy is essential in the field of transarterial liver interventions, including chemo- and radioembolisation of liver metastasis, allowing accurate tumour targeting whilst minimising the risk of non-target embolisation.

Methods: 39 patients underwent work up for Selective Internal Radiotherapy. All had CT Angiography and Digital Subtraction Angiography (DSA) carried out and 22/39 underwent a DynaCT scan. The data was analysed retrospectively to determine vasculature branching, segmental vascularisation and Right Gastric Artery (RGA) origin.

Results: The vasculature variations found in our patients was comparable to previous studies using Michel's Classification. The CT Angiography only located the RGA origin in 12.8% of the patients and it was seen in 87.1% of DSAs carried out. RGAs not found on DSA were located on DynaCT. Vascularisation was comparable to previous data, with segment 4 of the liver being supplied by left-sided circulation in 78% of patients with standard branching anatomy.

Conclusion: Segmental vascularisation is a more relevant way to classify vasculature with respect to radioembolisation. DSA and DynaCT are useful at determining the RGA origin, with the latter providing more details of small vasculature.

Keywords: hepatic artery, ct angiography, cone beam ct, digital subtraction angiography

Volume 2 Issue 1 - 2016

Irfan A,¹ Weir G²¹University of Edinburgh, UK²Department of Radiology, University of Edinburgh, UK

Correspondence: Irfan A, College of Medicine and Veterinary Medicine, University of Edinburgh, Little France Crescent, Edinburgh, United Kingdom, EH16 4SA, Tel 07455 245 952, Email ahmerirfan@googlemail.com

Received: November 27, 2015 | **Published:** March 08, 2016

Abbreviations: ⁹⁰Y, ⁹⁰Yttrium; aLHA, accessory left hepatic artery; aRHA, accessory right hepatic artery; CBCT, cone beam CT; CHA, common hepatic artery; DSA, digital subtraction angiography; HAP, hepatic artery proper; LHA, left hepatic artery; MDCT, multi-detector CT; MHA, middle hepatic artery; RE, radio embolisation; RHA, right hepatic artery; rLHA, replaced left hepatic artery; rRHA, replaced right hepatic artery; SIRT, selective internal radiotherapy; SMA, superior mesenteric artery; VCS, volume coverage speed

Introduction

Liver anatomy

The hepatic artery origins differ considerably between an adult and an embryo. The intrahepatic portal vein system (originating initially from the vitelline veins) acts as a framework for the arterial vasculature, the growth of which is also closely related to the development of the biliary tree.^{1,2} Initially, the embryonic Middle Hepatic Artery (MHA) exists as an offshoot of the coeliac trunk during the 8th week of gestation, with further branches of the parenchyma becoming visible by the 10th week.³ Whilst the distribution is initially to the central zones (segments 3, 4, 5 and 8), by the 15th week it will reach the periphery, maintaining growth at the same rate as the liver.¹ An embryological Left Hepatic Artery (LHA) is an offshoot of the Left Gastric Artery (LGA) supplies segment 2, whilst segments 6 and 7 are supplied by a branch of the Superior Mesenteric Artery (SMA), the embryonic Right Hepatic Artery (RHA).⁴ As the distribution of

the embryonic MHA increases, the embryonic LHA and RHA regress to form the "normal" hepatic vasculature. Failure of this regression can lead to replaced or accessory hepatic arteries.⁵

The intricate variants that exist in hepatic vasculature were initially relevant only during conventional surgical procedures. However, as regional chemotherapy and radioembolisation (RE) have been developed during the last 20 years, these anatomical variations have become increasingly important to the interventional radiologist. In addition to precise targeting of the cancerous lesions, the inadvertent delivery of chemotherapy to non-target vessels can cause significant adverse effects including: irritation and necrosis of the gastric mucosa, gall bladder and small intestine.⁶ The hepatic vasculature classification was defined in 1966 through Michel's dissection of 200 autopsies, which has been the benchmark since (Table 1).⁷ This classification may be seen as outdated with respect to RE, as it includes no information on segmental anatomy or the origin of the RGA, and a new classification has been proposed, focussing on segmental distribution of the variable vasculature.⁵

As the right gastric artery is not the major contributor to the gastric bed, it is one that is often overlooked in literature relating to arterial variation. It is a highly variable artery, with studies showing it can arise from the hepatic artery proper (HAP), gastro duodenal artery (GDA) and the left, right, common or middle hepatic arteries.^{8,9,10} Identification of the right gastric artery is critical, for interventional radiologists, since inadvertent chemotherapy delivery to this artery

can result in significant gastric mucosal damage (necrosis, ulceration or perforation).^{6,9} Evidence shows that the correct identification and embolisation of the right gastric artery can reduce the incidence of these complications from 36% to 3%.¹¹

Table 1 Michel's Classification of Hepatic Vasculature.⁷

Michel's type	Description
I	RHA and LHA from CHA
II	RHA from CHA. Replaced LHA from LGA.
III	LHA from CHA. Replaced RHA from SMA.
IV	Replaced LHA from LGA. Replaced RHA from SMA.
V	RHA and LHA from CHA. Accessory LHA from LGA
VI	RHA and LHA from CHA. Accessory RHA from SMA.
VII	Accessory RHA from SMA and Accessory LHA from LGA Replaced RHA and Accessory LHA
VIII	OR Replaced LHA and Accessory RHA
IX	CHA from SMA
X	CHA from LGA

CHA, common hepatic artery; LGA, left gastric artery; LHA, left hepatic artery; RHA, right hepatic artery; SMA, superior mesenteric artery

Selective internal radiotherapy (SIRT)

SIRT initially gained approval in 2002 by the United States Food and Drug Administration (USFDA) for the treatment of hepatic metastases secondary to colorectal adenocarcinoma.¹² Access to the hepatic circulation is most commonly gained through the femoral artery to allow the delivery of ⁹⁰Yttrium (⁹⁰Y) microspheres which are selectively taken up by tumours, due to their predominant hepatic arterial supply.^{12,13} This allows lethal tumour doses to be delivered to cancerous cells whilst preserving and reducing the risk of complications in normal liver tissue.¹³

Imaging modalities

CT angiography was first born in 1994 by the combination of helical CT and graphical image processing, eventually overshadowing conventional angiography, which had been the gold standard of vascular imaging for the preceding 70 years.¹⁴ The advancement allowed high-speed (the entire liver volume can be mapped in one breath-hold), high-resolution, and highly accurate vasculature mapping with multi-planar reconstruction of the image.^{15,16} Image quality was governed by the volume coverage speed (VCS) of the scanner, which itself was dependant on the number of scanners used. Consequently, increasing the number of rows (of scanners) increased the VCS,¹⁷ progression of which has now led to 256-row CT as the (ideal) first line imaging modality for vasculature artery mapping.

Digital Subtraction Angiography (DSA) is a technique that allows imaging of vasculature through a combination of digitalised fluoroscopy (using systems that are highly sensitive to contrast) and temporal subtraction (which subtracts an image before contrast from one after, isolating the contrast filled vessels).¹⁸ The ability to inject contrast without the requirement to directly enter into the arterial circulation, as was the case with conventional angiography, was deemed as a major advantage in the development of DSA.¹⁹

The advancement of Cone Beam CT (CBCT) into the clinical setting has been limited by the progress of flat-panel fluoroscopy systems.²⁰ The use of a flat panel detector allows higher spatial resolution when compared to the image intensifier systems, the primary limitation when cone beam CT was first postulated in the 1980s.^{21,22} The primary difference between Cone-Beam CT and Multi-detector CT (MDCT) is the property of the detector itself. A two-dimensional detector is used in CBCT as opposed to the multiple one-dimensional detectors employed in MDCT.²³ CBCT use in hepatic interventional radiology potentially allows more selective catheterisation and deposition of therapeutic agents, increasing treatment efficacy and reducing damage to non-tumour tissue as well as better determinants of target tissue treatment.²⁰

There are three types of CBCT scanners that are commercially used, DynaCT (Siemens), XperCT (Phillips) and Innova CT (GE Healthcare). They vary in their rotation and reconstruction time, number of projections and image quality.²⁰ For the purposes of this study, CBCT will always refer to the DynaCT (and they may be used interchangeably).

This investigation plans to compare the hepatic vasculature of the sample population with the existing data, paying close attention to the origin of the right gastric artery. In doing so, it will also be possible to determine which of these imaging techniques provides the greatest detail in hepatic vasculature, critical for the accurate deposition of ⁹⁰Y.

Method

Patient selection

All patients included in this study had undergone scans as part of their management between March 2012 and May 2015 at the Royal Infirmary of Edinburgh. These patients all presented with metastatic liver disease secondary to colorectal cancer and were undergoing work up to assess suitability for SIRT following discussion in the Hepatobiliary Multi Disciplinary Meeting. Ethical Approval was obtained in March 2015.

Imaging

All patients underwent CT Angiography prior to SIRT. It was either carried out on the 128-slice CT Scanner at the treatment centre (Aquilion CX; Toshiba) or had been done by the patient's previous care team (maximum three months old, minimum requirements: 128-slice CT scanner). If carried out in the treatment centre, intravenous contrast (Iomeron 400; 60-70ml dependant on patient size) was injected at 4.5ml/sec (Medrad Infusion Pump) followed immediately by a saline bolus (70ml). Images were obtained with an automatic trigger (descending aorta; HU=180) to view the arterial phase (7 second delay pre-scan for breathing instructions) and portal phase (32second delay post arterial scan).

Patients then underwent two DSA procedures, approximately 7 to 14 days apart. The first of those (work-up DSA) was carried out to determine vessel patency and anatomy (and carry out any vessel embolisation if required). During this procedure, if required, a DynaCT (Artis Zee; Siemens) was carried out. The second DSA was carried out for delivery of SIR-Spheres (Yttrium-90; 30µm diameter; 64hours half-life; 100-1000⁺ Gy dose to tumour).

Image interpretation

All images were analysed on a workstation. The liver segments

were reviewed against Couinaud’s Classification during the portal phase. The hepatic vein distribution was used to determine the vertical scissurae with the portal vein determining the horizontal scissura.

The hepatic vasculature was then analysed during the arterial

phase (if taken in the treatment centre), or variable phases (if taken elsewhere) and followed to determine the Michel’s Classification (Table 1) and the segmental distribution (Figure 1). The naming of the artery supplying segment 4 was based on the study by van den Hoven.⁵ If visible; the origin of the RGA was also recorded

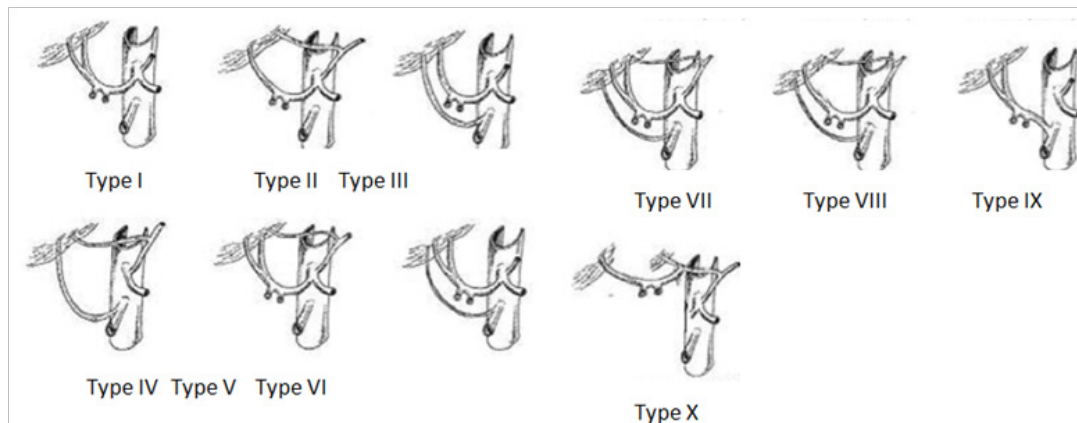


Figure 1 Michel’s Classification of Hepatic Vasculature.^{7,8}

After the CT images had been reviewed, the DSA-images was analysed to confirm the arterial branching and determine the origin of the RGA. If there was a requirement during the procedure, the CBCT was taken (variable entry dependant on reasoning). If possible, information regarding vasculature branching, RGA origin and segmental distribution was recorded.

Results

Of the 39 patients that were worked up for SIRT therapy, all underwent CT Angiography and DSA. 22/39 of these patients also underwent CBCT during the DSA procedure.

There were no discrepancies between the scans in determining

the Michel’s classification. These are listed below (Table 2) in comparison to previous (surgical and radiological) data. Any study that combined replaced and accessory arteries was not included, as accurate comparisons could not be made.

The segmental distribution was analysed on the CT Angiography and CBCT (Table 3). Any patient that had undergone a major resection (n=6) was not included in the analysis.

Both researchers also looked for the origin of the RGA on all three imaging modalities (Table 4). If the origin was at a bi- or trifurcation point then it was said to derive from the proximal artery (Example: the RGA coming off at the bifurcation of the CHA into the HAP and the GDA would be determined to arise from the CHA).

Table 2 Surgical and Radiological data analysing the variations in hepatic vasculature utilising Michel’s Classification

Author	Michel’s Classification/% (Rounded to Nearest 0.1%)										
	I	II	III	IV	V	VI	VII	VIII	IX	X	Unclassified
Irfan 2015	74.4	7.7	7.7	2.6	2.6	-	-	5.1	-	-	-
Michel’s 1966 ⁷	55	10	11	1	8	7	1	2	4.5	0.5	-
Suzuki 1971 ²³	70.5	8	3.5	-	4.5	4	-	-	3	-	6.5
Daly 1974 ²⁴	76	4	6	-	3.5	4	-	-	2	-	6
Rygaard 1986 ²⁵	75.5	4.6	13.4	0.9	-	-	0.5	0.5	1.4	-	-
Chen 1998 ²⁶	80.3	7.8	5.2	0.7	1.3	1.5	0.5	-	1.6	0	1.1
De Santis 2000 ²⁷	52	10	15.5	0.6	0.6	2	0.6	-	4	-	14.7
Covey 2002 ²⁸	61.3	4.5	12.2	-	15	2.5	1	3.2	2	-	-
Koops 2004 ²⁹	79.1	2.5	8.6	1	0.5	3.3	0.2	0.2	2.8	-	1.8
Yang 2009 ³⁰	70.2	2	9.8	0.6	-	-	-	-	2.3	0.4	5.2
Ugurel 2010 ³¹	54	11	17	1	10	1	-	-	-	-	1
Elkholy 2014 ³²	55	10	15	5	5	10	-	-	-	-	-
Hoven 2015 ⁵	66	8	15	3	1	-	1	2	1	-	-

Table 3 The main arterial branches are followed by their segmental territories of vascularisation in brackets

Coeliac axis	LGA	SMA	Irfan 2015/%	Hoven ⁵ 2015/%
No aberrant branches			69	66
LHA (2-4) and RHA (5-8)	-	-	54	46
LHA (2-3) and RHA (4-8)	-	-	15	19
Aberrant left hepatic artery			12	9
MHA (4) and RHA (5-8)	rLHA (2-3)	-	6	-
RHA (4-8)	rLHA (2-3)	-	3	6
LHA (3-4) and RHA (5-8)	aLHA (2)	-	3	1
Aberrant right hepatic artery			6	17
LHA (2-4)	-	rRHA (5-8)	6	14
Aberrant left and right hepatic arteries			9	6
-	rLHA (2-4)	rRHA (5-8)	3	1
RHA (5-8)	rLHA (2-4)	aRHA (5,8)	3	-
MHA (4) and RHA (6-8)	rLHA (2-3)	aRHA (5-6)	3	-

Not all of the variations determined by Hoven et al.⁵ are listed

LHA, left hepatic artery; RHA, right hepatic artery; MHA, middle hepatic artery; rLHA, replaced left hepatic artery; ALHA, accessory left hepatic artery; rRHA, replaced right hepatic artery; aRHA, accessory right hepatic artery

Table 4 The visibility and origin of the Right Gastric as viewed on three different imaging modalities

Origin of RGA	CT Angiography n=39	DSA n=39	CBCT n=22
Not Seen	34(87.1%)	3(7.7%)	4(18.2%)
HAP	1(2.6%)	8(20.5%)	2(9.1%)
CHA	-	8(20.5%)	1(4.5%)
RHA	-	4(10.3%)	-
LHA	4(10.3%)	13(33.3%)	5(22.7%)
MHA	-	1(2.6%)	-
GDA	-	1(2.6%)	-
Gastro-epiploic	-	1(2.6%)	-
Coiled	-	-	10(45.5%)

Discussion

Even though the sample size for this study (n=39) was smaller than many of the other studies focussing on the Michel's Classification, the results obtained are comparable and fit the trend. The most common pattern is the Michel's I(54-80.3%) classically deemed to be the standard branching anatomy, but there is significant variability in the other classifications, making it difficult to determine an accurate "order of prevalence".

S4 segment vascularisation

There is varying nomenclature to describe the arterial supply to segment 4 (S4) of the liver. In previous studies, the terms MHA and A4 (artery supplying segment 4) have been used interchangeably,³³⁻³⁶ but a distinction was made defining the MHA as a hilar branch from the CHA or PHA and A4 as a distal branch of the LHA or RHA.⁵ This definition has been utilised in the naming of S4 branches in this study.

In those patients that did not present with replaced or accessory arteries, it was found that the Left Hepatic Artery vascularised Segment 4 in 78% of cases. This was agreeable with 2 recent studies, which showed 70%⁵ and 61.5%³⁵ respectively of S4 supply originated from the LHA in the absence of aberrant arteries. However, there has been disagreement as to the most common origin of S4 blood supply with two newer studies reporting the RHA as the most common site for A4 branching (52%³⁴ and 65%³⁶ respectively in patients with no aberrant branches).

It was postulated that in the presence of replaced hepatic arteries, the origin of the artery supplying segment 4 would come from a branch of the coeliac axis.³⁶ Whilst this held mostly true in our study (78% of patients with replaced or accessory arteries), it was found that a S4 branch could arise from a replaced LHA (though not from an accessory LHA). This data was supported by a previous study⁵ which also demonstrated S4 vascularisation from a replaced RHA. Therefore, when determining the vascular supply of S4 in patients with aberrant arteries, it is not the origin of the artery that is important, rather the nature of the aberrance (replaced or accessory).

RGA origin

The sensitivity of CT Angiography to detect the RGA was low (12.8% in this study) with it not being found in the majority of scans. This may explain why previous radiological studies do not include the RGA^{5,24-26,28-30,32} whilst studying the variations in hepatic vasculature primarily utilising CT Angiography.

The radiological studies in which the RGA has been reported (Table 5)^{9,11,37,39,40} have utilised DSA (primarily whilst attempting to coil it for RE). These trials make no real distinction between aberrant or accessory arteries in the work up phase of the patients. DSA was significantly more sensitive to the RGA origin when compared to CT Angiography, detecting it in 87.2%.

In some of the scans utilised in this study, CBCT was used as

a “trouble-shooting” option for patients when the RGA was not visible using DSA. In all these cases, it was possible to determine its location; this finding is supported by data showing increased sensitivity, specificity and accuracy of CBCT compared to DSA when determining small arterial branches.³⁸ The current analysis is the first to review the use of CBCT in determining the RGA, as coiling

(and consequently identification) of both GDA and RGA is standard practice in the treatment centre. This had led to reduced gastric complications secondary to SIRT when compared to other centres, which is supported by previous data showing the significant decline in adverse effects (36% to 3%) when the RGA was coiled during infusional chemotherapy.¹¹

Table 5 The variations in origin of the Right Gastric Artery

Author	HAP/%	CHA/%	LHA/%	RHA/%	MHA/%	GDA/%
Irfan 2015	20.5	20.5	33.3	10.3	2.6	2.6
Daselar 1947 ³⁸	50	-	32.4	4	-	13.2
Eckmann 1984 ³⁹	53	24	15	-	-	8
Inaba 2001 ¹⁰	55.7	7.8	20.7	4.1	1.3	10.1
Yamagami 2002 ⁸	50.7	9.3	25.3	9.3	2.7	2.7
Cosin 2006 ³⁶	55	22	22	-	-	-

In some instances, the RGA could not be seen on the CBCT whilst it had been identified on the DSA. In these cases, the role of CBCT was not to determine the RGA but to determine detailed vascularisation of the tumour. When the CBCT was performed, contrast was infused distal to the origin of the RGA, and therefore no information on the RGA position was obtained.

Compared to previous published results of the RGA (Table 5), there is variation between the distributions of RGA origin. This may be due to the small population number that presented in our study, potentially giving a skewed view of the data. Another reason may be the naming of the origin of the RGA. In our study, if the RGA originated from a bi- or trifurcation, then the origin was determined to be the proximal artery. It was not stated how this was allocated in other trials and may account for the larger number of CHA originating RGAs in our trials compared to the majority.

Limitations

As in any study of a retrospective nature, there were limitations that need to be addressed. The use of CBCT in the scans utilised in this trial was not consistent, it was used to determine vessel location, extra-hepatic enhancement or check tumour perfusion. The vessels that were injected with contrast at the time of the scan varied based on the requirements for it. Due to this inconsistent approach to CBCT, it is hard to determine its true potential in this study. Trials that have utilised CBCT in the work up for ⁹⁰Y delivery in the treatment of hepatic malignancies^{41,42} found that CBCT provided more information in over half of the patients when compared to DSA. Whilst in some cases, the information was purely academic; it altered the treatment in 52%⁴¹ and 19% of patients.⁴² It may be considered that in the future work-up of SIRT patients, CBCT is carried out as standard practice as it may yield information that will allow more complete patient management.

Another limitation that was highlighted was the utilisation of Couinaud's classification of liver segments. Whilst it is an easily applicable concept to the liver anatomy of most patients, its accuracy is not infallible when compared across the entire population.⁴³ In the field of RE, this means that the expected target volume for SIRT may differ from the actual affected area. The use of CBCT in SIRT could allow exact arterial distribution to the liver to be mapped (as it provides soft tissue as well as vascular information).²⁰ This reduction in uncertainty of treatment targeting could cause a further reduction in complications from ⁹⁰Y damage to non-target tissues.

Conclusion

The classification for Hepatic vasculature proposed by Michel's has long been used in hepatic surgery. There are differing requirements during radioembolisation, and with the evolution of segmental approach and techniques a more useful and relevant arterial mapping classification specific to SIRT and liver directed arterial therapies is required. Whilst this can be determined using CT Angiography, the lack of visualisation of the RGA is a limiting feature. These can be identified using DSA and CBCT with the latter providing more detail in terms of small arterial branching. Considerations may be made to incorporate CBCT into standard SIRT therapy, though further data collection is required before this shift in clinical practice is viable.

Acknowledgements

None.

Conflict of interest

Author declares that there is no conflict of interest.

References

- Collardeau-Frachon S, Scoazec JY. Vascular development and differentiation during human liver organogenesis. *Anat Rec (Hoboken)*. 2008;291(6):614–627.
- Desmet VJ. Embryology of the liver and intrahepatic biliary tract, and an overview of malformations of the bile duct. In: MacIntyre N, Benhamou JP, Bircher J, editors. *Oxford textbook of clinical Hepatology*. England: Oxford University Press; 1991. p. 497–517.
- Gouysse G, Couvelard A, Frachon S, et al. Relationship between vascular development and vascular differentiation during liver organogenesis in humans. *J Hepatol*. 2002;37(6):730–740.
- Couinaud C. Surgical anatomy of the liver revisited: embryology. 1989.
- van den Hoven AF, van Leeuwen MS, Lam MG, et al. Hepatic arterial configuration in relation to the segmental anatomy of the liver; observations on MDCT and DSA relevant to radio embolization treatment. *Cardiovasc Intervent Radiol*. 2015;38(1):100–111.
- Liu DM, Salem R, Bui JT, et al. Angiographic considerations in patients undergoing liver-directed therapy. *J Vasc Interv Radiol*. 2005;16(7):911–935.
- Michels NA. Newer anatomy of the liver and its variant blood supply and collateral circulation. *Am J Surg*. 1966;112(3):337–347.

8. Lopez-Andujar R, Moya A, Montalva E, et al. et al. Lessons Learned From Anatomic Variants of the Hepatic Artery in 1,081 Transplanted Livers. *Liver Transplantation*. 2007;13(10):1401–1404.
9. Yamagami T, Nakamura T, Iida S, et al. Embolization of the right gastric artery before hepatic arterial infusion chemotherapy to prevent gastric mucosal lesions: approach through the hepatic artery versus the left gastric artery. *AJR Am J Roentgenol*. 2002;179(6):1605–1610.
10. VanDamme JP, Bonte J. *Vascular Anatomy in Abdominal Surgery*. 1st ed. New York, UK: Thieme; 1990.
11. Inaba Y, Arai Y, Matsueda K, et al. Right gastric artery embolization to prevent acute gastric mucosal lesions in patients undergoing repeat hepatic arterial infusion chemotherapy. *J Vasc Interv Radiol*. 2001;12(8):957–963.
12. Welsh JS, Kennedy AS, Thomadsen B. Selective Internal Radiation Therapy (SIRT) for liver metastases secondary to colorectal adenocarcinoma. *Int J Radiat Oncol Biol Phys*. 2006;66(2 Suppl):S62–73.
13. Stubbs RS, Wickremesekera SK. Selective internal radiation therapy (SIRT): a new modality for treating patients with colorectal liver metastases. *HPB (Oxford)*. 2004;6(3):133–139.
14. Rubin GD, Leipsic J, Joseph Schoepf U, et al. CT angiography after 20years: a transformation in cardiovascular disease characterization continues to advance. *Radiology*. 2014;271(3):633–652.
15. Kamel IR, Kruskal JB, Pomfret EA, et al. Impact of multi-detector CT on donor selection and surgical planning before living adult right lobe liver transplantation. *AJR Am J Roentgenol*. 2001;176(1):193–200.
16. Takahashi S, Murakami T, Takamura M, et al. Multi-detector row helical CT angiography of hepatic vessels: depiction with dual-arterial phase acquisition during single breath hold. *Radiology*. 2002;222(1):81–88.
17. Hu H, He HD, Foley WD, et al. Four multi-detector-row helical CT: image quality and volume coverage speed. *Radiology*. 2000;215(1):55–62.
18. Brody WR. Digital Subtraction Angiography. *IEEE Transactions on Nuclear Science*. 1982;29(3):1176–1180.
19. Tobis JM, Nalcioglu O, Henry WL. Digital subtraction angiography. *Chest*. 1983;84(1):68–75.
20. Wallace MJ, Kuo MD, Glaiberman C, et al. Three-dimensional C-arm cone-beam CT: applications in the interventional suite. *J Vasc Interv Radiol*. 2008;19(6):799–813.
21. Baba R, Konno Y, Ueda K, et al. Comparison of flat-panel detector and image-intensifier detector for cone-beam CT. *Comput Med Imaging Graph*. 2002;26(3):153–158.
22. Feldkamp LA, Davis LC, Kress JW. Practical Cone-Beam Algorithm. *J Opt Soc Amer*. 1984;1(6):612–619.
23. Orth RC, Wallace MJ, Kuo MD. Technology Assessment Committee of the Society of Interventional Radiology. C-arm cone-beam CT: general principles and technical considerations for use in interventional radiology. *J Vasc Interv Radiol*. 2008;19(6):814–820.
24. Suzuki T, Nakayasu A, Kawabe K, et al. Surgical significance of anatomic variations of the hepatic artery. *Am J Surg*. 1971;122(4):505–512.
25. Daly JM, Kemeny N, Oderman P, et al. Long-term hepatic arterial infusion chemotherapy. Anatomic considerations, operative technique, and treatment morbidity. *Arch Surg*. 1984;119(8):936–941.
26. Rygaard H, Forrest M, Mygind T, et al. Anatomic variants of the hepatic arteries. *Acta Radiol Diagn (Stockh)*. 1986;27(4):425–427.
27. Chen CY, Lee RC, Tseng HS, et al. Normal and variant anatomy of hepatic arteries: angiographic experience. *Zhonghua Yi Xue Za Zhi (Taipei)*. 1998;61(1):17–23.
28. De Santis M, Ariosi P, Calo GF, et al. Hepatic arterial vascular anatomy and its variants. *Radiol Med*. 2000;100(3):145–151.
29. Covey AM, Brody LA, Maluccio MA, et al. Variant hepatic arterial anatomy revisited: digital subtraction angiography performed in 600 patients. *Radiology*. 2002;224(2):542–547.
30. Koops A, Wojciechowski B, Broering DC, et al. Anatomic variations of the hepatic arteries in 604 selective celiac and superior mesenteric angiographies. *Surg Radiol Anat*. 2004;26(3):239–244.
31. Yang SH, Yin YH, Jang J, et al. Establishment of a Guideline for the Safe Management of Anatomical Hepatic Artery Variations While Performing Major Hepato-pancreatico-biliary Surgery. *Journal of the Korean Surgical Society*. 2009;76(2):100–108.
32. Ugurel MS, Battal B, Bozlar U, et al. Anatomical variations of hepatic arterial system, coeliac trunk and renal arteries: an analysis with multi-detector CT angiography. *Br J Radiol*. 2010;83(992):661–667.
33. Elkholy MR, Elshazly HM. Role of three-dimensional multi-detector computed tomography angiography of hepatic vessels in the evaluation of living donors. *Menoufia Medical Journal*. 2014;27(1):157–163.
34. Jin GY, Yu HC, Lim HS, et al. Anatomical variations of the origin of the segment 4 hepatic artery and their clinical implications. *Liver Transpl*. 2008;14(8):1180–1184.
35. Onishi H, Kawarada Y, Das BC, et al. Surgical anatomy of the medial segment (S4) of the liver with special reference to bile ducts and vessels. *Hepatogastroenterology*. 2000;47(31):143–150.
36. Wang S, He X, Li Z, et al. Characterization of the middle hepatic artery and its relevance to living donor liver transplantation. *Liver Transpl*. 2010;16(6):736–741.
37. Cosin O, Bilbao JI, Alvarez S, et al. Right Gastric Artery Embolization Prior to Treatment with Yttrium-90 Microspheres. *Cardiovasc Intervent Radiol*. 2007;30(1):98–102.
38. Iwazawa J, Ohue S, Mitani T, et al. Identifying feeding arteries during TACE of hepatic tumors: comparison of C-arm CT and digital subtraction angiography. *AJR Am J Roentgenol*. 2009;192(4):1057–1063.
39. Daseler EH, Anson BJ. The cystic artery and constituents of the hepatic pedicle; a study of 500 specimens. *Surg Gynecol Obstet*. 1947;85(1):47–63.
40. Eckmann I, Krahn V. Frequency of different sites of origin of the right gastric artery. *Anat Anz*. 1984;155(1–5):65–70.
41. Louie JD, Kothary N, Kuo WT, et al. Incorporating cone-beam CT into the treatment planning for yttrium-90 radioembolization. *J Vasc Interv Radiol*. 2009;20(5):606–613.
42. Wallace MJ, Murthy R, Kamat PP, et al. Impact of C-arm CT on hepatic arterial interventions for hepatic malignancies. *J Vasc Interv Radiol*. 2007;18(12):1500–1507.
43. Strunk H, Stuckmann G, Textor J, et al. Limitations and pitfalls of Couinaud's segmentation of the liver in transaxial Imaging. *Eur Radiol*. 2003;13(11):2472–2482.