

# Cavernous sinus thrombosis case report

## Case scenario

- A Sudanese male 45years old medically has a history of poor controlled diabetes mellitus complaining from pain full swelling in the left side of the face after 48hours spread to the other side.
- Patient had shooting vital signs (pyrexia, tachypnea and tachycardia).
- Extra-oral examination, proptosis, dilated fixed pupils, ptosis, papill oedema, pus discharge and paralysis of extra ocular muscles.
- Intra-oral examination, a firm swelling with badly carious left upper canine (Figures 1-4).

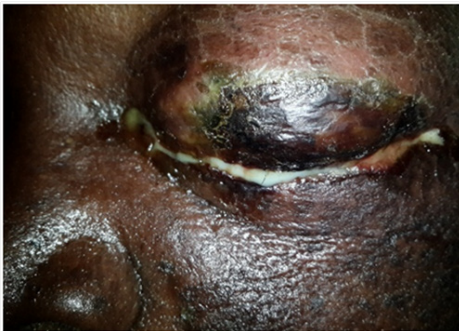

Figure 1 Shows pus discharge and proptosis in the left eye.

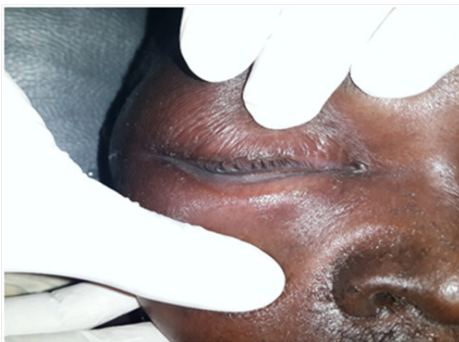

Figure 2 Shows complete ptosis of the right eye after 72hours.

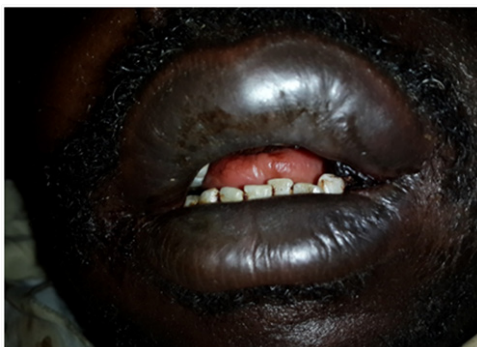

Figure 3 Shows swollen upper lip.

Volume 3 Issue 1 - 2016

Yousif I Eltohami, Amal H Abuaffan

Faculty of Dentistry, University of Khartoum, Sudan

**Correspondence:** Amal H Abuaffan, Faculty of dentistry, University of Khartoum, Sudan, Email amalabuaffan@yahoo.com

**Received:** April 26, 2016 | **Published:** September 16, 2016

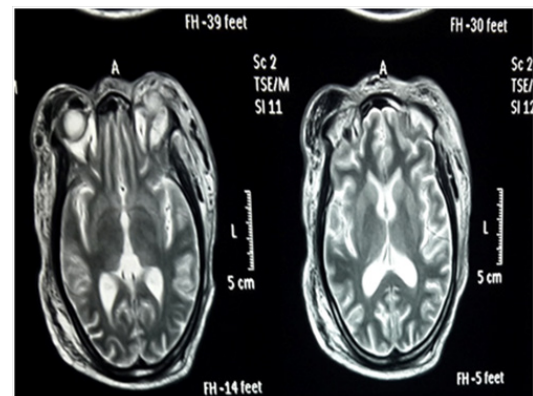


Figure 4 Shows T2 weighed MRI Showed bilateral involvement of the eyes.

## Acknowledgements

None.

## Conflict of interest

Author declares that there is no conflict of interest.