

Use of a smartphone ECG monitor to identify electrocardiogram abnormalities due to hyperkalemia from urinary obstruction in a Jacob's sheep

Abstract

Smartphone-based ECGs present a diagnostic opportunity for large animal practice. A two year old Jacob's sheep presented with severe hyperkalemia secondary to a urinary obstruction. Collection of an electrocardiogram from a smart-phone based device demonstrated altered waveforms typical of severe hyperkalemia. The patient was successfully managed with medical and surgical therapies. This case presents that the method of collecting a smartphone-based ECG as determined for other large animal species, may be applicable to sheep. Additionally, this report demonstrates that the smartphone-based device may be sensitive enough to detect the absence of a P wave as commonly encountered with cases of hyperkalemia.

Keywords: electrocardiogram, hyperkalemia, sheep, smartphone, urolithiasis

Volume 9 Issue 6 - 2020

Joe S Smith

Large Animal Clinical Sciences, University of Tennessee,
Knoxville, TN, USA

Correspondence: Joe Smith, LACS, University of Tennessee
College of Veterinary Medicine, Knoxville, TN,
Email jsmit04@utk.edu

Received: November 03, 2020 | **Published:** December 21, 2020

Introduction

Smartphone-based diagnostics are becoming increasingly more utilized by ambulatory veterinary practitioners.¹ An exciting new example of this powerful and portable technology is the AliveCor ECG device (AliveCor). The AliveCor allows the smart phone user to utilize their smartphone for the collection of heart rhythm, and rate in the form of an electrocardiogram (ECG) that can be instantaneously evaluated as well as recorded for future use. In addition to determination of average heart rate, these devices can be used to identify sinus rhythm, atrial fibrillation and ventricular premature complexes, ventricular pre-excitation and asynchronous ventricular depolarization by a trained veterinarian.² In some cases the device is replacing the traditional Holter monitor for ECG monitoring due to its portability and ease of use.² The product instructions describe the use for canine, feline, and equine patients. However, there are reports in the literature of the use of the device in other species including cattle,³ goats,^{4,5} water buffalo,^{6,7} pigs,⁸ as well as exotic species such as Harbor Seals⁹ and Savannah Monitors.¹⁰

Urolithiasis is a common condition in small ruminants. Occurring more commonly in males than females it is associated with multiple types of calculi. Treatment options include medical and surgical management, as well as a combination of both methods. Multiple preventive measures have been utilized for this condition. If left unmanaged urolithiasis can commonly lead to bladder or urethral rupture, with grave consequences for the patient. In addition to bladder rupture, the metabolic disturbances from urinary obstruction, such as azotemia or hyperkalemia can present a severe risk to the patient. On ECG patients with hyperkalemia can present with a widening of the QRS complex, tented T waves, and absent P waves.¹¹ Often overlooked in ambulatory settings are the cardiac effects of obstructive urolithiasis. In this case report we present the derangement of a normal ECG rhythm due to hyperkalemia from obstructive urolithiasis in a sheep.

Material and methods

A two year old Jacob's four-horned sheep was presented to the livestock medicine and surgery service for evaluation following approximately one week of acting depressed with reduced activity and appetite. The clients reported that they had not observed the animal urinate within the previous seventy-two hours prior to presentation. The animal had been castrated at several weeks of age and had been fed an *ad libitum* grain diet. The clients had three other sheep and no previous medical issues had been reported in the flock. No routine deworming was performed and all animals were annually vaccinated with a commercial *Clostridium perfringens* type C and D and tetanus product.

Results

Physical examination revealed the sheep to be tachycardic (115 beats per minute, normal: 70-90) with decreased ruminations and a "hunched" abdominal posture. Digital rectal examination revealed the presence of urethral spasms. Ultrasound of the abdomen demonstrated a markedly enlarged urinary bladder (10.5 cm diameter; normal reference range <6 cm). Due to concerns of obstructive urolithiasis from the physical examination a point of care serum biochemistry examination was performed. Bloodwork showed an animal that was azotemic, as well as markedly hyperkalemic (Potassium: 9.2 mEq/L; reference range 4.2-6.2 mEq/L). The ECG was collected caudal to the left elbow as previously reported.^{3,4,6} The area was clipped of hair, and then a small amount of isopropyl alcohol was applied to the skin to improve contact. This proved to be too much, as the resulting image was indecipherable (Figure 1). The area was dried, and a small amount of ultrasound gel was applied to the skin to facilitate contact. This image was of diagnostic quality (Figure 2). The patient's urinary obstruction was relieved with a percutaneous suprapubic catheter as previously reported.¹² After twenty-four hours of fluid therapy the urinary obstruction was relieved via a tube cystostomy procedure and the animal was discharged from the hospital ten days postoperatively.

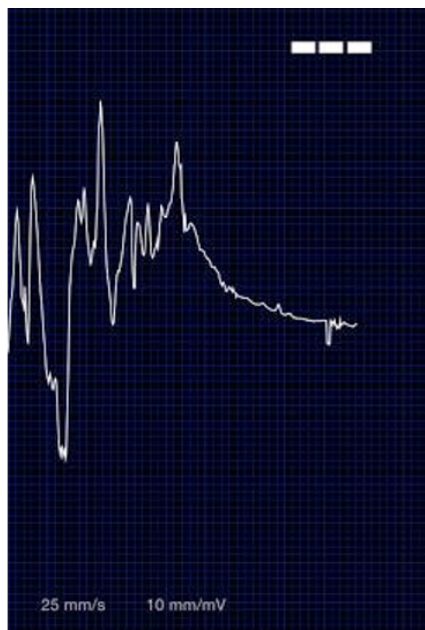


Figure 1 This initial attempt to record the electrocardiogram (ECG) from the hyperkalemic whether. Too much alcohol was applied to the skin, leading to background noise or “scatter” being displayed instead of an ECG rhythm.

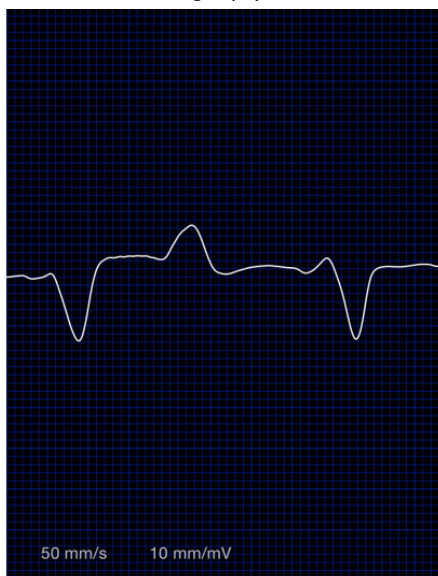


Figure 2 An ECG recorded from the hyperkalemic whether shortly after presentation to the veterinary hospital. Note the absence of a “P” wave before the QRS complex in this rhythm.

Discussion

Herein is reported the use of a commercial smartphone ECG monitor for the absence of a P wave presumably secondary to hyperkalemia due to obstructive urolithiasis in a Jacob's sheep. Diagnosis of urolithiasis in small ruminants is made based on history, signalment, physical examination findings, and in some situations ancillary diagnostic testing. Common presentation for urolithiasis are castrated males, and to a less frequent extent intact males on high-concentrate diets. In addition to castrated males being more commonly affected, smaller or dwarf breeds have also been shown to more likely develop urolithiasis.¹³ Presentation is typically non-specific, with tenesmus, anuria, vocalization, and anorexia all being common for initial presentation. Some cases of urolithiasis, such as struvite, may

present with a “gritty” texture to the hair of the distal prepuce of the patient, where small crystals have accumulated. In some patients a rigid bladder can be palpated externally, although care should be taken when palpating a bladder with an animal with a suspected urethral obstruction, as bladder distention could lead to a predisposition for bladder rupture. Another common physical examination finding is pulsation of the urethra on digital palpation of the rectum. Often ultrasound or radiographic imaging is utilized to identify bladder distention and radiopaque uroliths. For regions where the common calculi observed in small ruminants are radiopaque (such as calcium carbonate, calcium oxalate, and silica uroliths) plain radiographs are recommended when considering a surgical solution.¹⁴ Common laboratory findings for urolithiasis include higher blood urea nitrogen (BUN), creatinine, potassium, and glucose concentrations and lower mean phosphorus, sodium, and chloride concentrations.¹³ This same study reported that goats with uroliths had higher frequency of azotemia, hypophosphatemia, hypochloridemia, than control goats. Increased BUN, creatinine, and potassium are due to decreased voiding, and hyperglycemia can be seen as a stress response.

The absence of P waves on an ECG is a common occurrence of hyperkalemia.¹¹ Initially tall or “tented” T waves can be present, and then as the potassium concentration increases P waves can disappear entirely.¹⁵ This increase in potassium can ultimately lead to the depolarization of the membrane potential of cardiac cells and lead to fatal arrhythmias.¹⁵ Fortunately for our patient, the relief of urinary obstruction and fluid therapy allowed for a reduction in serum potassium levels. Most of the large animal veterinary literature demonstrates the use of smartphone-based ECGs for the determination of normal sinus rhythms, as has been demonstrated in cattle,³ goats,⁴ and water buffalo calves.^{6,7} The next step for determining the utility of this diagnostic approach would be the use for the real-time diagnosis of altered ECGs. This has been proven effective in people¹⁶ for the monitoring of supraventricular tachycardia¹⁷ and palpitations;¹⁸ as well as in dogs.¹⁹ This case report demonstrates primary feasibility for the determination of altered ECGs in sheep with a smartphone-based ECG monitor. Future studies should examine large populations of sheep for determination of validity of this device on a population basis.

Conclusion

In conclusion, this case presents that the method of collecting a smartphone-based ECG as determined for other large animal species, may be applicable to sheep. Additionally, this report demonstrates that the smartphone-based device may be sensitive enough to detect the absence of a P wave as commonly encountered with cases of hyperkalemia.

Acknowledgments

None.

Conflicts of interest

The author declares no conflict of interest exists.

References

1. Smith J. Smartphone Diagnostics for the Ambulatory Practitioner. *Colorado Veterinary Medical Association*; 2018.
2. Brložnik M, Avbelj V. *Wireless electrocardiographic monitoring in veterinary medicine. Information and Communication Technology. Electronics and Microelectronics (MIPRO), 2015 38th International Convention on*; 2015: IEEE.

3. Bonelli F, Vezzosi T, Meylan M, et al. Comparison of smartphone-based and standard base-apex electrocardiography in healthy dairy cows. *Journal of veterinary internal medicine*. 2019;33(2):981–986.
4. Smith JS, Ward JL, Schneider BK, et al. Comparison of Standard Electrocardiography and Smartphone-Based Electrocardiography Recorded at Two Different Anatomic Locations in Healthy Meat and Dairy Breed Does. *Frontiers in Veterinary Science*. 2020;7(416).
5. Smith J, Heller M, Smith F. Use Of An AliveCor Heart Monitor For Heart Rate And Rhythm Evaluation In Domestic Goats. *Journal of Veterinary Internal Medicine*. 2016;30(4):1516.
6. Smith J, Ward J, Urbano T, et al. Use of AliveCor Heart Monitor for Heart Rate and Rhythm Evaluation in Dairy Water Buffalo Calves (Bubalis Bubalis). *J Dairy Vet Anim Res*. 2016;4(2):00113.
7. Smith J, Ward J, Urbano T, Mueller M. Use of AliveCor heart monitor for heart rate and rhythm evaluation in domestic water buffalo calves. *J Dairy Vet Anim Res*. 2016;94:261–264.
8. Madariaga M, Michel S, Tasaki M, et al. Induction of cardiac allograft tolerance across a full MHC barrier in miniature swine by donor kidney cotransplantation. *American Journal of Transplantation*. 2013;13(10):2558–2566.
9. Fonfara S, Casamian Sorrosal D, Sundermeyer J, et al. Variations in heart rate and rhythm of harbor seal pups during rehabilitation. *Marine Mammal Science*. 2014.
10. Cushing AC, Ossiboff RJ, Knafo SE, et al. Coelomic and Pericardial Effusion Associated with Mesothelioma in a Savannah Monitor (Varanus exanthematicus). *Journal of Herpetological Medicine and Surgery*. 2014;24(3):66–71.
11. Pothiwala SE. Hyperkalemia induced pseudo-myocardial infarction in septic shock. *J Postgrad Med*. 2014;60(3):338–340.
12. Chigerwe M, Heller MC, Balcomb CC, et al. Use of a percutaneous transabdominal catheter for management of obstructive urolithiasis in goats, sheep, and potbellied pigs: 69 cases (2000–2014). *Journal of the American Veterinary Medical Association*. 2016;248(11):1287–1290.
13. George JW, Hird DW, George LW. Serum biochemical abnormalities in goats with uroliths: 107 cases (1992–2003). *Journal of the American Veterinary Medical Association*. 2007;230(1):101–106.
14. Kinsley MA, Semevolos S, Parker JE, et al. Use of plain radiography in the diagnosis, surgical management, and postoperative treatment of obstructive urolithiasis in 25 goats and 2 sheep. *Veterinary Surgery*. 2013;42(6):663–668.
15. Campese VM, Adenuga G. Electrophysiological and clinical consequences of hyperkalemia. *Kidney Int Suppl*. 2016;6(1):16–9.
16. Garabelli P, Stavrakis S, Po S. Smartphone-based arrhythmia monitoring. *Current opinion in cardiology*. 2017;32(1):53–57.
17. Ferdman DJ, Liberman L, Silver ES. A Smartphone Application to Diagnose the Mechanism of Pediatric Supraventricular Tachycardia. *Pediatric cardiology*. 2015;36(7):1452–1457.
18. Peritz DC, Howard A, Ciocca M, et al. Smartphone ECG aids real time diagnosis of palpitations in the competitive college athlete. *Journal of electrocardiology*. 2015;48(5):896–899.
19. Vezzosi T, Tognetti R, Buralli C, et al. Home monitoring of heart rate and heart rhythm with a smartphone-based ECG in dogs. *Vet Rec*. 2019;184(3):96.