

# Prevalence of dermatophytosis in rabbits at Saqtvh, Chittagong, Bangladesh

## Abstract

Dermatophytosis or ringworm is a superficial cutaneous infection with one or more of the fungal species of the keratinophilic genera. The genera include *Microsporum*, *Trichophyton* and *Epidermophyton* which were zoonotic and have a great public health impact. The aim of this study was to find out the prevalence of specific types of fungus that are responsible for dermatophytosis among the hospitalized rabbits at SAQ-Teaching Veterinary Hospital (SAQTVH) of Chittagong Veterinary and Animal Sciences University (CVASU), Bangladesh. A total of 9 skin scraping samples were collected by using scalpel from the rabbit that were suspected as dermatophytosis based on gross lesion on their body surface. Some samples (Hair and scrapings) were mounted for direct examination in 40% KOH and heated for 60 seconds and examined under light microscope in 400 magnifications to observe fungal morphology. Rest of the samples was preserved at room temperature (25°C) in zipper bag for fungal isolation and identification. Sabouraud's dextrose agar plates, containing 0.02% Cycloheximide and 0.3% Depomycin was used to fungal culture and the specific types of fungus were identified based on colony characteristics. *Trichophyton Mentagrophytes* was the most common fungal species isolated from rabbits. Among the suspected patients the prevalence of *T. Mentagrophytes* was 89%.

There observed insignificant ( $p>0.05$ ) effects of sex, age, body weight and deworming status for the occurrence of dermatophytosis in rabbit. The current study limited only on the hospitalized suspected patients, so a comprehensive study considering the sample from whole rabbit population is required to find out the actual prevalence of the fungal species.

**Keywords:** cutaneous infection, rabbit, dermatophytosis, prevalence, zoonotic

Volume 3 Issue 6 - 2016

Jagannath Chandra Dey, Md. Kaiser Rahman, Md. Aftabuddin Rumi, Avijit Dutta, Bhubon Chandra Halder, Abdul Mannan, Mohammad Mahmudul Hassan, Md. Saddam Hossain  
Chittagong Veterinary and Animal Sciences University, Bangladesh

**Correspondence:** Md. Saddam Hossain, Faculty of Veterinary Medicine, Chittagong Veterinary and Animal Sciences University, Khulshi, Chittagong-4225, Bangladesh, Tel +08 8016 8127 2616, Email drsaddamcvasu@gmail.com

**Received:** August 18, 2016 | **Published:** August 31, 2016

## Introduction

Rabbits are calm by nature. They are extremely delicate animals and are prone to many bacterial, fungal or parasitic skin diseases if proper care is not taken. Among the different skin diseases one of the most common disease is dermatophytosis.<sup>1</sup> Dermatophytosis is a superficial mycotic fungal infection caused by various species of dermatophytes that have an affinity on the superficial keratinized tissues of both humans and animals.<sup>2</sup> Dermatophytes cause infections of the keratinized structures of the skin, hair and nails, called dermatophytosis.<sup>3</sup> Dermatophytes can be divided into three ecological groups: anthropophilic species which have humans as the normal host; zoophilic species which have animals as their host and geophilic species which naturally occur in the soil.<sup>4</sup> In animal dermatomycosis, the most common pathogens are *Trichophyton mentagrophytes*,<sup>5</sup> *Microsporum gypseum* and *Microsporum canis*.<sup>6</sup> *T. Mentagrophytes* is the most common dermatophytes isolated from rabbits and some researchers consider rabbits as asymptomatic carriers of this organism.<sup>7</sup> Sporadic infections with *M. Canis*, *M. Gypseum*, *M. Audouinii*, *T. Verrucosum* and *T. Schoenleinii* have been reported in rabbits. Dermatophytosis is a zoonotic disease and thus has important implications in public health.<sup>8</sup> Young or immune compromised rabbits are thought to be most susceptible.<sup>9</sup> The susceptibility of very young rabbit to dermatophytes is due to not fully developed immune system, causing a delay in adequate host immunity.<sup>10</sup> However, differences in skin secretions, especially lower levels of fungistatic fatty acids in sebum and lower levels of fungal inhibitory sphingosine, and the fast

growth and replacement of hair may also play a role in facilitating infection.<sup>10</sup> The presence of ecto-parasites, especially fleas and *Cheyletiella* mites, can also be important in the establishment and spread of dermatophytosis.<sup>10</sup> Clinically, dermatophytes infect the epidermis and adhering structures, including hair follicles and shafts. Often results in localized lesions most commonly on the face usually on or around the head, and cause pruritus, patchy alopecia, erythema, and crusting.<sup>11</sup>

This disease can also result in rabbit malnutrition, growth retardation, feed remuneration reduction and even death. Human dermatophytosis (ringworm) is often caused by the zoophilic species.<sup>12</sup> It is known that these zoonotic human dermatophytoses are usually acquired directly or indirectly by exposure to typical reservoir hosts or their immediate environment, and not by human to human transmission.<sup>13</sup> A large number of dermatophytes have been found on several animals, but three species, *M. Canis*, *T. Verrucosum* and *T. Mentagrophytes* are consistently recovered from human dermatophytosis.<sup>4</sup> Household-pets appear to be an important source of these human-zoonotic dermatophytosis, rodents or rabbits in the case of *T. Mentagrophytes*, and cats and dogs in the case of *M. Canis*.<sup>4</sup> In our country rabbits, dog, cat and guinea pigs are often purchased as a pet, and often children are involved. Dermatophytosis is a zoonotic disease so it can be transmitted to human when people come in close contact with these pets. As a result dermatophytosis have important impact on public health. *Trichophyton mentagrophytes* one common species of dermatophytes that is equally important for man and animal,

which commonly found in rabbit. Considering the above mentioned facts the present study was designed to isolate the specific types of fungus that are responsible for dermatophytosis in hospitalized rabbit as well as to find out the prevalence among the suspected cases at SAQTVH of CVASU, Bangladesh.

## Methodology

### Study area and period

The present study was conducted at SAQTVH of CVASU located in Chittagong district which is the Port City of Bangladesh. The study was conducted between February and April in 2015.

### Sample collection and preparation

Skin scraping samples were collected from the hospitalized rabbit accused with skin diseases. A total of 9 skin scraping samples (5 from males and 4 from females) were collected from the rabbit that were suspected as dermatophytosis on the basis of gross lesion on their body. Samples (hair and scrapings) were collected with forceps or scalpel just behind the extending margin in the infected area. Some samples (Hair and scrapings) were mounted for direct examination in 40% KOH and heated for 60seconds then examined under light microscope in 400 magnifications to observe fungal morphology. Rests of the samples were preserved at room temperature (25°C) in zipper bag for fungal isolation and identification.

### Culture in the agar media

Sabouraud's dextrose agar plates, containing Cycloheximide 0.02% and Depomycin 0.3% (to reduce the growth of non dermatophytic fungi) were used for fungal culture. The sample materials (Hair, skin scraping) was taken by sterile cotton bud from zipper bag and inoculated on the agar. The material was incubated at a temperature of 25°C. Each mold was sub-cultured in Sabouraud dextrose agar medium for sample maintenance.

### Identification of fungus

Grossly *T. Mentagrophytes* colonies were identified by having the colony characteristics of flat powdery to floccose or granular appearance, that are cream-colored to yellowish-buffed.<sup>14</sup> Some strains produced a lavender-tinged surface.<sup>15</sup> The colonies were frequently somewhat star-shaped and sometimes yellow or dark brown.<sup>14</sup> In microscopic examination, colonies were subjected to Lactophenol cotton-blue staining (used one drop of Lactofenol cotton blue) and these were microscopically examined. The most consistent feature of *T. Mentagrophytes* was identified as abundance of microconidia arranged in grape-like structures or alongside the hyphae. Spiral or coiled hyphae were frequently present.<sup>14</sup>

### Statistical analysis

The obtained information was imported, stored and coded accordingly using Microsoft Excel -2007 and transfer to STATA/IC-11.0 (Stata Corporation College Station) for analysis. Prevalence was determined dividing the total number of fungal infected animals by total number of animal examined and multiplied by 100 to expresses in percentage. The association between the independent factors such as age, sex, body weight, and deworming status were evaluated using the Chi-square test ( $\chi^2$ ) and considered significant when  $p < 0.05$  (Figures 1–9).

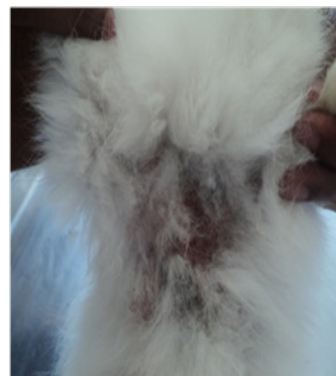

Figure 1 Alopecia in abdomen.

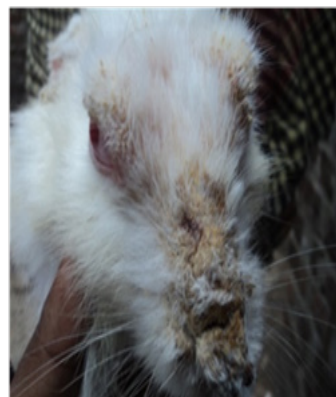

Figure 2 Alopecia in mouth.



Figure 3 Alopecia in nose.



Figure 4 Skin scraping.



Figure 5 Direct microscopic.

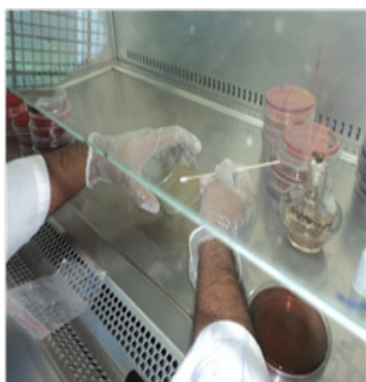

Figure 6 Fungal culture.

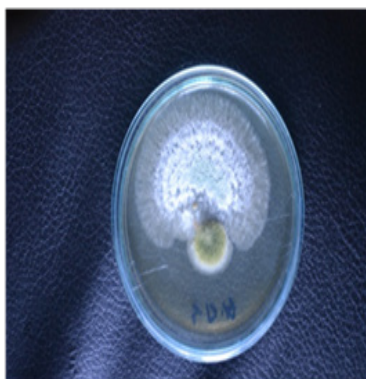

Figure 7 Fungal colony.

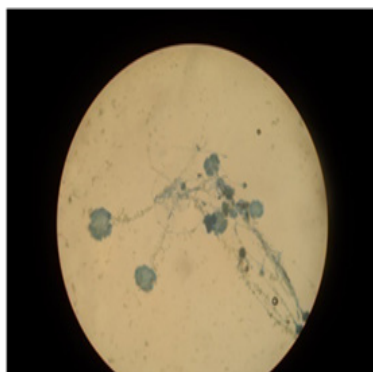


Figure 8 Microscopic structure.




Figure 9 Microscopic structure.

### Results

A total of 9 dermatophytosis suspected rabbits (5 male and 4 female) were sampled based on gross lesions and clinical signs for confirmation, among them 8 were found positive for dermatophytosis after definitive diagnosis. So the overall prevalence of dermatophytosis among the suspected cases was 88.89%. All of the cases the causative organism was *T. Mentagrophytes*.

Table 1 shows the prevalence of dermatophytosis caused by *T. Mentagrophytes* between sexes (Male and female), age groups, body weight groups and deworming statuses. The current research revealed insignificant ( $p > 0.05$ ) effect of these factors in the occurrences of dermatophytosis by *T. Mentagrophytes* in rabbit. The prevalence of dermatophytosis is higher in female (100%), age  $\geq 13-24$  (100%), body weight  $\geq 2.5$ kg (100%) and among the non-deworming rabbit (100%), with comparison to male (80%), 1-12months age (85.71%), 1-2.5kg body weight (85.71%) and vaccinated rabbits (66.67%), respectively.

Table 1 The prevalence of dermatophytosis between different sexes, age groups, body weights and deworming status caused by *T. Mentagrophytes*

Variables	Categories	No. of cases	Positive	Prevalence (%)	P-value
Sex	Male	5	4	80	0.343
	Female	4	4	100	
Age	1-12m	7	6	85.71	0.571
	$\geq 13-24$ m	2	2	100	
Body weight	1-2.5kg	7	6	85.71	0.571
	$\geq 2.5$ kg	2	2	100	
Deworming	Yes	3	2	66.67	0.134
	No	6	6	100	

### Discussion

The skin of rabbits is a window to their general state of health. Skin disorders in rabbits range from irritating to life-threatening problems. So the current study was designed to identify the most common fungal pathogen that cause dermatophytosis in rabbit. All of the identified dermatophytosis of rabbit were caused by *T. Mentagrophytes* which is supported by Manning et al.,<sup>16</sup> and they suggested *T. Mentagrophytes* is main cause of dermatophytosis in pets and rabbits. Other authors stated that rabbits were positive not only for *T. Mentagrophytes*

but also for other *Trichophyton spp.* and *Microsporum spp.*<sup>17,18</sup> In current study the prevalence of dermatophytes in rabbits those were hospitalized in SAQTVH, was higher and *T. Mentagrophytes* was isolated. Specific studies on prevalence rate of dermatophytosis in rabbits were conducted by the several researchers.<sup>19,20</sup> A number of studies showed that *T. Mentagrophytes* was the most frequent species isolated from rabbits.<sup>21–24</sup> Frequency of dermatophytes in pet rabbit in SAQTVH is similar to that of Spain, where dermatophytosis in rabbits are almost exclusively caused by *T. Mentagrophytes*.<sup>10,24</sup>

The prevalence of dermatophytosis in rabbit at Dhaka city in Bangladesh, those were hospitalized in central veterinary hospital (CVH) was 25% in male and 50% in case of female rabbits (Hossain and Kayesh, 2014). Alike the current study in earlier studies,<sup>25,26</sup> there was no sex predisposition for occurrence of dermatophytosis caused by *T. Mentagrophytes* and younger animals were more frequently affected. Some researchers<sup>19</sup> stated counter statement to the current research finding, that dermatophytosis in rabbits was more common in male rabbits. . While considering age, the output of present study have similarity with the findings of Kim SW,<sup>27</sup> they mentioned like the current findings the rabbits below 12months of age were more frequently affected with dermatophytosis than other age groups. Many other authors<sup>28</sup> suggested age as a predisposing factor for dermatophytosis of rabbit, although some authors<sup>29</sup> disagree with it.

## Conclusion

Rabbits are very prone to cutaneous form of fungal infections. The current study was undertaken to investigate the most common cause of dermatophytosis in rabbits that were hospitalized with skin infections at SAQTVH of CVASU, Bangladesh. All of the cases *T. mentagrophytes* were found as the causative organism. The most important objective of the current study was to isolate the causative organisms that are prevalent among the dermatophytotic rabbits. The prevalence rate was found higher, because the prevalence was calculated among the suspected cases. This study showed insignificant effects of age, sex, body weight and deworming status for the occurrence of dermatophytosis in rabbit. To find out the actual prevalence a comprehensive study may be conducted in future including all the rabbit population of a particular area.

## Acknowledgements

None.

## Conflict of interest

Author declares that there is no conflict of interest.

## References

- Cavalcanti JN, Guerra JL, Gambale W, et al. Histopathologic and mycologic aspects of experimental infection of guinea pigs with *Microsporum canis*. *Brazilian Journal of Veterinary Research and Animal Science*. 2002;39(5):238–243.
- Dobrowolska A, Staczk P, Kaszuba A, PCR–RFLP analysis of the dermatophytes isolated from patients in Central Poland. *J Dermatol Sci*. 2006;42(1):71–74.
- Hubálek Z, Kushwaha R, Guarro J. Keratinophilic fungi associated with free-living mammals and birds. *Biology of Dermatophytes and other Keratinophilic Fungi*. 2000. p. 93–103.
- Rochette F, Van Meirhaeghe P. Enilconazole as a Treatment of Naturally Occurring Dermatophytosis in Rabbit Farms: A Review. *World Rabbit Science*. 2010;5(1):7–11.
- Ziółkowska G, Nowakiewicz A, Gnat S, et al. Molecular identification and classification of *Trichophyton mentagrophytes* complex strains isolated from humans and selected animal species. *Mycoses*. 2015;58(3):119–126.
- Xiao CW, Ji QA, Wei Q, et al. Antifungal activity of berberine hydrochloride and palmatine hydrochloride against *Microsporum canis*-induced dermatitis in rabbits and underlying mechanism. *BMC Complement Altern Med*. 2015;15:177.
- Donnelly TM, Rush EM, Lackner PA. Ringworm in small exotic pets. *Journal of Exotic Pet Medicine*. 2000;9(2):82–93.
- Cafarchia C, Weigl S, Figueredo LA, et al. Molecular identification and phylogenesis of dermatophytes isolated from rabbit farms and rabbit farm workers. *Vet Microbiol*. 2012;154(3–4):395–402.
- Connole MD, Yamaguchi H, Elad D, et al. Natural pathogens of laboratory animals and their effects on research. *Med Mycol*. 2000;38 Suppl 1:59–65.
- Torres-Rodriguez J, Dronda M, Rossell J, et al. Incidence of dermatophytoses in rabbit farms in Catalonia, Spain, and its repercussion on human health. *European Journal of epidemiology*. 1992;8(3):326–329.
- Paré JA, Sigler L, Hunter DB, et al. Cutaneous mycoses in chameleons caused by the *Chrysosporium* anamorph of *Nannizziosis vriesii* (Apinis) Currah. *J Zoo Wildl Med*. 1997;28(4):443–453.
- Kushwaha RK, Guarro J. Biology of dermatophytes and other keratinophilic fungi. *Revista Iberoamericana de Micología*, Spain; 2000. p. 1–174.
- Cafarchia C, Camarda A, Coccioli C, et al. Epidemiology and risk factors for dermatophytoses in rabbit farms. *Med Mycol*. 2010;48(7):975–980.
- de Hoog GS, Guarro J, Gené J, et al. Atlas of clinical fungi. *Centraalbureau voor Schimmelcultures (CBS)*. 2000.
- Miller L, Hurley K. *Infectious disease management in animal shelters*. USA: John Wiley & Sons; 2011. p. 1–400.
- Manning PJ, Ringler DH, Newcomer CE. *The biology of the laboratory rabbit*. USA: Book Marketing Department, Academic Press; 1994.
- Balsari A, Bianchi C, Cocilovo A, et al. Dermatophytes in clinically healthy laboratory animals. *Lab Anim*. 1981;15(1):75–77.
- Ali-Shtayeh MS, Arda HM, Hassouna M, et al. Keratinophilic fungi on the hair of cows, donkeys, rabbits, cats, and dogs from the West Bank of Jordan. *Mycopathologia*. 1988;104(2):109–121.
- López-Martínez R, Mier T, Quirarte M. Dermatophytes isolated from laboratory animals. *Mycopathologia*. 1984;88(2–3):111–113.
- Vangeel I, Pasmans F, Vanrobaeys M, et al. Prevalence of dermatophytes in asymptomatic guinea pigs and rabbits. *Veterinary Record*. 2000;146(15):440–441.
- Hagen K, Gorham J. Dermatophytoses in fur animals: chinchilla, ferret, mink and rabbit. *Vet Med Small Anim Clin*. 1972;67(1):43–48.
- Szili M, Köhalmi I. Endemic *Trichophyton mentagrophytes* Infection of Rabbit Origin: Endemische *Trichophyton mentagrophytes*-Infektion, verursacht durch Kaninchen. *Mycoses*. 1981;24(7):412–420.
- Cutsem J, Gerven F, Geerts H, et al. Treatment with Enilconazole\* Spray of Dermatophytosis in Rabbit Farms: Behandlung von Dermatophytosen mit Enilconazol\* Spray in Kaninchenbetrieben. *Mycoses*. 1985;28(8):400–407.

24. Cabañes FJ, Abarca ML, Bragulat MR. Dermatophytes isolated from domestic animals in Barcelona, Spain. *Mycopathologia*. 1997;137(2):107–113.
25. Vermout S, Tabart J, Baldo A, et al. Pathogenesis of dermatophytosis. *Mycopathologia*. 2008;166(5–6):267–275.
26. Kraemer A, Mueller RS, Werckenthin C, et al. Dermatophytes in pet Guinea pigs and rabbits. *Vet Microbiol*. 2012;157(1–2):208–213.
27. Kim SW, Jang HC. Clinical and mycological studies of Trichophyton mentagrophytes infections from rabbits. *Korean J Med Mycol*. 1999;4(2):117–123.
28. Lewis DT, Foil CS, Hosgood G. Epidemiology and clinical features of dermatophytosis in dogs and cats at Louisiana State University: 1981–1990. *Veterinary Dermatology*. 1991;2(2):53–58.
29. Quesenberry KE, Carpenter JW. Ferrets, rabbits, and rodents. *Clinical Medicine and Surgery*. 1997.