

Analysis of base apex lead electrocardiograms of adult buffaloes

Abstract

Electrocardiographic studies were carried out in healthy adult buffaloes in Proddatur of Andhra Pradesh state in India. The electrocardiograms were recorded in standard base apex lead system. Duration and amplitude of the P, QRS complex and T wave and the PR, RR, intervals, ST segments and heart rate were measured and averaged from successive beats. Mean heart rate was 61.175 ± 0.8262 bpm. Mean amplitudes of the P, QRS and T waves were 0.186 ± 0.0042 mV, 1.168 ± 0.0181 mV and 0.336 ± 0.0095 mV. Mean duration of P, QRS and T waves were 0.0648 ± 0.0016 sec, 0.0688 ± 0.0014 sec, 0.0968 ± 0.0034 sec. In this study correlation coefficient between heart rate and Q-T intervals was negative. Present study findings will be use full for the compare the different disease conditions in buffaloes.

Keywords: Andhra Pradesh, buffaloes, ECG, India, normal values

Volume 2 Issue 6 - 2015

Sudhakara Reddy B,¹ Venkatasivakumar R,² Varaprasad Reddy LSS,³ Vani P,⁴ Sivajothi S⁵

¹Department of Veterinary Medicine, Teaching Veterinary Clinical Complex, India

²Department of Veterinary Medicine, Sri Venkateswara Veterinary University, India

³Department of Physiology, Sri Venkateswara Veterinary University, India

⁴Department of Animal Genetics and Breeding, Sri Venkateswara Veterinary University, India

⁵Department of Parasitology, Sri Venkateswara Veterinary University, India

Correspondence: Sudhakara Reddy B, Teaching Veterinary Clinical Complex, College of Veterinary Science, Sri Venkateswara Veterinary University, Proddatur-516360, Andhra Pradesh, India, Email bhavanamvet@gmail.com

Received: May 12, 2015 | **Published:** December 01, 2015

Introduction

Electrocardiography is non invasive and inexpensive technique which can be give useful information for diagnosis of arrhythmias and conduction abnormalities.¹ Electrocardiography (ECG) is considered as one of the most important parameter for an animal suffering with the cardiovascular problem. Electrocardiography also useful as prognostic indicator in large animal medicine, and it provides a record of the varying potential difference that occurs over the surface of the body as the result of electrical activity within the heart. In large animals, including large animals, a base apex lead has been shown to be an ideal lead system for monitoring cardiac arrhythmias.² Recently normal ECG study parameters in adult goats were recorded in Andhra Pradesh.³ Literature on normal values of different wave forms duration and amplitude obtained for buffaloes was scarce, and so this preliminary study was undertaken on buffaloes using the Base-Apex ECG lead system in Proddatur of Y.S.R. District in Andhra Pradesh state of India.

Materials and methods

Present study was conducted in buffaloes (28) which are maintained in well dairy farm and cases presented to the Teaching Veterinary Clinical Complex, in Y.S.R. Kadapa District of Andhra Pradesh, India. Buffaloes in this study were maintained occasional open grazing with green pasture, paddy straw and *Ad libitum* water. All the buffaloes in this study were aged between 4 to 9 years and in lactation period and were clinically examined for soundness before the recordings described by Rosenberger.⁴ Buffaloes were apparently healthy and normal at the time of study and all the vital signs were within the normal range and free from the cardiac and other systemic problems. Electrocardiographic parameters recorded in this study were on a bipolar base apex lead, using limb lead I as standard.⁵ Same procedure was adopted previously to record the normal ECG

parameters in adult sheep and goats.^{6,7} All ECGs were recorded on a three channel electrocardiographic machine (Marks electronics, Chennai) with 25mm/sec paper speed and calibrated 10mm/mV.

The right arm electrode was attached to middle of the neck (Figure 1) and the left arm electrode is placed over the apex of the heart just behind the elbow (Figure 2).⁵ The animals were kept in quiet surroundings at the time of recording. The electrodes were placed using alligator clips and a gel contact. In order to ensure good adherence to the skin, the skin was cleaned with alcohol prior to the application of the gel. The recordings were analyzed for the P wave, the QRS complex, the PR interval, the ST segment, the QT interval and the T wave. Heart rate was calculated according to the R-R interval in lead-I. All the data were analysed by using the SPSS software and expressed as mean±standard error of mean (SE) and range at confidence interval 95%. Correlation coefficient was calculated between the heart rate and QT interval.




Figure 1 Placing of right arm (RA) electrode.



Figure 2 Placing of left arm (LA) electrode.

Results and discussion

Recorded electrocardiographic parameters in this study were mentioned in the (Table 1 & Table 2). Standard ECG recordings in different age group of the buffaloes were represented in Figure 3 & Figure 4. The patterns of P wave were analyzed and found to be round, peaked and positive deflection. P wave amplitude ranged from 0.15mV to 0.25mV with a mean of 0.186±0.0042mV. Duration of P wave varied from 0.04seconds to 0.08seconds with a mean duration of 0.0648±0.0016seconds. The PR interval was ranged from 0.16seconds to 0.30seconds with an average duration of 0.2176±0.0062seconds. The QRS complex always showed negative deflection in all the animals. In this Q was occasional positive deflection with mean amplitude of 0.039±0.0031mV, R wave was always in negative deflection with mean amplitude of 1.168±0.0181mV and S wave was occasional positive deflection with mean amplitude of 0.024±0.0035mV. The duration of QRS complex ranged from 0.06 to 0.08seconds, and the mean duration was found to be 0.0688±0.0014seconds. The T wave was in positive, negative and biphasic with amplitudes varying from 0.2mV to 0.5mV and durations of 0.06seconds to 0.16seconds. The mean amplitude and duration of the T wave were 0.336±0.0095mV and 0.0968±0.0034seconds, respectively. The ST segment was from 0.16seconds to 0.24seconds with an average duration of 0.1904±0.0035seconds. The Q-T interval ranged from 0.36seconds to 0.48seconds with an average duration of 0.4086±0.0042seconds. Correlation coefficient between the heart rate and QT interval was negative (-0.082) in this study. This explains about the relation between the heart rate and QT interval in individual buffalo.

Table 1 Amplitude in mill volts of the lead-I of electrocardiography in adult buffaloes (Mean±S.E.)

	Adult buffaloes (Mean±S.E.)	Range
P	0.186±0.0042	0.15 to 0.25
Q	0.039±0.0031	0.00 to 0.05
R	1.168±0.0181	0.90 to 0.14
S	0.024±0.0035	0.00 to 0.05
T	0.336±0.0095	0.20 to 0.50

Table 2 Duration in seconds of the lead-I of electrocardiography in adult buffaloes (Mean±S.E.)

	Adult buffaloes (Mean±S.E.)	Range
P	0.0648±0.0016	0.04 to 0.08
QRS	0.0688±0.0014	0.06 to 0.08
T	0.0968±0.0034	0.06 to 0.16
P-R interval	0.2176±0.0062	0.16 to 0.30
Q-T interval	0.4086±0.0042	0.36 to 0.48
R-R interval	0.9683±0.0135	0.80 to 1.12
S-T segment	0.1904±0.0035	0.16 to 0.24
Heart rate	61.175±0.8262	53.0 to 75.0

Electrocardiogram measures the changes in the electrical activity of the heart during each cardiac cycle. Different ECG waveforms are useful in regular clinical practice in the veterinary medicine. Deflections in the ECG waveform represent the change in electrical activity caused by atrial or ventricular depolarization and repolarization.⁸ Animals with heat block can be diagnosed by the determination of the PR interval. Cases with first degree heart block had the elongated PR interval. In ECG, P wave without a subsequent QRS complex before the next P wave indicates second-degree heart block. An ECG trace with P waves and QRS complexes beating independently of each other indicates the cessation of atrioventricular node which indicates third-degree heart block.⁹ Irregular opening or closing of sodium or potassium channels in the heart causes prolonged QT interval which indicates the delayed repolarization of the cardiomyocytes.⁵

Cardiac dysrhythmias in clinically healthy animals as well as animals with various organ problems, particularly gastrointestinal problems have been reported.¹⁰ The values obtained in this study were well within the normal range as indicated by earlier workers.^{4,11} Severe cardiovascular disease is relatively uncommon, it is important that the clinician examines this system with care during the routine clinical examination of the bovine patient. Early detection of cardiovascular disease might enable appropriate remedial action to be taken and an accurate prognosis of the patient's condition to be offered.¹² Variations in the T wave use full for the potassium levels in the serum and also use full for the response to the treatment.

The electrocardiogram is a non invasive test that is used to detect underlying heart conditions by measuring the electrical activity of the heart. Electrocardiography is a very important tool to diagnose cardiac diseases in large animal practice which includes diseases involving the thoracic as well as peritoneal cavity like pericarditis, traumatic reticulo peritonitis.^{13,14} Different waveforms in ECG useful in parasitic diseases like theileriosis, trypanosomosis, and microfilariosis in buffaloes.¹⁵⁻¹⁷ ECG also useful to detect the cardiac arrhythmias and chamber enlargements in young as well as adult buffaloes.¹⁸ The ECG is a static picture and may not reflect severe underlying heart problems at a time when the patient is not having any symptoms. Other tests that may be alternatives to an ECG or may be used in conjunction with an ECG include an echocardiogram. ECG itself is not useful to detect early stages of cardiac diseases except for arrhythmias. Echocardiogram is more classical tool for the investigation of the preclinical form s of cardiomyopathies in buffaloes. But, availability

of the echocardiogram (costly equipment) is not possible in all the veterinary institutions in developing countries like in India. By this study, we standardised the procedure and normal healthy adult buffalo

values were recorded. Data recorded in this study is useful as reference values for clinical evaluation of diseased buffaloes.

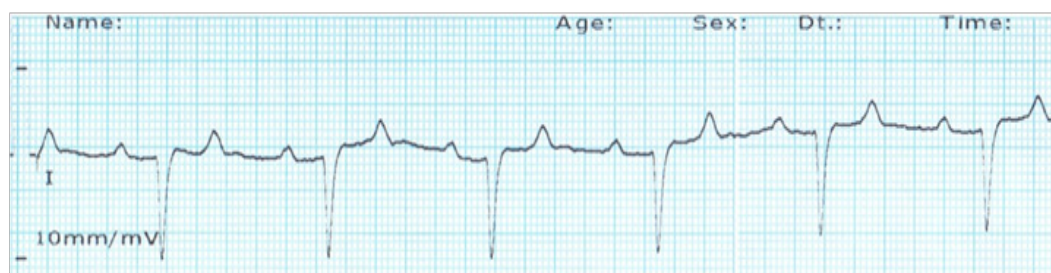

Figure 3 The electrocardiogram of healthy adult buffalo (Age-8years) in base apex leads system (paper speed 25mm/sec, calibrated 10mm/mV).

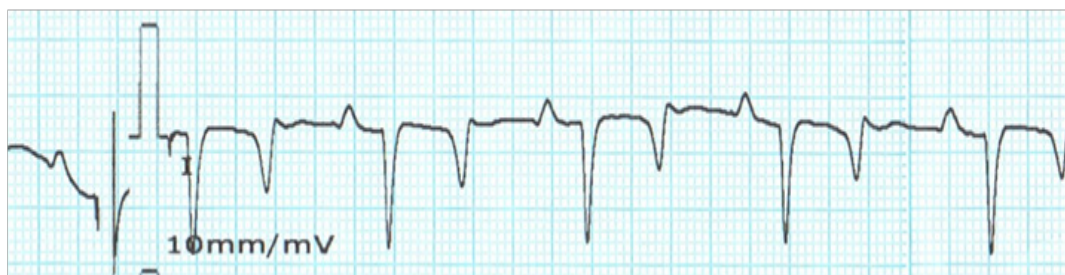

Figure 4 The electrocardiogram of healthy adult buffalo (Age-6years) in base apex leads system (paper speed 25mm/sec, calibrated 10mm/mV).

Conclusion

In the present study, provides the normal ECG findings in apparently healthy adult buffaloes in Andhra Pradesh state of India.

Author's contribution and competing interests

All authors had equally contributed to complete the work based on the need. Authors declare that they have no competing interests.

Acknowledgements

Corresponding author expressed thanks to the Mr. S. Sadasiva Reddy for his co operation during the study period. All the authors are thankful to Sri Venkateswara Veterinary University for providing facilities to carry out this work.

Conflict of interest

Author declares that there is no conflict of interest.

References

- Mendes LCN, Camacho AA, Alves ALG, et al. Standard electrocardiographic values in Holstein calves. *Arq Bras Med Vet Zootec.* 2001;53(6):641–644.
- Rezakhani R, Paphan AA, Shekarfroush S. An analysis of base apex lead electrocardiograms of normal dairy cows. *Vetrinarski Archv.* 2004;74(5):351–358.
- Reddy BS, Reddy LSSV, Raju KGS, et al. Electrocardiographic Studies in Adult Osmanabadi Goats. *Photon. The Journal of Veterinary Science.* 2014;115(2014):333–337.
- Rosenberger G. *Clinical Examination of Cattle.* 2nd ed. Berlin and Hamburg, Verlag Paul parey; 1979.
- Radostits OM, Gay CC, Hinchcliff KW, et al. *Veterinary Medicine, A text book of the diseases of cattle, horses, sheep, pigs and goats.* 10th ed. USA: WB Saunders Co; 2009.
- Reddy BS, Reddy BS, Raju KGS, et al. Electrocardiographic Studies in Adult Sheep. *The Indian Journal of Veterinary Science.* 2013;1(2):43–47.
- Reddy BS, Venkatasivakumar R, Sivajothi S, et al. Electrocardiographic abnormalities in young healthy sheep and goats. *International Journal of Biological Research.* 2014;2(1):21–22.
- Johnson LR. *Essential Medical Physiology.* 3rd ed. San Diego: Elsevier Academic Press; 2003.
- Mohrman DE, Heller LJ. *Cardiovascular Physiology.* 5th ed. New York: McGraw-Hill; 2003.
- Machida N, Nakamura T, Kiryu K, et al. Electrocardiographic features and incidence of atrial fibrillation in apparently healthy dairy cows. *Zentralbl Veterinarmed A.* 1993;40(3):233–239.
- Jackson P, Cockroft P. *Clinical Examination of Farm Animals.* USA: Blackwell Publishing; 2002.
- Jackson P, Slater J. Cardiovascular disease in cattle. *In Practice.* 1997;19:472–483.
- Reddy LSSVP, BS Reddy, BR Naik, et al. Haematological and clinical alterations with traumatic reticuloperitonitis in cattle. *Inter J Vet Sci.* 2014;3(4):203–205.
- Reddy BSS, Reddy BS, Manasa V. Acute diffuse peritonitis in a pregnant buffalo. *International Journal of Animal Biotechnology & Applications.* 2015;1(1):1–4.
- Sivajothi S, Reddy BS. Brisket oedema due to microfilariosis in a buffalo. *Res Rev: J Vet Sci Technol.* 2014;3(3):17–19.
- Sivajothi S, Reddy BS, Kumari KN, et al. Haematological changes in *Trypanosoma evansi* infected cattle. *International Journal of Scientific World.* 2014;2(1):27–30.

17. Mashhadi AG, Hajikolai RH, Rezakhani A, et al. The prevalence of cardiac arrhythmia in Khuzestan buffaloes (*Bubalus bubalis*), *Revue Med Vet*. 2014;165(3-4): 99-103.
18. Hasanpour A, Moghaddam GA, Nematollahi A. Biochemical, hematological, and electrocardiographic changes in buffaloes naturally infected with *Theileria annulata*. *Korean J Parasitol*. 2008;46(4):223-227.