

A case report of a facial skin lesion of dental origin

Abstract

Chronic inflammation due to periapical abscess can drain into the mouth or outside of the skin through sinus tract. In this last, it may be difficult to differentiate the opening of the fistula from primary skin conditions by the general physician who wrongly refers patients to dermatology, being a main issue of dentist.

Keywords: cutaneous fistula, periapical abscess, skin carcinoma, sinus tract, differential diagnoses, endodontic treatment

Volume 8 Issue 8 - 2017

Natalia De La Calle,¹ Luisa Gomez¹

¹Department of Dermatology, CES University, Colombia

²General Physician, CES University, Colombia

Correspondence: Natalia De la calle, Department of Dermatology, CES University, street 35 N°64a-55, Medellín, Antioquia, Colombia, Email natalitacalle@hotmail.com

Received: December 05, 2017 | **Published:** December 20, 2017

Introduction

Periapical abscess may be due to cavities or trauma are a highly common cause of intraoral fistulas, and in a less frequent occurrence extraoral fistula, which drain directly onto the skin.^{1,2} This last is rare, but easily misdiagnosed due to the amount of differential diagnoses which may be mistaken, for so patients could undergo unnecessary antibiotic therapy, allowing the infection to be chronic.^{3,4} Fortunately, life threatening complications such as osteomyelitis and sepsis are not very common.^{5,6} Whenever a patient has a facial or cervical fistula, it is mandatory a complete oral exploration looking for an odontogenic abscess besides a fibrous tissue (fistula) on the mandibular angles, cheeks or chin that connects jugal with gingival mucosa, causing the skin retraction.⁷⁻⁹ It is necessary to be corroborated the periapical infection with a panoramic x ray, or it may be done by drawing the sinuous tract con radiopaque material such as gutta percha, and then takes the x-ray.¹⁰⁻¹² Therapy consists of treating the underlying infection, which may be with endodontic treatment in teeth, which can be saved, or if the piece is completely useless, it is best to remove, along with its fistulous tract.¹⁻⁴ This article describes the case of a patient who was wrongly referred to dermatology for surgical resection of a probably basocellular carcinoma on the cheek, based on the presence of retraction in the skin and lack of oral symptoms. This manuscript should help guide the general physician to understand that cutaneous lesion could be the consequence of dental pathology, and this way make the right derivation for odontological treatment.¹²

Case report

79year old male, born and raised in Antioquia, with a personal history of prostate carcinoma and undergoing oncological treatment with leuprolide acetate, whom was referred to a dermatology department for a biopsy of a lesion on his right cheek, thought being malign. During anamnesis the patient described a lesion on the right cheek approximately the last 3years, completely asymptomatic and had no relation to any other personal medical history. Also, he said he was partially toothless. In the physical examination, it was noticed a facial orifice on the cheek with a retraction of the surrounding skin (Figure 1). An oral exploration once the patient took of the dental prostheses revealed one original right canine and a right premolar, also present it could be seen a fibrous tract that coincided with the retracted skin lesion and connected the right jugal with the gingival mucosa at the level of the inferior premolar. There was cavities and

abfraction of the same exact dental piece, nerve root being completely exposed (Figure 2). Based on these findings, the patient was referred to stomatology to have the fistula treated. Panoramic x-ray identified periapical radiolucency in tooth number 44 and fillings in pieces 43 and 44 (Figure 3). The patient is now waiting endodontic treatment.

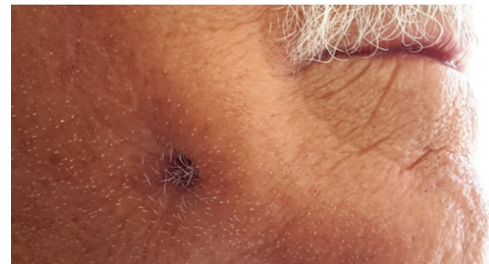

Figure 1 Cutaneous hole on the right cheek with retraction of the surrounding skin.

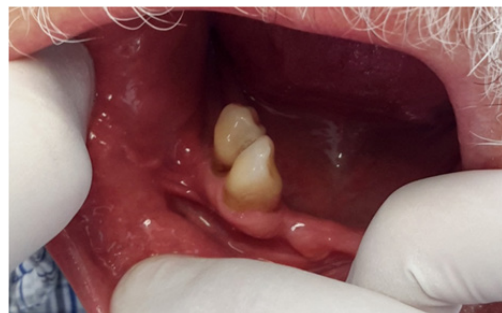

Figure 2 Fibrous tracts connecting jugal with gingival mucosa at premolar level, which has abfraction and cavities.

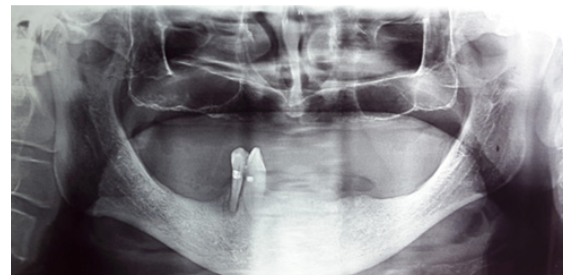


Figure 3 Periapical radiolucency in dental piece 44.

Discussion

Cutaneous dental fistulas are not a common dermatological subject, being the reason why is misdiagnosed by dermatologist and surgeons. A study published by Miri et al.¹³ which was realized in Iran in 1,527 patients with a personal history of endodontic treatment, it was found a frequency of a sinus tract of 9.9% in contrast with another study reported by Sadeghi et al.¹⁴ in 2011 in a very similar population with the same procedence and under canalicular therapy, in 728 patients it was set a prevalence of 14.7%.^{13,14} submitting the patient to unnecessary antibiotic treatments, biopsies, resections, and even radiotherapy, with a not so favorable outcome and a recurrence of the fistula.¹⁻³ Patients with or cutaneous fistulas it has been thought that odontocutaneous fistulas are more frequent in children and adolescents, due to the fact that the alveolar processes are not fully developed, although, it has been seen in patients older than 20years of age.⁹ The average of the patient age varies: Sadeghi et al.¹⁴ reported an age range of 10-69years; in the Guevara et al.¹⁵ study the mean was 45years with a higher presentation of sinus tracts in patients older than 51 years. In the Slutzky et al.¹⁶ the mean was 32.2 years.^{14,15} According to gender, the presence of odontocutaneous fistulas can vary: Guevara et al.¹⁵ found 53% of women with this condition and Miri et al.¹³ in a 9.1% and Huang et al.¹⁷ in 45.3% of women, meanwhile; Sadeghi et al.¹⁴ did not find significant differences between men and woman.¹³⁻¹⁷ Initially, cavities due to microorganisms such as *Fusobacterium nucleatum sp. Vicentii*, *orphyromonas gingivalis* *Veillonella parvula*, *Enterococcus faecalis*, *Campylobacter gracellis* and *Neisseria mucosa* invade the tooth through the enamel and dentin, infecting the pulp causing necrosis, periodontitis and formation of the periapical abscess, rich in anaerobic bacteria. Usually this process is acute and renders the patient to seek medical attention.⁴⁻¹⁸

With the passing of time between six months and 30years, added to the partial and temporal recovery, symptoms may be masked meanwhile the infectious process continues and intensifies, becoming chronic. At this point, the purulent material finds a way out through an abnormal canal that connects the alveolar abscess with an orifice in the interior of the mouth (intraoral sinus tract), or into the skin (extraoral sinus tract).⁶⁻²¹ Based on a recent report, extraoral fistulas are more common in women and adults and intraoral fistulas are usually found in children.¹⁶ The draining pathway depends on the length of the root and the exposition of the apex, in relation to the muscle union to the bone: if the infection goes underneath the buccinator muscle in the maxillary area or if the infection passes on top of the mentionian muscle, mylohyoideus or buccinators in the mandible, the most probably, the result is an intraoral fistula.¹²⁻²² If on the contrary, there is perforation of the cortical on top of the muscular union in the maxillary and underneath the mandible, the tract is an extraoral odontocutanous fistula. The purulent material tries to find a way out through a place that presents less resistance, in order to relieve the pain and the edema, the purulent material does this by passing through the periodontal ligament, bone and soft tissue right into the epidermis, creating abscess o cellulites of the skin, which leads to a hole in the skin.^{9,23} Besides cavities being the most common cause of periapical infection, there can be other causes such as trauma, root retentions, odontogenic cysts or chronic mandibular infections that lead to odontocutaneous fistulas.²⁴ Clinically, there can be a soft nodule on the skin, symmetric, erythematous, or covered with scab tissue, the skin can be retracted because of a fibrous tissue that joins

the jugal mucosa with the gingival tissue, which if it is palpated may produce the exit of purulent material. In other cases it may manifest with abscess, cysts, ulcers, or scars. Only 50% of the patients feel pain or dental sensitivity, but there may be evident drainage which can produce esthetic problems.¹⁹ The most common fistulas are associated with mandibular teeth in 80 to 87% of the cases, in a proportion of 4:1 between mandibular and maxillary unions and more common in anterior dental pieces like canine or incisor than posterior teeth.^{2,18} In other rare occasions it has been documented otherwise.^{1,15} Topically, they are localized in the angles of the mandible, chin and cheeks, and most of the times it can be predicted where the fistula will drain, depending on what tooth is affected: the mandibular premolars and molars will drain into the submandibular regions by some into the cheek of the affected side as well. Meanwhile the same pieces, but on the maxillary region will drain directly into the cheek.^{7,20} The maxillary incisors will most likely drain into the base of the nose and the canine into the internal part of the eye. There are less cases with drainage sites located distant to the affected area such as chest, muscles and sacral region.^{10,28} The diagnosis of a fistula requires suspicion, a well done medical history and an adequate physical and oral examination and sensitivity test. Past inflammatory process and dental work should be asked about. A panoramic and a periapical x-ray may show some radiolucent areas, traces with gutta percha on the sinus tract (radiopaque material put into the fistula and then take the x-ray). If there is purulent material it is best to take samples for cultures, in 60% of the cases it may be caused by anaerobic bacteria.⁸⁻²² Ultrasonography and CAT scans may be useful, but not necessary for diagnostics. If the biopsy material was sent to the lab the findings would be granulomatous tissue, pseudoepitheliomatous hyperplasia and chronic inflammation.²³⁻²⁶ Usually it can misguide the diagnostics, as there are other entities that can generate fistulas, pyogenic granuloma, salivary gland fistulas, congenital fistulas, infected cysts, deep mycosis infections, actinomycosis, thyroid cyst, pustules, furuncles, reactions to foreign bodies, skin carcinomas such as basal cell and squamous cancer, inverted follicular keratosis, dacryocystitis, suppurative lymphadenitis, tertiary syphilis and tuberculosis.^{27,28} Rarely periapical abscess and fistulas generate complications, as mentioned before, osteomyelitis and sepsis.⁶ Treatment consists of the elimination of the infectious agent through endodontic work if the piece can be recovered, in 12.7% of cases.²¹ If it cannot, it is best to remove it and complete resection of the fistula as well. There should be administration of systemic antibiotics if the patient is diabetic, immunosuppressed or has signs of systemic infection.²⁶⁻²⁹ Once the infection is treated the sinus tract will heal in 5-14days and closes by secondary intention, but the esthetic results are not so favorable; patients present scaring and depressions of the skin, which is why it is always recommended surgical removal of the fistula.⁹

Conclusion

It is very important to have a clear understanding and suspicion, as well as a very detailed medical history and an oral and physical exam, no matter whose patient it is. An initial dental work-up would have avoided this patient unnecessary dermatology visit and instead he could be directly referred to stomatology.

Funding

None.

Acknowledgments

None.

Conflicts of interest

All authors declare no conflict of interest.

Patient consent form

Patient agreed with his case report and came back to dermatology to provide stomatology's clinic register and x-ray studies.

References

- Tian J, Liang G, Qi W, et al. Odontogenic cutaneous sinus tract associated with a mandibular second molar having a rare distolingual root: a case report. *Head Face Med*. 2015;11:13.
- Sato T, Suenaga H, Igarashi M, et al. Rare case of external dental fistula of the submental region misdiagnosed as inverted follicular keratosis and thyroglossal duct cyst. *Int J Surg Case Rep*. 2015;16:39–43.
- Gupta M, Das D, Kapur R, et al. A clinical predicament—diagnosis and differential diagnosis of cutaneous facial sinus tracts of dental origin: a series of case reports. *Oral Surg Oral Med Oral Pathol Oral Radiol Endod*. 2011;112(6):e132–e136.
- Sisodia N, Manjunath M. Chronic cutaneous draining sinus of dental origin. *Ann Med Health Sci Res*. 2014;4(6):962–964.
- Brown RS, Jones R, Feimster T, et al. Cutaneous sinus tracts (or emerging sinus tracts) of odontogenic origin: a report of 3 cases. *Clin Cosmet Investig Dent*. 2010;2:63–67.
- Yeoh SC, MacMahon S, Schifter M. Chronic suppurative osteomyelitis of the mandible: case report. *Aust Dent J*. 2015;50(3):200–203.
- Abuabara A, Schramm CA, Zielak JC, et al. Dental infection simulating skin lesion. *An Bras Dermatol*. 2012;87(4):619–621.
- Nikkhah D, Gilbert P. Comment re: Odontogenic skin sinus: a commonly overlooked skin presentation. *J Plast Reconstr Aesthetic Surg JPRAS*. 2013;66(4):e124.
- Sammut S, Malden N, Lopes V. Facial cutaneous sinuses of dental origin—a diagnostic challenge. *Br Dent J*. 2013;215(11):555–558.
- Peermohamed S, Barber D, Kurwa H. Diagnostic challenges of cutaneous draining sinus tracts of odontogenic origin: a case report. *Dermatol Surg*. 2011;37(10):1525–1527.
- Samir N, Al-Mahrezi A, Al-Sudairy S. Odontogenic Cutaneous Fistula: Report of two cases. *Sultan Qaboos Univ Med J*. 2011;11(1):115–118.
- Gupta SK, Saxena P. Cutaneous manifestation of odontogenic infection misdiagnosed as having dermatologic etiology: a report of two cases. *Quintessence Int*. 2011;42(6):455–458.
- Miri SS, Atashbar O, Atashbar F. Prevalence of Sinus Tract in the Patients Visiting Department of Endodontics, Kermanshah School of Dentistry. *Glob J Health Sci*. 2015;7(6):271–275.
- Sadeghi S, Dibaei M. Prevalence of odontogenic sinus tracts in 728 endodontically treated teeth. *Med Oral Patol Oral Cir Bucal*. 2011;16(2):e296–299.
- Guevara-Gutiérrez E, Riera-Leal L, Gómez-Martínez M, et al. Odontogenic cutaneous fistulas: clinical and epidemiologic characteristics of 75 cases. *Int J Dermatol*. 2015;54(1):50–55.
- Slutzky-Goldberg I, Tsesis I, Slutzky H, et al. Odontogenic sinus tracts: a cohort study. *Quintessence Int Berl Ger*. 2009;40(1):13–18.
- Huang TJ, Roan RT, Lin HT. Sinus tracts of dental origin. A clinical study. Part I. *Gaoxiong Yi Xue Ke Xue Za Zhi*. 2009;6(12):653–660.
- Sheehan DJ, Potter BJ, Davis LS. Cutaneous draining sinus tract of odontogenic origin: unusual presentation of a challenging diagnosis. *South Med J*. 2005;98(2):250–252.
- Cantatore JL, Klein PA, Lieblich LM. Cutaneous dental sinus tract, a common misdiagnosis: a case report and review of the literature. *Cutis*. 2002;70(5):264–267.
- Spear KL, Sheridan PJ, Perry HO. Sinus tracts to the chin and jaw of dental origin. *J Am Acad Dermatol*. 1983;8(4):486–492.
- Johnson BR, Remeikis NA, Van Cura JE. Diagnosis and treatment of cutaneous facial sinus tracts of dental origin. *J Am Dent Assoc*. 1999;130(6):832–836.
- Held JL, Yunakov MJ, Barber RJ, et al. Cutaneous sinus of dental origin: a diagnosis requiring clinical and radiologic correlation. *Cutis*. 1989;43(1):22–24.
- Shobatake C, Miyagawa F, Fukumoto T, et al. Usefulness of ultrasonography for rapidly diagnosing cutaneous sinus tracts of dental origin. *Eur J Dermatol EJD*. 2014;24(6):683–687.
- Giménez-García R, Martínez-Vera F, Fuentes-Vera L. Cutaneous Sinus Tracts of Odontogenic Origin: Two Case Reports. *J Am Board Fam Med JABFM*. 2015;28(6):838–840.
- Bai J, Ji AP, Huang MW. Submental cutaneous sinus tract of mandibular second molar origin. *Int Endod J*. 2014;47(12):1185–1191.
- Pasternak-Júnior B, Teixeira CS, Silva-Sousa YTC, et al. Diagnosis and treatment of odontogenic cutaneous sinus tracts of endodontic origin: three case studies. *Int Endod J*. 2009;42(3):271–276.
- Yadav S, Malik S, Mittal HC, et al. Odontogenic cutaneous draining sinus. *J Craniofac Surg*. 2014;25(1):e86–e88.
- Cohen PR, Eliezri YD. Cutaneous odontogenic sinus simulating a basal cell carcinoma: case report and literature review. *Plast Reconstr Surg*. 1990;86(1):123–137.
- Cioffi GA, Terezhalmay GT, Parlette HL. Cutaneous draining sinus tract: an odontogenic etiology. *J Am Acad Dermatol*. 1986;14(1):94–100.