

# Clinical management of multiple traumatic dental injuries and treatment approaches: 30 months' follow-up

## Abstract

Trauma to the permanent dentition is common in children and adolescents. Almost two-third of these traumas involve a single anterior tooth. However, multiple dental injuries are often seen in high-velocity accident or sport related fall. These injuries can bring about serious damage to the tooth supporting structures and subsequent complications if inadequately treated. The present case highlights the management of multiple dental injuries that includes avulsion, intrusive luxation and alveolar fracture in a young adolescent including 30 months' follow-up. The holistically planned treatment approaches allowed restoration of patient's dental function and aesthetics with very minimal complications. Furthermore, it also brought about a positive impact on the psychological wellbeing of the patient.

**Keywords:** avulsion, intrusive luxation, subluxation, dental complications

Volume 7 Issue 3 - 2017

Nurulnazra Mohd Areffin, Ahmad Shuhud Irfani Zakaria, Alida Mahyuddin, S Nagarajan MP

Department of Operative Dentistry, The National University of Malaysia, Malaysia

**Correspondence:** Nagarajan MP Sockalingam S, Department of Operative Dentistry, The National University of Malaysia (UKM), Jalan Raja Muda Abdul Aziz, 50300. Kuala Lumpur, Malaysia, Email drnaga67@gmail.com

**Received:** May 10, 2017 | **Published:** May 30, 2017

**Abbreviations:** A&E, accident and emergency; EPT, electric pulp testing; GIC, glass ionomer cement; RCT, root canal treatment.

## Introduction

Traumatic dental injuries are a major threat to children and adolescents, often involving the upper anterior teeth.<sup>1,2</sup> Dental traumas can be divided into nine different types of fractures and six luxation injuries. However, the combination of several different trauma types can occur and may complicate the management of such cases.<sup>3</sup> Each set of these combinations has its own specific treatment demands and prognoses with regards to pulpal and periodontal healing.<sup>4</sup> The current case highlights the complexity of the trauma that can occur and how prioritization of treatment allows favorable outcomes, hence, enhancing the patient's quality of life.

## Case presentation

A 14-year-old girl was reported to the Accident and Emergency (A&E) Department of a University Hospital in the city of Kuala Lumpur following a motor-vehicle accident. The patient was conscious at the time of presentation without any history of loss of consciousness, headache or vomiting. She sustained multiple injuries to her upper front teeth. Two of her upper permanent teeth were out of their sockets but only one was retrievable from the site of accident. The tooth was kept in a dry tissue paper. No other injury to her body was observed and her medical history was unremarkable. She presented at the A&E four hours following the accident. The extra-oral examination did not reveal any remarkable findings except that both her lips were swollen. Intra-oral examination showed sockets devoid of maxillary left permanent central and lateral incisors (tooth 21 and tooth 22). The labial alveolar plate at the site of tooth 21 and 22 was slightly mobile with intact overlying mucosa. The maxillary right permanent central incisor (tooth 11) was intruded and displaced

buccally without any mobility. The maxillary right permanent lateral incisor (tooth 12) had grade I mobility and tender to touch. There was bleeding from the gingivae around the injured teeth due to lacerations (Figure 1). Other teeth in the dentitions were intact without any occlusal derangement. Posteroanterior (PA) skull radiograph was taken at the A&E Department, showing a hazy appearance of teeth sockets devoid of both tooth 21 and 22 and the intruded tooth 12 due to superimposition of other structures. Examination of the avulsed tooth brought by the patient showed an anatomical resemblance of a maxillary left permanent incisor (tooth 21). The root surface of tooth 21 appeared to be dry and contaminated with some road grits. The tooth was held by its crown and the root surface was washed with a gentle stream of isotonic saline. The root was further scraped carefully using a sterile No. 11 scalpel blade to remove the necrotic periodontal ligament and grits. Thereafter the tooth was placed into a container that contained 0.2% Chlorhexidine solution. Subsequently, the traumatized area was anesthetized and the sockets of the avulsed teeth were carefully irrigated using normal saline to remove the blood clot. This was then followed by surgical repositioning of the intruded tooth 11 to its anatomical position using extraction forceps. Subsequently, the avulsed tooth 21 was replanted back to its proper orientation in its socket. A flexible wire splint using a 0.5 mm of a stainless steel wire and composite was placed from the maxillary right permanent canine (tooth 13) to its contralateral counterpart (tooth 23) to secure the traumatized teeth in their position (Figure 2). Occlusion was checked to ascertain that there was no heavy bite to the traumatized teeth. Soft tissue lacerations were again cleaned with 0.2% chlorhexidine and sutured with a 4 'O' resorbable polyglactin suture. Following that, pulp sensibility tests were carried out with no response recorded of tooth 11 and 21. A periapical radiograph was taken to verify the location of the repositioned and replanted teeth in their sockets (Figure 3). Since both the tooth 11 and 21 had matured apices, a follow-up appointment was arranged after 10 days for pulp extirpation. The patient was discharged home with Amoxicillin and Paracetamol prescribed. She was advised of the need for meticulous

oral hygiene care. A mouthwash of 0.2% chlorhexidine was also prescribed to be used twice daily. She was also advised to consume a soft diet and avoid undue pressure on the traumatized teeth. At the review appointment 10 days' post-trauma, pulp extirpation was carried out on both tooth 11 and 21 prior to splint removal. The canals were chemo-mechanically cleansed with sodium hypochlorite after working length estimations. Later the canals were filled with the non-setting calcium hydroxide and the pulp chambers were double sealed using the reinforced zinc-oxide eugenol and glass ionomer cement (GIC). During the follow-up appointment at four weeks' post-trauma, the traumatized teeth did not exhibit any mobility and had no evidence of pathology clinically (Figure 4). However, a periapical radiograph taken showed loss of lamina dura at the distal aspect of the root of tooth 21 and marginal bone loss between tooth 11 and 21. Additionally, there was also a widening of the lamina dura noted at the apical region of tooth 12 (Figure 5). Pulp sensibility tests of tooth 12 revealed a delayed Electric Pulp Test (EPT) response. At this juncture, root canal treatment (RCT) of tooth 12 was initiated. The canal was debrided and cleaned chemo-mechanically prior to placement of intra-canal medication of non-setting calcium hydroxide. Also during this visit, alginate impressions of the upper and lower arches were taken for a partial denture construction to replace the missing tooth 22. Patient was provided with an acrylic partial denture a week later (Figure 6). At another follow-up appointment four months' post trauma, all the affected teeth were clinically sound with no further deterioration of their condition seen radiographically. However, both tooth 11 and 21 had a loss of lamina dura around their roots (Figure 7) and produced a high metallic sound upon percussion, suggestive of replacement resorption. Based on these findings, the root canals of tooth 11, 21 and 12 were obturated with gutta-percha during this visit. At six months' post root canal treatment completion follow-up, the periapical radiolucency of tooth 12 had completely resolved radiographically. There was also no further progression of the root resorption on the tooth 11 and 21 (Figure 8), and similar findings were also found at one and two years' follow-ups (Figure 9 & 10). A resin bonded bridge was constructed to replace the partial denture for the missing tooth 22 (Figure 11). Clinically, the patient had been asymptomatic with no mobility of any of the injured teeth since the splint was removed. The resin bonded bridge was intact and in good function. The patient was very happy with treatment outcome and is currently placed on periodic follow-ups.

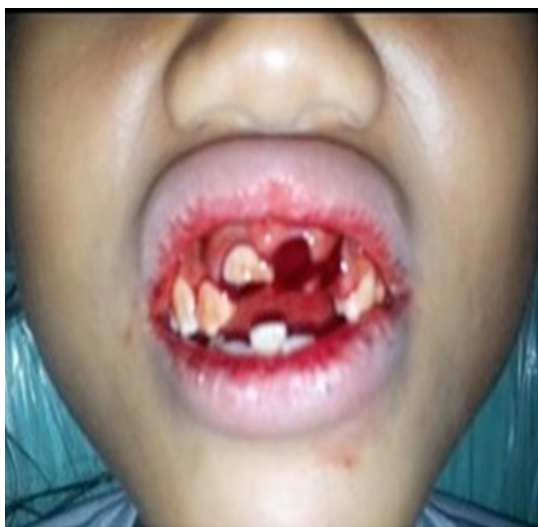

Figure 1 Pre-treatment multiple dental injuries sustained.

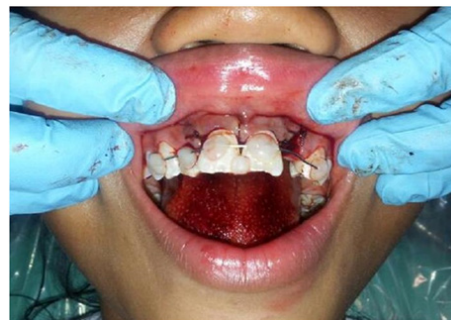

Figure 2 Immediately after replantation of tooth 21 and surgical repositioning of tooth 11 and stabilization with acid-etch composite wire splint.

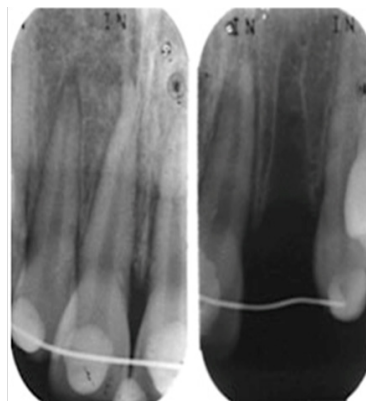


Figure 3 Radiograph post-splinting to verify position of tooth 11 and 21.

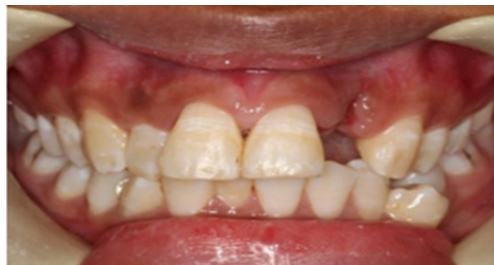

Figure 4 One-month post-trauma view.

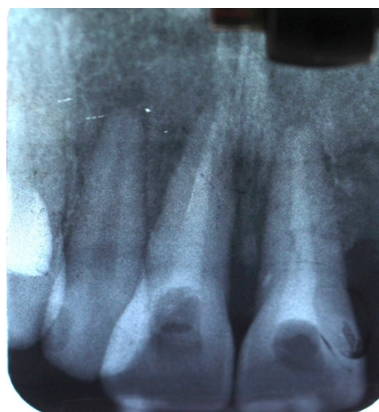

Figure 5 One-month follow-up radiograph.

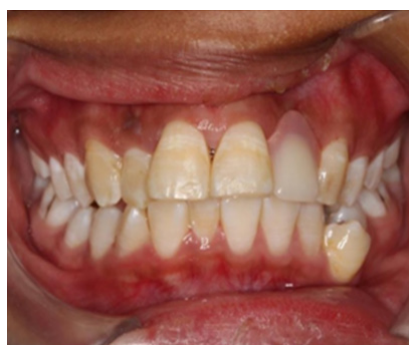

Figure 6 Replacement of missing tooth 22 with removable acrylic denture.

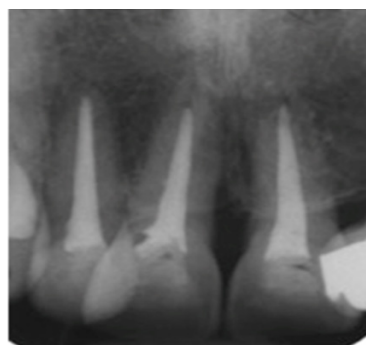

Figure 10 Two-year follow-up radiograph.

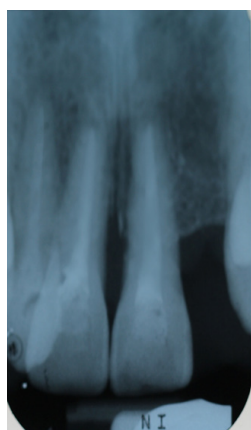


Figure 7 Pre-obturation radiograph of the tooth 12, 11 and 21 four-month post-trauma.

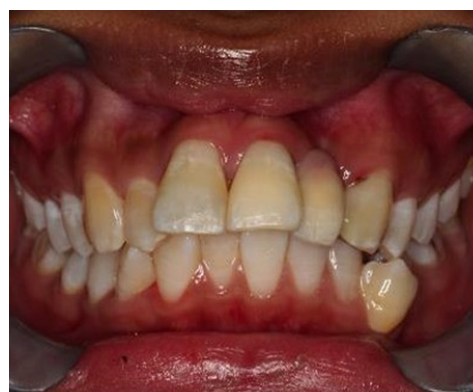

Figure 11 Replacement of the missing tooth 22 with acid etch bridge.

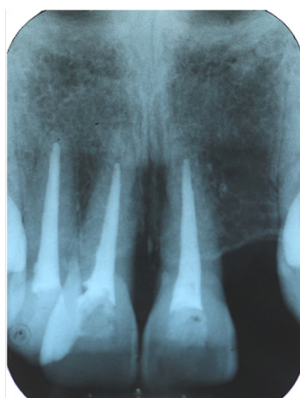


Figure 8 Six-month post root canal treatment completion.

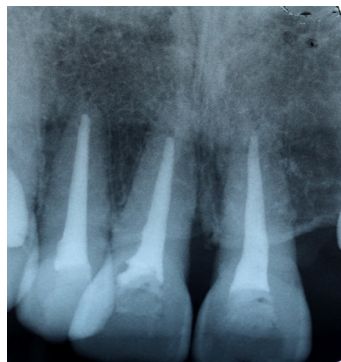


Figure 9 One-year follow-up radiograph.

## Discussion

Maxillary incisors are the most commonly traumatized teeth and usually single injury type is the commonest type seen following dental trauma.<sup>5</sup> However, in the current case, there was multiple dental trauma involving avulsion, intrusive luxation and subluxation of maxillary incisors, with a concurrent injury of the gingival tissue. Immediate treatment is imperative because it can significantly affect the outcomes especially with regards to intrusive luxation and avulsion. Delay in providing treatment at the earliest possible time can lead to complications such as apical periodontitis, breakdown of marginal bone, external inflammatory resorption or replacement resorption.<sup>6,7</sup> Two important principles in managing dental trauma to ensure favorable outcomes include early repositioning and splinting of the traumatized teeth and prevention of infection. Early repositioning and stabilization have been shown to promote the best periodontal repair.<sup>8,9</sup> A splinting technique that allows physiologic movement of teeth may optimize the healing of pulp tissues and periodontal ligaments.<sup>10</sup> In this case, splinting was done with composite and stainless steel arch wire 0.5mm in diameter. This type of flexible splinting allows adequate maintenance of oral hygiene and is easily tolerated by the patient.<sup>6</sup> Meticulous oral hygiene care and optimal gingivae health were emphasized to minimize risks of healing complications and infection-related resorption. The combination of timely management and maintenance of good oral hygiene throughout the healing period might have contributed to the good outcome in this case. Different types of dental trauma have different healing outcomes. Factors such as the timing of treatment, handling of the tooth, the severity of trauma, concomitant injuries to the supporting structures, the degree of contamination and tooth development maturity may influence treatment outcomes.<sup>6,7</sup> In the present case, different entities of dental trauma occurred simultaneously which further complicated

the management. Some teeth may show undesirable outcomes early and others have late presentation. However, the treatment aim for this patient is to maintain as many traumatized teeth in function with minimal undesirable outcomes for as long as possible. Of the many types of dental trauma, tooth avulsion is considered as the most serious form resulting in a complete displacement of the tooth out of its socket and consequently damaging its supporting periodontal apparatus. The ideal treatment for an avulsed permanent tooth is to immediately replant the tooth into its socket, thus allowing periodontal reattachment and possible pulpal revascularization. Total periodontal ligament cells necrosis can be expected after more than 1-hour extra-alveolar time and this increases healing complication.<sup>10</sup> In the present case, due to the prolonged extra-alveolar time which was more than 4-hours, it was anticipated that following replantation, periodontal healing would be achieved by replacement resorption. Although replacement resorption is an expected undesired outcome, nevertheless, in the current case it can be regarded as otherwise. It helps to hold the replanted tooth in its socket for aesthetic and occlusal function. This indirectly allows the preservation of alveolar bone height and width for alternative prosthesis later. Another undesirable outcome of replacement resorption is infra-occlusion.<sup>12</sup> In the present case, it was fortunate that infra-occlusion was not observed. One possible explanation for this is perhaps the patient has surpassed her growth spurt period, thus the rate of replacement resorption observed is relatively slower compared to that commonly observed in young patients. In the event of infra-occlusion, decoronation can be an alternative treatment option if the infra-occlusion is more than 1 mm. Decoronation helps to maintain the gingival height and the existing bone volume. It minimizes the need of future ridge augmentation for prosthesis placement later.<sup>13,14</sup> Stage of root development may influence the chances of revascularization of a tooth following trauma. An immature tooth has better chances of revascularization than a mature one.<sup>6,7</sup> In the current case, all the traumatized teeth had matured roots thus chances of pulp revascularization were extremely limited. Therefore, root canal therapy was initiated early as recommended to reduce the risks of inflammatory root resorption.<sup>11-15</sup> Calcium hydroxide was placed as intra-canal medicament due to its simultaneous effects of disinfection and proteolysis action on pulp tissue as well as its capacity to initiate hard-tissue healing.<sup>16</sup> Intrusive luxation represents a complex wound-contusion of alveolar bone that generally results in compression of periodontal ligaments fibers, damage to cementum and disruption of neurovascular supply to the pulp. Similarly, the complications associated with this type of injury were inflammatory root resorption or replacement resorption and pulp necrosis. In this case, tooth 11 sustained severe intrusion of more than 7 mm, thus surgical repositioning was carried out with subsequent stabilization with a flexible splint. The degree of the intrusion makes this procedure a more reasonable option than orthodontic extrusion which is more time demanding.<sup>17</sup> Furthermore, surgical repositioning provides timely solutions to the displacement and is inexpensive. As pulp necrosis is certain with closed apex tooth, pulp extirpation was performed as a prophylactic measure against the risk of inflammatory root resorption.<sup>11</sup> In response to the extensive damage to periodontal ligaments, a sign of replacement resorption was seen radiographically 1-month after the injury but no signs of further deterioration were noted subsequently with repeated placement of calcium hydroxide intra-canal medicament. Subluxation injury on the other hand results in injuries to the periodontal ligament fibers in forms of edema, bleeding and tearing. Although relatively rare, a secondary effect of the impact may be total rupture of the neurovascular supply to the

pulp.<sup>18</sup> In the present case, there might be an initial partial rupture of the neurovascular bundle which has led to progressive pulp necrosis within 1-month after the injury. Root canal treatment was performed and resolution of signs and symptoms was found following intra-canal dressing with calcium hydroxide. Another important aspect of dental trauma management is the restorative rehabilitation of the missing teeth. Although a removable acrylic denture could immediately restore the aesthetic and psychological deficits associated with a missing anterior tooth, this type of prosthesis possesses several disadvantages of being less stable, predisposing adjacent tissue to the development of caries and gingivitis, and less comfortable to the patient.<sup>19</sup> Furthermore, in view of the absence of infraocclusion, hence, it was decided that construction of a resin-bonded bridge could offer better aesthetic and functional outcomes to the patient. This serves as an interim prosthesis until a dental implant can be placed later upon completion of her growth.

## Conclusion

In summary, the extent of dental injuries with its anticipated complications imposes a great challenge for rehabilitation of the dentition. Immediate and effective management of dental trauma based on the recommended by current guidelines often minimizes the possible complications. Replantation and prosthetic rehabilitation help to restore the patient's aesthetic appearance and occlusal function thus preventing future physiological trauma and limits the complexity of treatment later. In this case, during the 30 months' follow-up, the dental aesthetics and function were maintained without signs of further resorption. The patient is currently placed under periodical review and appropriate treatment will be rendered if a need arises.

## Funding

None.

## Acknowledgments

None.

## Conflicts of interest

The author declares that there is no conflict of interest.

## References

1. Caldas AD, Burgos MEA. A retrospective study of traumatic dental injuries in a Brazilian dental trauma clinic. *Dent Traumatol.* 2001;7(6):250-253.
2. Andresson L. Epidemiology of traumatic dental injuries. *J Endod.* 2013;39(3 Suppl):S2-S5.
3. Andreasen JO, Lauridsen E, Gerds TA, et al. Dental Trauma Guide: a source of evidence-based treatment guidelines for dental trauma. *Dent Traumatol.* 2012;28(5):345-350.
4. Andreasen JO, Vinding TR, Ahrensburg SS. Predictors for healing complications in the permanent dentition after dental trauma. *Endodontic Topics.* 2006;14(1):20-27.
5. Diangelis AJ, Andreasen JO, Ebeleseder KA, et al. International Association of Dental Traumatology guidelines for the management of traumatic dental injuries: 1. Fractures and luxations of permanent teeth. *Dent Traumatol.* 2012;28(1):2-12.
6. Andersson L, Andreasen JO, Day P, et al. International Association of Dental Traumatology guidelines for the management of traumatic dental injuries: 2. Avulsion of permanent teeth. *Dent Traumatol.* 2012;28(2):88-96.

7. Wilson S, Smith GA, Preisch J, et al. Epidemiology of dental trauma treated in an urban pediatric emergency department. *Pediatr Emerg Care.* 1997;3(1):12–15.
8. Andreasen JO, Farik B, Munksgaard EC. Long-term calcium hydroxide as a root canal dressing may increase risk of root fracture. *Dent Traumatol.* 2002 18(3): 134-137.
9. Zerfowski M, Bremerich A. Facial trauma in children and adolescents. *Clin Oral Investig.* 1998;2(3):120–124.
10. Kristerson L, Andreasen JO. The effect of splinting upon periodontal and pulpal healing after auto transplantation of mature and immature permanent incisors in monkeys. *Int J Oral Surg.* 1983;12(4):239–249.
11. Andreasen JO, Andreasen FM Avulsions. In *Textbook and Color Atlas of Traumatic Injuries to the teeth.* 4th edn, Blackwell, Oxford, England, UK, 2007. p. 444–480.
12. Andersson L, Malmgren B. The problem of dentoalveolar ankylosis and subsequent replacement resorption in the growing patient. *Aust Endod J.* 1999;25(2):57–61.
13. Malmgren B. Decoronation: how, why, and when? *J Calif Dent Assoc.* 2000;28(11):846–854.
14. Filippi A, Pohl Y, Von Arx T. Decoronation of an ankylosed tooth for preservation of alveolar bone prior to implant placement. *Dent Traumatol.* 2001;17:93–95.
15. Cvek M. Treatment of non-vital permanent incisors with calcium hydroxide. IV. Periodontal healing and closure of the root canal in the coronal fragment of teeth with intra-alveolar fracture and vital apical fragment. A follow-up. *Odontol Revy.* 1974;25(3):239–246.
16. Cvek M. Endodontic management and the use of calcium hydroxide in traumatized permanent teeth. In *Textbook and Color Atlas of Traumatic Injuries to the teeth.* 4th edn, Blackwell, England, UK, 2007. p. 598–658.
17. Andreasen JO, Bakland LK, Andreasen FM. Traumatic intrusion of permanent teeth. Part 2. A clinical study of the effect of preinjury and injury factors such as sex, age, stage of root development, tooth location and extent of injury including number of intruded teeth on 140 intruded permanent teeth. *Dent Traumatol.* 2006;22(2):90–98.
18. Lauridsen E, Hermann N, Gerds TA, et al. Dental Trauma. Combination injuries 2. The risk of pulp necrosis in permanent teeth with subluxation injuries and concomitant crown fractures. *Dent Traumatol.* 2012;28(5):371–378.
19. Walmsley AD. Acrylic Partial Dentures. *Dental Update.* 2003;30:424–429.