

Incisalign: A Novel Surgical Technique to Integrate Corticotomies in the Invisalign® Orthodontic Treatment

Abstract

To date, the number of adult patients looking for aesthetic and comfortable alternatives to traditional fixed appliance therapies is increasing significantly. One of the biggest challenges an adult orthodontic patient faces is the time spent wearing the appliance: to accelerate orthodontic tooth movement and shorten treatment duration is thus a topical issue. Corticotomy is an effective and safe technique to accelerate orthodontic treatment: however corticotomies are associated to significant post-operative discomfort and are time consuming. Alternative minimally invasive procedures combining micro-incision with selective tunneling hard and soft tissue grafting and piezoelectric incision, have thus been developed to shorten surgical time and to limit patient discomfort and to increase periodontal safety. The association of mini-invasive surgical approaches and aesthetic and comfortable appliances, like aligner orthodontics, could increase the acceptance rate of adult patients. On the basis of these considerations and with the aim of a further improvement of minimally invasive procedures an innovative, outpatient, simplified tunneling procedure combining piezoelectric cortical incisions, bone tissue grafting and clear aligners has been designed and will be here described.

Keywords: Corticotomy; Orthodontics; Minimally invasive; Outpatient; Clear aligners

Research Article

Volume 5 Issue 5 - 2016

Alberto Diaspro, Tommaso Castroflorio, Simone Parrini*, Gabriele Rossini, Serena Ravera and Andrea Deregibus

Department of Orthodontics, Dental School, University of Turin, Italy

***Corresponding author:** Simone Parrini, Department of Orthodontics, Dental School, University of Turin, Via Nizza 230, Turin, Italy, Email: simo.parrini@gmail.com

Received: November 11, 2016 | **Published:** November 30, 2016

Introduction

In this fast-paced and self-conscious society, time and aesthetics have become increasingly important and the number of adult patients looking for aesthetic and comfortable alternatives to traditional fixed appliance therapies is increasing significantly. One of the biggest challenges an adult orthodontic patient faces is the time spent wearing the appliance: to accelerate orthodontic tooth movement, and thus shorten treatment duration, is thus a topical issue [1]. Corticotomy is an effective and safe technique to accelerate orthodontic treatment: surgical wounding of cortical bone potentiates tissue reorganization and healing, by a transient burst of localized hard and soft tissue remodeling. The so called Regional Acceleratory Phenomena (R.A.P.) healing is a natural localized reaction of soft and hard tissues in response to an injury, characterized by increased perfusion, bone turnover and decreased bone density. Its well known that surgical trauma of the cortical bone increases the expression of several inflammatory cytokines, which leads to more osteoclast and, consequently, greater bone remodeling process [2]. The time available to accelerate tooth movement is thus limited to the 2-3 months following corticotomy. During the reactive and reparative phases 4-6 mm of tooth movement might be expected, doubling the normal rate of orthodontic tooth movement. A recent review of the existing literature reported that tooth movement was found to be slightly quicker with surgically assisted orthodontics in comparison with conventional treatment over periods of one month (MD 0.61 mm; 95% CI 0.49 to 0.72; P value <0.001) and three months (MD 2.03 mm; 95% CI 1.52 to 2.54; P value <0.001) [3]. However corticotomies are associated to significant post-

operative discomfort, are time consuming and may require patient sedation: moreover are associated to post-operative morbidity and periodontal risks mainly due to the flap elevation. Alternative minimally invasive procedures combining micro-incision with selective tunneling hard and soft tissue grafting and piezoelectric incision, have thus been developed to shorten surgical time and to limit patient discomfort and to increase periodontal safety. The association of mini-invasive surgical approaches and aesthetic and comfortable appliances, like aligner orthodontics, could increase the acceptance rate of adult patients. On the basis of these considerations and with the aim of a further improvement of minimally invasive procedures an innovative, minimally invasive, simplified tunneling procedure combining piezoelectric cortical incisions and bone tissue grafting has been designed and will be here described.

Materials and Methods

A 24 years old male presented with a bilateral molar class I malocclusion, severe crowding, open bite and reduced upper arch width (Figure 1). In order to avoid the palatal surgical expansion and considering the conclusions by Bhattacharya et al. according to which alveolar corticotomies not only can accelerate the orthodontic treatment but also provide the advantage of increased alveolar width to support the teeth and overlying structures, corticotomies were selected to assist the Invisalign® (Align Technology, San José, CA, USA) orthodontic treatment [4]. A cone beam computed tomography (CBCT) scan was collected among all the conventional orthodontic and surgical diagnostic data in order to design the surgical assisted orthodontic treatment

plan. CBCT data were very helpful in reviewing the orthodontic treatment plan via the Clin Check® planning in order to obtain a maxillary arch expansion of about 4 mm in the premolar region with staging set at 0.25 mm per aligner. A total duration of 30 months of treatment was forecasted. The patient did not report any systemic contraindication to surgery and provided written informed consent to the described procedures. All the statements of the Declaration of Helsinki were followed. The day when surgery was scheduled, the patient performed mouth-rinse containing 0.2% chlorhexidine for 1 minute pre-operatively and Mepivacaine (carbocaine 2% AstraZeneca S.p.a. Milan, Italy) with adrenaline 1:100.000 was infiltrated tea reducing bleeding at the surgical site. Full-thickness vertical gingival incisions were performed along the median and both in lateral frenula using a number 15 blade and not extending to the keratinized gingiva. Full thickness incisions were made cutting the mucosa to the periosteum, allowing the blade to touch the alveolar bone. A sharp periosteal elevator allowed wide subperiosteal tunneled dissection over the roots of the involved teeth, both mesially and distally (Figure 2) Subsequently, a piezoelectric micro saw (*Surgysonic Moto® Esacrom S.r.l. Imola, Italy*) was introduced into the tunnel created

underneath the flap and interproximal corticotomies extended through the entire thickness of the cortical layer, just barely penetrating the medullary bone were performed between the dental roots following the long axis of the alveolus and stopping at a distance of 2 mm from the papilla up to the vestibular fornix, 4-5 mm above the apex of the teeth, not penetrating the maxillary sinus. Endoscopic assistance through fiber optic was not necessary because of the direct sight allowed by the frenula incisions. An established augmentation procedure was performed in this case. The suture of the vertical incisions using PGA 3-0 thread (*Omnia S.p.a, Fidenza, Italy*) in the muscular layer and Silk 3-0 thread (*Ethicon, Johnson & Johnson, Somerville, NJ, USA*) on the mucosa complete the surgical procedure. Prophylactic amoxicillin 2 gr per day medication was prescribed for one week; pain killing was achieved using Paracetamol 500 mg + Codeine 30 mg three times a day restricted to the first postoperative days to avoid interference with the RAP. Orthodontic treatment was resumed on the same day using Invisalign® aligners. During the RAP phase aligners were changed every 5 days, reducing of about one third the normal protocol of aligners changing (14 days).

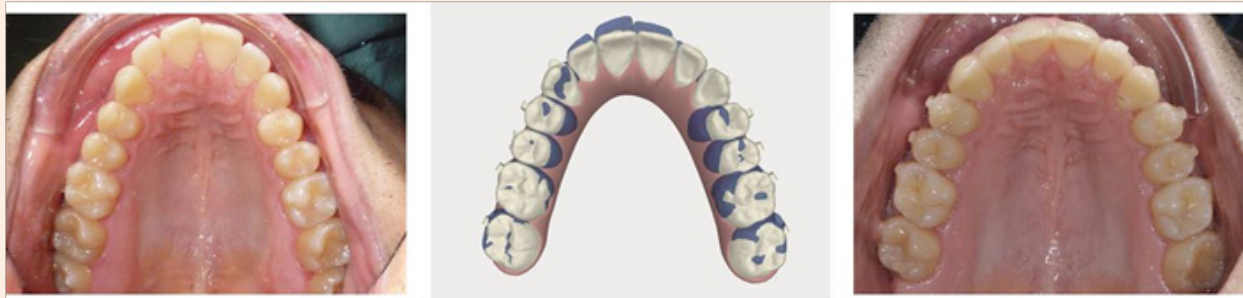

Figure 1: patient upper arch before and after treatment and Clincheck image.

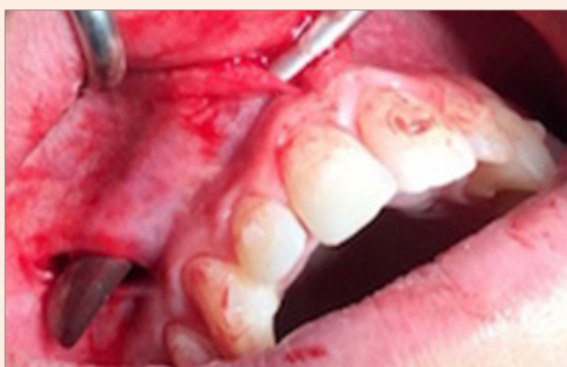

Figure 2: The minimally invasive surgical access.

Result

This approach permitted to reduce the duration treatment forecasted from 30 to 18 months. Nor dentinary hyper sensibility neither loss of tooth vitality, nor adverse periodontal events neither significant reduction in crestal bone height and no evidence of

apical root resorption effects were clinically and radiographically noticeable during 12 months of follow-up evaluation. A TC Cone Beam was collected to evaluate final results (Figure 3).

Discussion

The biologic limit of orthodontic tooth movement includes the pre-treatment alveolar bone and the surrounding soft tissues. Historically surgery was required in order to overcome these limits but periodontally accelerated osteogenic orthodontics' (PAOO) methods, published in the last 15 years including flapless 'piezocision' and transmucosal micro-osseous perforations, have been demonstrated effective in reducing overall orthodontic treatment times. However, these techniques have not been widely embraced by the orthodontic community since they associated with post-operative discomfort and a high risk of complications leading to a low acceptance by the patient. These are also the main reasons why minimally invasive corticotomies techniques were introduced: furthermore the possibility of restoring alveolar volume and periodontium integrity in a single stage procedure makes this minimally invasive approaches even more attractive [5,6]. The physical injury determined by the corticotomy evokes regional acceleratory phenomena (RAP) that involves a temporary

osteopenia responsible for the rapid tooth movement: with the Invisalign® technique, aligners were changed every 5 days. Selective bone injury stimulates both the catabolic and anabolic responses in the periodontium and the sequential demineralization-demineralization phenomenon justifies the facilitated tooth movement after corticotomy surgery [1]. The reason for this kind of approach is to maximize the usefulness of the RAP window, lasting for about 9 weeks after surgery, but up to 14 weeks if the orthodontic movement is continued where the bone is more pliable allowing moving teeth rapidly through the demineralized bone matrix. Wilcko performed extensive corticotomy cuts with burs after a sulcular-releasing incision and full-thickness flap elevation labially and lingually under intravenous or oral sedation [5]. Significant trauma always derived from the elevation of large flaps and the extensive nature of the corticotomies, no matter the technique: ultrasonic microsaws, once introduced, allowed a safer corticotomy [6-7]. Hernandez-Alfaro presented endoscopically assisted piezocision performed under local anesthesia through a tunnel approach using only one to three buccal vertical incisions per arch at the upper or lower midline and/or behind the upper canine, performed with angled piezoelectric saws: their technique permitted an improved endoscopic control of the cuts with respect to the roots. The technique here presented is an evolution of the one proposed by Hernandez-alfaro and Dibart [1-8]. Incisions are made through the frenula, allowing a more distal surgical access: the median to the six anterior teeth while the lateral ones to the premolars and molars of the respective quadrant. Another advantage of this technique is represented by the chance to reach the superior wisdom teeth if their extraction has been planned: the tunnel started at the lateral frenulum could be used to access the bone surrounding the wisdom tooth with the piezoelectric saw.

Dedicated Esacrom (Esacrom S.r.l., Imola, Italy) angulated saws have been designed and engineered to perform corticotomies through the surgical access without the need of endoscopic assistance. The use of dedicated piezoelectric saw is mandatory to avoid thermal damage of the soft tissues. Cortical incisions can be easily performed on direct crown and cortical bone vision, together with the tactile sensation of the interdental concavity between the root prominences, just designing more distal lateral incisions, even if root proximity, root convexity or abnormal root angulation are critical. With this surgical technique the graft could be easily located as requested by Wilcko, Vercellotti and Dibart, and placed as crestally as required [5-7]. This technique is very respectful of the periodontium since no sulcular incisions are performed even though a full-thickness flap elevation is obtained. At the meantime it is aimed to be user-friendly, being performed in dental office, allowing soft and hard tissue grafting when required, minimizing post-operative discomfort, and reducing chairside time. It allows the clinician to treat both full-arch and segmental malocclusion in one-step or sequential surgery. This technique has been conceived to overcome the referred complications of previously described approaches, to avoid periodontal damage and to offer the chance to apply a unique surgical protocol, no matter the number of sites to treat and the need or not of bone graft. To date in literature there are only two published reports concerning Invisalign®-assisted treatment with corticotomies, and both of them involve a segmental malocclusion: by means of this technique we treat successfully a full arch malocclusion [9,10]. Clinical trials are guaranteed to confirm these preliminary results in order to elicit this technique as the novel surgical standard in performing corticotomies.

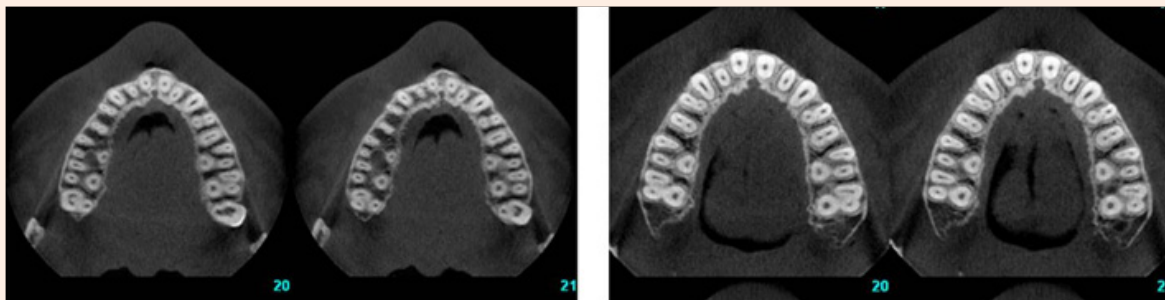


Figure 3: Cone Beam images before and after treatment.

References

- Hernández-Alfaro F, Guijarro-Martínez R (2012) Endoscopically assisted tunnel approach for minimally invasive corticotomies: a preliminary report. *J Periodontol* 83(5): 574-580.
- Teixeira CC, Khoo E, Tran J, Chartres I, Liu Y, et al. (2010) Cytokine expression and accelerated tooth movement. *J Dent Res* 89(10): 1135-1141.
- Fleming PS, Fedorowicz Z, Johal A, El Angbawi A, Pandis N (2015) Surgical adjunctive procedures for accelerating orthodontic treatment. *Cochrane Database Syst Rev* 6: CD010572.
- Bhattacharya P, Bhattacharya H, Anjum A, Bhandari R, Agarwal DK, et al. (2014) Assessment of corticotomy facilitated tooth movement and changes in alveolar bone thickness -a CT scan study. *J Clin Diagn Res* 8(10): ZC26-ZC30.
- Wilcko MT, Wilcko WM, Pulver JJ, Bissada NF, Bouquot JE (2009) Accelerated osteogenic orthodontics technique: A 1-stage surgically facilitated rapid orthodontic technique with alveolar augmentation. *J Oral Maxillofac Surg* 67(10): 2149-2159.
- Dibart S, Sebaoun JD, Surmenian J (2009) Piezocision: A minimally invasive, periodontally accelerated orthodontic tooth movement procedure. *Compend Contin Educ Dent* 30(6): 342-350.

7. Vercellotti T, Podesta A (2007) Orthodontic microsurgery: A new surgically guided technique for dental movement. *Int J Periodontics Restorative Dent* 27(4): 325-331.
8. Dibart S¹, Surmenian J, Sebaoun JD, Montesani L (2010) Rapid treatment of Class II malocclusion with piezocision: two case reports. *Int J Periodontics Restorative Dent* 30(5): 487-493.
9. Owen AH 3rd (2001) Accelerated Invisalign treatment. *J Clin Orthod* 35(6): 381-385.
10. Keser EI, Dibart S (2011) Piezocision-assisted Invisalign treatment. *Compend Contin Educ Dent* 32(2): 46-51.