

Case Report: Macrodonia in a Unilateral Premolar in a Ten Year Old Child

Case Report**Abstract**

Cone-Beam Computed Tomography has become an invaluable tool in aiding in the diagnosis and treatment planning of complex cases by providing information in which a conventional two dimensional image lacks. This case reports illustrates the value of CBCT in diagnosing a rare tooth abnormality involving macrodonia of a single premolar. Macrodonia refers to teeth that are larger than normal. It is a rare occurrence. Our review of the literature showed that when macrodonia involves a premolar the majority of cases reported involved the mandibular second premolar [1], further review showed that only 8 cases have been reported of macrodonia of a unilateral mandibular second premolar [2], while only 5 cases of bilateral mandibular second premolars have been reported [3]. This case report involves a patient with macrodonia of an unilateral mandibular second premolar (Figure 1).

Keywords: Macrodonia; Unilateral mandibular second premolar; Cone-Beam computed tomography; Dental anomaly; CBCT

Volume 2 Issue 4 - 2015

Federico Lamus* and Jon Y Willingham

University of Missouri-Kansas City, USA

***Corresponding author:** Federico Lamus, Oral and Maxillofacial Radiologist, University of Missouri-Kansas City, General Dentistry and OFR at Heartland Dental Group 3507 S, 4th St Leavenworth, Kansas, USA, Tel: (913) 682-1000; Email: federicolamus@att.net

Received: May 22, 2015 | **Published:** June 18, 2015

Abbreviations: CBCT: Cone Beam Computed Tomography; BW: Bitewing Radiograph; PA: Periapical Radiograph; MA: Milli Amperage; kVp: Peak Kilo voltage; mGycm²: miligray/centimeter²; C-A: Coronal-to-Apical; M-D: Mesial-to-Distal; B-L: Buccal-to-Lingual

Introduction

A 10 year old white female presented for routine prophylaxis and periodic examination, the patient is under the care of an orthodontist with a preliminary treatment of a palatal expander. The patient's health history was unremarkable, which is pertinent in these cases since Macrodonia has been associated with systemic disturbances [4] or syndromes [5]. A posterior cross-bite and open bite (Figure 2) on the right side is present. The BW evaluation revealed what appeared to be a larger than normal unerupted tooth #29. Clinically tooth #30 was erupted and the primary molars #S and #T were also present. A PA was taken to confirm the suspicion of macrodonia of tooth #29 (Figure 3) and rule out distortion of the BW radiograph. A CBCT scan was recommended and performed to evaluate the position, size, location, and aid in treatment for tooth #29, the scan was evaluated and read by an oral and maxillofacial radiologist. A consultation was performed along with an oral and maxillofacial surgeon, orthodontist and a general dentist, and a treatment plan was formulated. The treatment including having tooth #29 removed to prevent impaction and resorption of adjacent teeth, orthodontic movement, and follow up with general dentistry.

Materials and Methods

A limited volume CBCT was taken using a Gendex DPX 700, set at 8 mA, 90 kVp x 6 secs delivering 321 mGycm² on the mandible. The scan showed moderate streak artifacts due to an orthodontic palatal expander appliance present on the maxilla. The scan revealed tooth #29 exhibiting severe macrodonia measuring approximately 10.42 mm in a buccal-lingual dimension (Figure 4), 14.61 mm in a C-A dimension (Figure 5), and 14.22 mm in a M-D dimension. These measurements are considerably larger

when compared to the same un-erupted contra-lateral tooth (tooth #20) measuring 9.17 mm in a M-D dimension (Figure 6) and 8.59 mm in B-L dimension (Figure 7).

The mesial aspect of the crown of tooth #29 appears to be wedged at the level of the cervix of tooth #28 and approximately 1 mm from the mid-root section of tooth #30, no resorption is noted on either tooth. The width of the mandible from cortex to cortex at the largest width of tooth #29 is 14.49 mm (Figure 8) from which it is expanded mildly when compared to a width of 11.23 mm at the same level of the mandible of the contra-lateral tooth #20 as seen on selected axial views (Figure 9). This is suggestive of moderate expansion of the cortex, likely due to the enlarged size of tooth #29. The inferior alveolar canal and mental foramen are not well visualized on the volume obtained.

Treatment Plan

The treatment plan was initially determined to be surgical removal of the tooth (#29) and full orthodontic appliances to be placed in order to correct malocclusion (Figure 2). Teeth #S (Figure 10) & #T (Figure 11) were removed to gain access to tooth #29. An attempt was made to measure tooth #29 post extraction using a caliper to compare those to the measurements taken in the CBCT examination (Figure 12 & 13) but the tooth was sectioned for removal due in part to the close proximity of tooth #28. It has not been determined whether the contra-lateral tooth (#20) will be extracted or not. Once the patient is in orthodontic treatment, a decision will be made by the Orthodontist on either using the spacing at area of tooth #29 for full mouth orthodontics or hold the space for implant placement in the future (Figure 14).

Discussion

The incorporation of CBCT in the dental office the has resulted in a more objective and accurate evaluations of the oral and maxillofacial anatomical structures. It provides more accurate and detailed information that conventional radiography simply cannot provide. It is an integral tool in aiding in the diagnosis

and treatment planning of especially complex cases involving dental anomalies. True macrodonia of both a single tooth and a premolar are rare. This case study depicts one of the few reported cases of a unilateral mandibular second premolar macrodonia in the literature [6,7]. The cause of this abnormality is unknown but vascular abnormalities like hemangioma can result in an increase in the size of adjacent structures (including adjacent teeth) due to the increase in irrigation, it has also been reported in cases of

hormonal imbalance like pituitary gigantism [8]. The use of CBCT proved to be extremely useful in localizing the dimensions and orientation of macrodonia which will be helpful in treatment planning but the complexity of this case does not stop at its rarity, it presented a serious challenge clinically due to the proximity to vital anatomical structures (i.e. mental foramen and inferior alveolar nerve and canal), the sheer size of the tooth, as well as the young age of the patient.

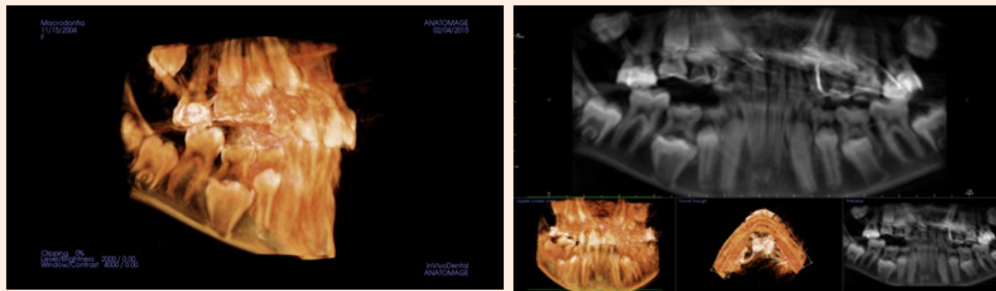


Figure 1: 3D Volume Rendering and Panoramic reformatted views of the CBCT.

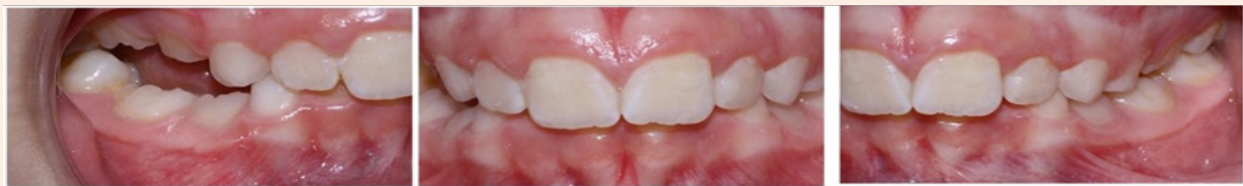

Figure 2: Pre-orthodontic treatment pictures.

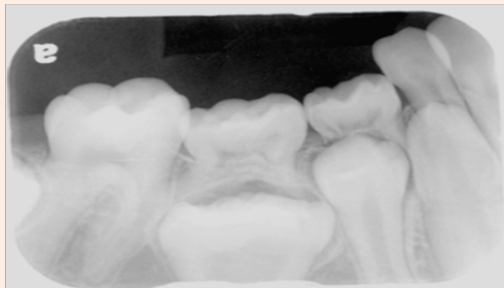


Figure 3: PA radiograph.

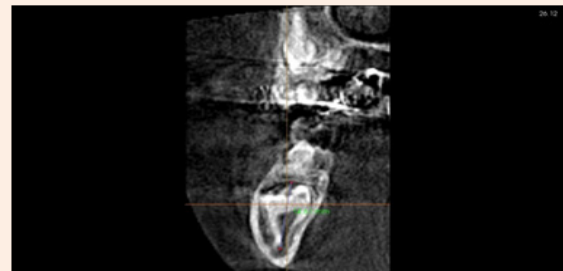


Figure 5: Reformatted cross-section C-A.

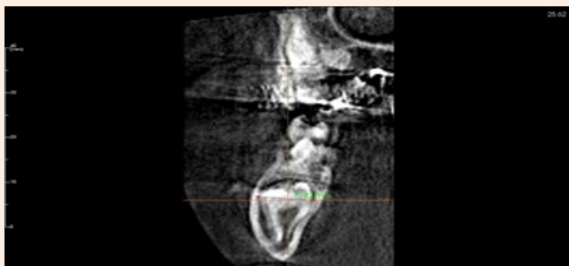

Figure 4: Reformatted cross-section B-L dimensions.

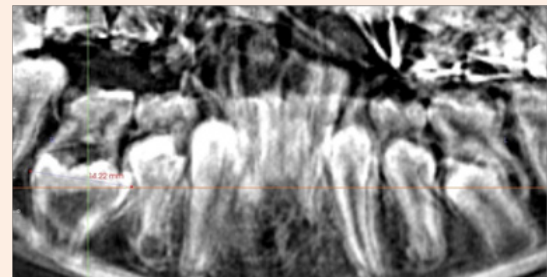


Figure 6: Corrected Panoramic View measuring #29 M-D.

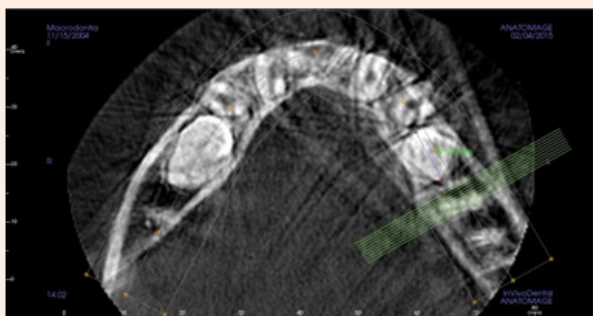


Figure 7: Corrected Axial View measuring M-D #20.

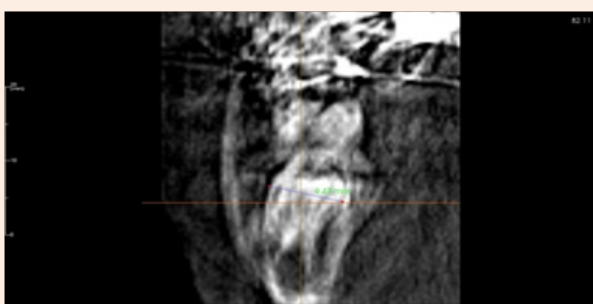

Figure 8: Reformatted cross-section #20 M-D dimensions.

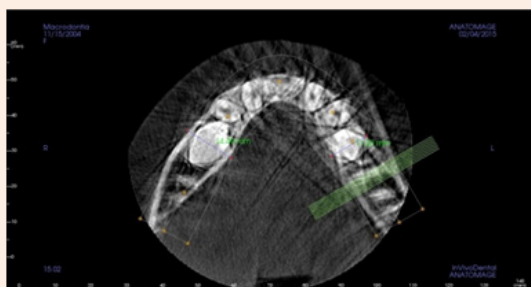


Figure 9: Axial views measuring cortex to cortex LL & LR.

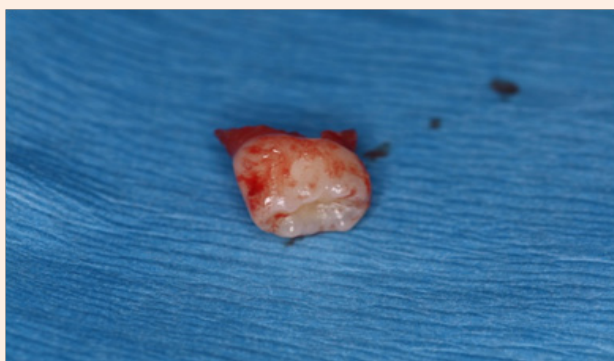

Figure 10: Tooth # S.

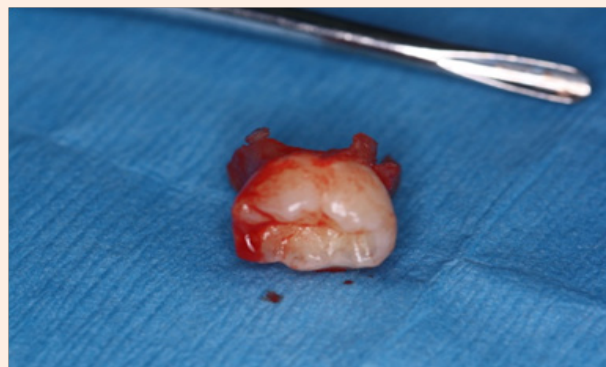

Figure 11: Tooth #T.

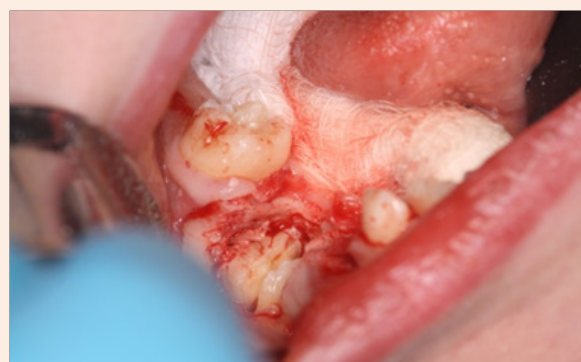

Figure 12: Surgical access.

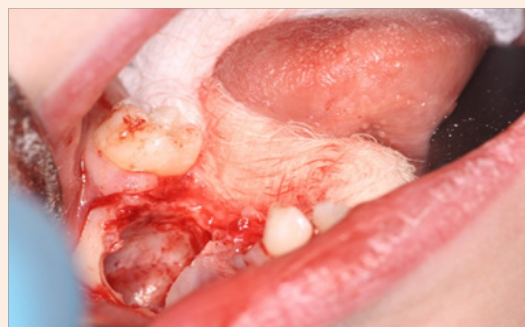

Figure 13: Post extraction socket.

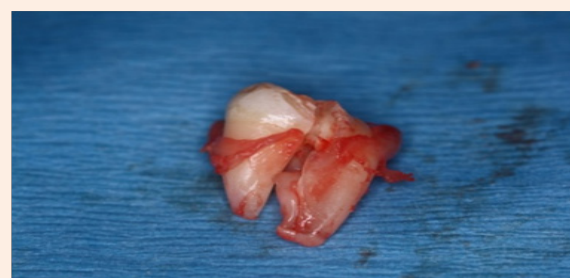


Figure 14: Tooth #29.

Conclusion

This case will be followed in our practice with a treatment plan that was formulated with a multi-disciplinary team that included an orthodontist, oral and maxillofacial surgeon, oral and maxillofacial radiologist and general dentists. As the treatment progresses we will do every attempt to follow up. A more comprehensive review of the literature will be done for the follow up report in this case since we are interested mostly in the clinical progression of this particular patient at this point in time. Multi planar reformatting was carried out at the work station using Anatomage *in Vivo* 5 Software with selected images that were adjusted for viewing and are not actual size. Any measurements or recorded markers have been made in the primary image fields and are included only as guidelines not as a substitute for complete analysis using the primary imaging series and the clinical measurements were done using a caliper.

References

1. Rootkin-Gray VF, Sheehy EC (2001) Macrodontia of a mandibular second premolar: a case report. *ASDC J Dent Child* 68(5-6): 347-349.
2. Mangla N, Singh Khinda VI, Kallar S, Singh Brar G (2014) Molarization of mandibular second premolar. *Int J Clin Pediatr Dent* 7(2): 137-139.
3. Canoglu E, Canoglu H, Aktas A, Cehreli ZC (2012) Isolated bilateral macrodontia of mandibular second premolar: A case report. *Eur J Dent* 6(3): 330-334.
4. Holmes J, Tanner MS (1976) Premature eruption and macrodontia associated with insulin resistant diabetes and pineal hyperplasia. Report of two cases. *Br Dent J* 141(9): 280-284.
5. Herrmann J, Pallister PD, Tiddy W, Opitz JM (1975) The KBG syndrome-a syndrome of short stature, characteristic facies, mental retardation, macrodontia and skeletal anomalies. *Birth Defects Orig Artic Ser* 11(5): 7-18.
6. Babaji P, Chaurasia VR, Masamatti VK, Tiwari S, Malik S (2014) Unilateral molariform macrodont mandibular second premolar: an unusual case report in a nonsyndromic patient. *J Clin Diagn Res* 8(7): ZD08-ZD09.
7. Kyriazidou A, Haider D, Mason C, Parekh S, Bloch-Zupan A (2013) Case report: Macrodont mandibular second premolars, a hereditary dental anomaly. *Eur Arch Paediatr Dent* 14(6): 411-416.
8. White SC, Pharoah M (2009) *Oral Radiology: Principles and Interpretation*. (6th edn), Mosby Elsevier, USA.