

Modern Methods of Diagnosis of Periodontal Diseases in Teenagers

Abstract

In the article the possibilities of new methods of diagnosis of periodontal diseases in teenagers are characterized. A hygienic condition of the oral cavity was evaluated by the use of the intraoral camera Durr Dental's Vista Proof (Germany). The polymerase chain reaction (PCR) was performed to detect DNA of pathogenic periodontal bacteria in dental plaque. It was found that the increase in the severity of the disease was accompanied by increased pathogenic periodontal micro flora in dental plaque.

Keywords: Pathogenic periodontal micro flora; Polymerase chain reaction; Dental plaque; Intraoral camera; Periodontal diseases; Teenagers

Mini Review

Volume 2 Issue 3 - 2015

Birsan I*

Department of Paediatric Dentistry, A.A. Bogomolets National Medical University, Ukraine

***Corresponding author:** Birsan I, Department of Paediatric Dentistry, A.A. Bogomolets National Medical University, 25A, Degtyarivska, apt.178, Kiev 04119, Ukraine, Tel: +38 050 357 25 60; Email: yuliasha0401@ukr.net

Received: April 9, 2015 | **Published:** June 06, 2015

Abbreviations: PCR: Polymerase Chain Reaction; CCG: Chronic Cattarral Gingivitis

Introduction

A high prevalence of periodontal tissue diseases in teenagers has been identified [1]. An unsatisfactory level of individual oral hygiene and a lack of systematic professional hygiene instructions lead to a progression of them. The interaction of different types of microorganisms, called pathogenic periodontal micro flora, in the biofilm defines periodontal infection and development of serious complications, including the loss of teeth [2]. Five of them are the most important in this case: *Prevotella intermedia*, *Bacteroides forsythus* (*Tannerella forsythia*), *Treponema denticola*, *Actinobacillus actinomycetemcomitans*, *Porphyromonas gingivalis*. The main difficulty in studying pathogenic periodontal micro flora is the technical complexity of the cultivation of these microorganisms. Modern methods of uncovers a dental plaque and identification these microorganisms are essential.

Discussion

The Durr Dental's Vista Proof intraoral camera (Germany) was effective in the definition of hygiene status of oral cavity of each patient (Figure 1-3). A direct correlation between the level of oral hygiene and the severity of the pathological process in it was determined. *Prevotella intermedia*, *Bacteroides forsythus* (*Tannerella forsythia*), *Treponema denticola* were found in dental plaque of the patients with the low severity of CCG (25%). Patients with moderate severity of CCG had all 5 pathogenic periodontal microorganisms in dental plaque (65%) (Figure 4). In our investigation there were no cases of hard severity of CCG, but 5% of patients were diagnosed with localized periodontitis. They had all the above mentioned periodontal pathogens in dental plaque. The periodontal pathogenic micro flora in the dental plaque was not found in the healthy patients (5%).

Conclusion

The use of the intraoral camera Vista Proof increases the

objective character of evaluation of the hygienic condition of the mouth, motivating the patients to improve their personal hygiene as well as permitting to control the quality of the tooth plaque removal. The PCR is a reliable and promising method for the early diagnosis of periodontal diseases. In case of the chronic catarrhal gingivitis of low and moderate severity, the revealing of periodontal pathogen DNA in the dental plaque is a basis for the negative diagnosis, providing the absence of the modern preventive measures and appropriate treatment. The diagnosis of chronic localized periodontitis in 5 % of patients indicates the rapid progression and aggressive course of the pathological process in the periodontium in teenagers. Identification of periodontal pathogens in dental plaque by PCR greatly enhances the early diagnosis of CCG risk factors in adolescents and allows for detailed analysis of the relation between each factor and severity of the process.

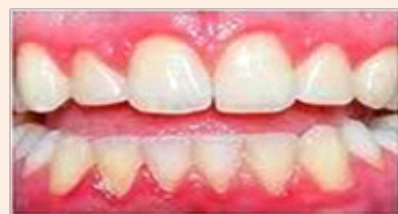

Figure 1: Clinical image.

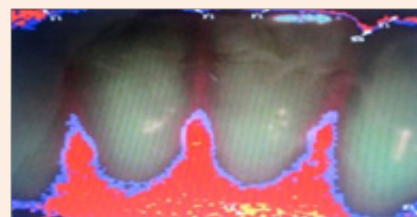


Figure 2: Photo made by Vista Proof camera. Plaque on the incisors of the lower jaw.

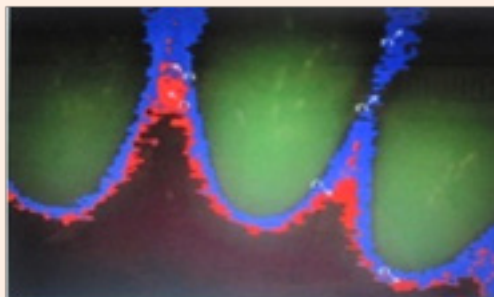


Figure 3: Control after the professional Dental hygiene treatment.

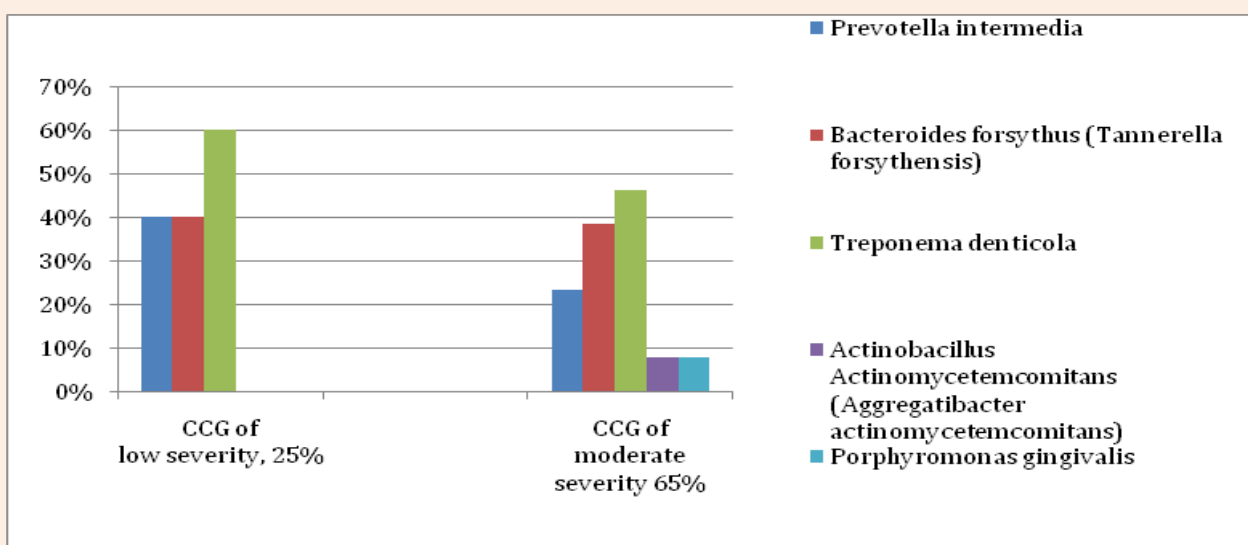


Figure 4: Revealing of the Periodontal Pathogenic Microorganism DNA.

Acknowledgment

The author expresses her gratitude to the Dep of Paediatric Dentistry and Dental Disease Prevention of A.A. Bogomolets National Medical University and to Prof L.A. Khomenko, to the staff of Diagnostic Laboratory of the Scientific Research Centre of Biological Department of Taras Shevchenko National University of Kiev (Kive, Ukraine).

References

1. Scardina GA, Buonamente A, Messina P (2008) Efficacy of an oral health training programme for visually impaired individuals. Ig Sanita Pubbl 64(4): 509-516.
2. Muller 2H (2001) Parodontologie. Stuttgart: Georg Thieme-Verlag.