

Orf's nodules in Muslim communities after the religious sacrifice of goat and sheep, 7 cases

Abstract

Introduction: The ON is a zoonosis caused by a Parapoxvirus. The diagnosis is based on the clinic and the concept of contact with sheep and goats. Dermoscopy is poorly understood in the literature. Complications can occur but remains rare.

Methods: We retrospectively analyzed 7 cases of ON at the clinical, dermoscopic level and we raised the complications.

Results: The mean age was 42 years, 6 patients without antecedents and 1 chronic hemodialysis and diabetic patient; all patients had a contact with the sheep during the Muslim sacrifice feast, the lesion sat at hands in all our patients. 4 patients with a nodular form, 2 patients in the ulcerated form, and 1 patient with a pseudo-tumoral form. Dermoscopically; all the patients had a red background, 5 had a central ulceration, 6 with a peripheral erythematous ring, the central whitish yellow zone in 4 patients, milky red blood cells in 1 patient, linear vessels in 2 patients, point vessels in 3 patients, crusts in 2 patients. As complications; erysipelas was observed in two patients, lymphangitis in one patient, paronychia in one patient. Biopsy was performed in a single patient with the pseudo-tumor form.

Keywords: orf, dermoscopy, contagious, ecthyma, viral, muslim feast

Volume 4 Issue 3 - 2020

Kaoutar Achehboune, Khadija Elboukhari, Hanane Baybay, Sara Elloudi, Fatima Zahra Mernissi

Department of Dermatology-Venereology, Hospital University Hassan II-Fez, Morocco

Correspondence: Kaoutar Achehboune, Department of Dermatology-Venereology, Hospital university Hassan II-Fez, Morocco, Email achehboune.kaoutar@gmail.com

Received: September 27, 2019 | **Published:** June 29, 2020

Introduction

The Orf's nodule (ON) or Ecthyma contagiosum, is a zoonosis caused by Parapoxvirus genus of the Poxviridae family. The diagnosis is based on the clinic and the concept of contact with sheep and goats. Dermatoscopy is poorly understood in the literature. Complications can occur but remains rare.

Methods

We realised a retrospective analyse of the clinical and dermoscopic images and we raised the complications of all cases of Orf Nodule in our department of dermatology and venereology of Hassan II University Hospital of Fez in Morocco, over a period of one year, between January 2017 et January 2018. Our department is one of the largest teaching units in Morocco, integrated into a tertiary school; it is a reference hospital in the central region of the country.

Result

We have collected 7cases of Orf nodule. The mean age was 42 years, 6 patients without antecedents and one patient with diabetes and chronic hemodialysis. All patients had a contact with the sheep, during the Muslim sacrifice feast. The lesion sat at hands in all our patients. Clinically, 4 patients with a nodular form (Figure 1), 2 patients with ulcerated form (Figure 2&3), and 1 patient with a pseudo-tumoral form (Figure 4). At the dermoscopy; all the patients had a red background, 5 had central ulceration, 6 with a peripheral erythematous ring, the central whitish yellow zone in 4 patients, milky red blood cells in 1 patient, linear vessels in 2 patients, point vessels in 3 patients, crusts in 2 patients. As complications; erysipelas was observed in two patients (Figure 5), lymphangitis in one patient (Figure. 1), paronychia in one patient. Biopsy was performed in

a single patient who presented a pseudo-tumor form, the result of which was in favor of the Orf nodule. Symptomatic treatment was instituted in all our patients, antibiotic therapy was started in a three patients who had the associated lymphangitis and erysipelas testifying to a bacterial superinfection, the patient with the pseudo-tumoral form was lost sight of.

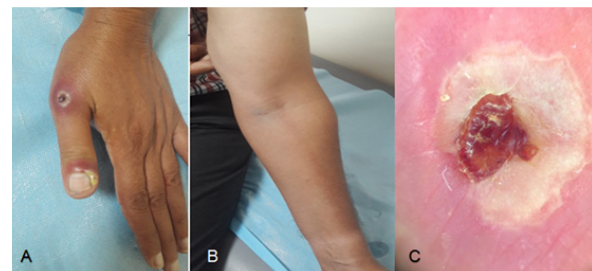


Figure 1 (A,B) Nodular form dermoscopy with lymphangitis. (C)lymphangite.

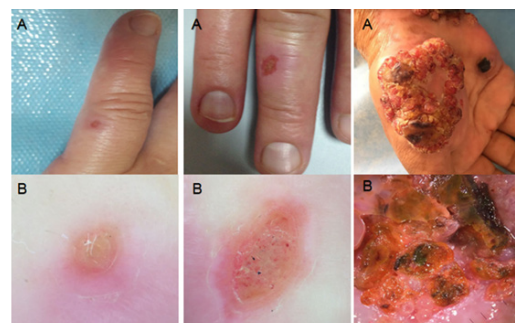


Figure 2 (A) ulcerated form, (B) Dermascopy.

Figure 3 (A) ulcerated form, (B) Dermascopy.

Figure 4 (A) On pseudo tumoral form, (B) Dermascopy .

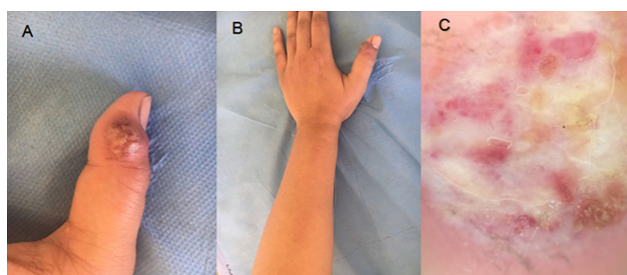


Figure 5 (A,B) Nodular form with erysipelas, (C) Dermoscopy.

Discussion

Orf's nodule is a zoonosis with epithelial tropism, transmitted to humans from infected animals, sheep and goats (sheep, goat).¹

The diagnosis is based on the appearance clinic and the concept of contact with these animals. In our context the muslim sacrifice feast is customary to sacrifice a sheep for God, as a reinterpretation of when God asked Ibrahim to sacrifice his son Isaac. Hence the contact with fresh meat. This increases the risk of this infection in this population. The incubation is from 3 to 13 days. The lesion begins at the site of inoculation, often the hand, in the form of an erythematous macule quickly turning into a papule, becoming nodular, then oozing and crusting. The healing is done without scar. The number of lesions varies from 1 to 10. An associated lymphangitis can be observed,² this is the case of one of our patients.

Dermoscopy is a non-invasive and inexpensive tool that can strengthen the diagnosis of Orf nodule and eliminate differential diagnoses. However, remains poorly understood in literature. Central ulceration, unstructured white areas and point vessels have been reported by Sonia Chavez-Alvarez et al.³ The Other dermoscopic aspects that we described were reported by Erhan Ayhan et al. Our series confirms all these dermoscopic aspects.³⁻⁵

Histology is interesting in deceptive or pseudo-tumoral forms or when history or clinical examination is not persuasive.⁶ Electron microscopy or PCR can be a diagnostic tool.¹ Pseudo-tumoral (in one of our patients) and disseminated immunosuppressed forms are described which may pose a differential diagnosis problem with milker's nodule (caused by paravacciniavirus), fish tank granuloma, pyogenic granuloma, keratoacanthoma, fungal infection, and cutaneous anthrax.⁶ Hence the interest of histology in these cases. Complications were described such as pain, bacterial superinfections, lymphangitis, and regional lymphadenitis.⁷

The treatment is often symptomatic; local care is advocated with the avoidance of manipulation to avoid self-infestation. what was done with us patients. Antibiotic therapy is indicated in case of surinfection (three of our patients). In chronic or pseudo-tumoral forms, several treatments can be used such as Imiquimod, Cidofovir antiviral, administered topically or intravenously, has also been used with positive results.^{5,8} Interferon-2b intra-lesional injections, along with oral acyclovir or interferon asystemically have been used in cases of "giant" orfin immunocompromised patients.⁹ Surgical management

is usually reserved for resistant cases with a shave excision helping to confirm the diagnosis and relieve pain or a distraught patient. Curettage and electrodesiccation are also indicated.⁷ Unfortunately our patient with pseudo-tumoral form was lost sight of. The spontaneous regression is done in a few weeks.¹

Conclusion

The diagnosis of Orf's nodule is based on the clinical and the notion of contact with sheep and goats. The knowledge of the religious practices and the customs of the doctor makes it possible to seek them during the interrogation in order to guide the diagnosis of this rare infection, and thus to avoid unsuitable care or unnecessary hospitalizations. Several clinical aspects are possible, some of which are misleading. Dermoscopy is a non-invasive tool that can strengthen diagnosis and eliminate differential diagnoses.

Conflicts of interest

The author declares that there is no conflicts of interests.

Acknowledgments

None.

Funding

None.

References

1. Patrice Bouree, Pascale Sarrand. L'orf, une zoonose virale fréquente mais mal connue. *Francophone Des Laboratoires*. 2016;483:63–66.
2. Seyed Sajjad Hasheminasab, Ali Mahmoodi, Parvin Mahmoodi, et al. Orf virus infection in human ecthyma contagiosum: a report of two cases in the West of Iran. *Virusdisease*. 2016;27(2):209–210.
3. Sonia Chavez-Alvarez, Dermoscopy of contagious ecthyma (orf nodule). *J Am Acad Dermatol*. 2016;74(5):e95–e96.
4. Handan Saçar et al. Investigation of the complications and incidences of orf disease during and after the Feast of the Sacrifice period. *Dermatologica Sinica*. 33(2015):191–195.
5. Erik De Clercq. Cidofovir in the treatment of poxvirus infections. *Antiiral Res*. 2002;55(1):1–13.
6. Dana Saade, Catherine Higham, Neelam Vashi. Boston, Massachusetts A case series of orf infection after the religious sacrifice feast Eid al-Adha. *JAAD Case Reports*. 2018;4(5):489–492.
7. Georgiades G, Katsarou A, Dimitroglou K. Human Orf (Ecthyma Contagiosum). *Journal of Hand Surgery: British and European Volume*. 2005;30(4):409–411.
8. De Clercq E. Clinical potential of the acyclic nucleosidephosphonates cidofovir, adefovir, and tenofovir in treatment of DNA virus and retrovirus infections. *Clin Microbiol Rev*. 2003;16(4):569–596.
9. Menglong Ran, Mingyang Lee, Jie Gong, et al., Oral Acyclovir and Intralesional Interferon Injections for Treatment of Giant Pyogenic Granuloma-Like Lesions in an Immunocompromised Patient With Human Orf. *JAMA Dermatol*. 2015;151(9):1032–1034.