MedCrave
Step into the World of Research
Journal of Cancer Prevention & Current Research

Case report

Open Access
CrossMark

Structural dedifferentiation of breast cancer arising within the major lactiferous ducts: imaging-histopathologic correlation in two fatal cases, part III

Abstract

Background: Imaging biomarkers, the mammographic appearance of the breast cancer subtypes, emerged during the development of breast imaging. Our research on correlative mammographic-large format thin and thick section histopathologic studies has shown that imaging biomarkers of breast cancers reflect the underlying histopathology and can reliably indicate the sites of tumour origin. Our ability to control the various subgroups of breast cancer largely depends upon which component of the glandular tissue each subtype originates from. The diffusely infiltrating breast cancers, despite the benefits of regular screening and modern therapeutic methods, cause most of the remaining breast cancer deaths. Prediction of long-term outcome in patients with these diffusely infiltrating breast cancers has been unsatisfactory using molecular biomarkers, both individually or combined into luminal and basal subtypes. Imaging biomarkers, easily reproducible in calcified diffuse breast cancer cases, can more accurately predict these patients' outcome.

Precis: The aim of our series of articles is to call for a re-evaluation of a misunderstood breast cancer subtype, a malignancy originating within the major lactiferous ducts. We have described three phases of its development, the 1st being an intraductal, *in situ* malignancy not demonstrable by current imaging methods. The 2nd phase is caused by neoductgenesis, in which branching, newly formed neoducts invade the surrounding parenchyma, a phase we have termed ductal adenocarcinoma of the breast, DAB. The 2nd phase involves a considerable structural change compared with the 1st phase. The 3rd phase is caused by further structural dedifferentiation in which the contents of the neoducts manage to escape through breaches in the neoduct wall, losing the ability to form ducts and instead can form invasive conglomerates. We have termed this final phase of the disease dedifferentiated DAB, ddDAB. Both DAB and ddDAB are capable of metastasizing to the axillary lymph nodes and distant organs. Appreciation of this complex disease progression could generate research for more successful control of this breast cancer subgroup, which currently has a high fatality rate. Central to improving these patients' outcome is an appreciation that both the 2nd and 3rd phases in the evolution of this disease subgroup are invasive cancers, and that their combination is responsible for their poor outcome.

Case description: Case 1 describes a 47-year-old woman with a self-detected, palpable thickening in the upper-outer quadrant of her left breast. Clinical breast examination and mammography both revealed pathologic axillary nodes. No tumour mass or microcalcifications were detected on the patient's previous screening mammograms and only vague signs at varying locations were seen with the retrospective use of an artificial intelligence (AI) algorithm. Histologic examination of the 14G core biopsy specimen showed invasive breast cancer. Mastectomy was performed followed by endocrine therapy. Microscopic examination of the surgical specimen revealed extensive, low-grade cancer cells in distended neoducts (DAB) adjacent to multiple invasive, dedifferentiated DAB foci. The remarkable feature of this case is that her pleural metastasis showed a histologic image that closely resembled the DAB (2nd phase) in the primary tumour, which the pathologist had diagnosed as DCIS. On the contrary, her liver metastases showed a histopathologic image comparable to the histology of the original ddDAB (3rd phase), diagnosed in her left breast five years earlier. The patient died from metastasizing DAB and ddDAB five years and four months after the first diagnosis and initiation of treatment.

Case 2. This 67-year-old woman presented with a self-detected small, firm tumour mass in the lower-outer quadrant of her left breast. Microscopic examination demonstrated the presence of invasive, dedifferentiated DAB (ddDAB) while the presence of the centrally located, short casting-type calcification indicated the presence of a neoduct (DAB) with central necrosis and amorphous calcification. The total extent of the combined ddDAB and the Grade 2 DAB was 23x13 mm. The patient was diagnosed with a malignant tumour in the left axillary tail 53 months following diagnosis and initiation of treatment. This tumour had the histologic features of the ddDAB diagnosed in her primary breast cancer. Three months later she was diagnosed with pathologic left axillary nodes having macro-metastases. The disease unfortunately progressed despite treatment, and an additional 32 months later liver metastases were diagnosed. Seven years and 3 months after diagnosis of a unifocal, 13x10 mm ddDAB associated with "DCIS", the patient died from metastasizing dedifferentiated DAB (ddDAB).

Conclusion: These case reports emphasize the harmful consequences of an outdated histopathologic terminology, which still holds that the newly formed duct-like structures, neoducts (DAB), the 2nd phase in the evolution of cancers originating within the major lactiferous ducts, are a supposedly low-risk *in situ* process. When these neoducts progress through structural dedifferentiation into the 3rd phase (ddDAB), the combination of these two invasive processes can be fatal at a surprisingly small tumour size.

Keywords: mammography, breast cancer neoducts, neoductgenesis, dedifferentiation of neoducts, imaging biomarkers

Volume 17 Issue 5 - 2026

László Tabár,[1] Peter B Dean,[2] Miklós Tarján[3]
[1]Department of Mammography, Falun Central Hospital, Sweden
[2]Department of Diagnostic Radiology, Faculty of Medicine, University of Turku, Finland
[3]Department of Clinical Pathology and Cytology, Falun Central Hospital, Sweden

Correspondence: László Tabár, Department of Mammography, Falun Central Hospital, Sweden

Received: September 15, 2026 | **Published:** November 12, 2026

©2026 Tabár et al. This is an open access article distributed under the terms of the Creative Commons Attribution License, which permits unrestricted use, distribution, and build upon your work non-commercially.

Copyright: ©2026 Tabár et al.

List of abbreviations: DCIS, ductal carcinoma *in situ*; DAB, ductal adenocarcinoma of the breast; ddDAB, dedifferentiated DAB; H&E, haematoxylin-eosin staining; IHC, immunohistochemical; MLO, mediolateral oblique projection; CC, cranio-caudal projection; ER, estrogen receptor; PR, progesterone receptor; HER2, human epidermal growth factor receptor 2; Ki-67, antigen Kiel 67; EGFR, epidermal growth factor receptor; GATA3, GATA binding protein 3; CK, cytokeratin staining; TTF-1, lung cancer and thyroid cancer marker; AI, artificial intelligence; Calretinin, a calcium-binding protein

Introduction

The persistent use of the term "DCIS" to describe mammographically detected breast cancers originating in the major lactiferous ducts hinders our efforts to better control this disease subgroup. It has six imaging biomarkers, the most prominent being the presence of fragmented casting-type calcifications on the mammogram.[1,2] The lack of improvement in long-term outcome of these cases in consecutive decades should alert physicians responsible for breast cancer care that the current management procedures are inadequate, because they are based upon the frequent assumption that "DCIS" is an innocent, truly *in situ* disease.[3,4] The published evidence documents the invasive nature of the neoducts (DAB) together with their subsequent dedifferentiation (ddDAB) to a potentially fatal disease, supporting the argument that these neoducts should not be dismissed as "*in situ*".[5-19]

First case

This 47-year-old woman was referred for assessment of a palpable, firm, diffuse thickening in the upper-outer quadrant of her left breast. At clinical breast examination she also had a palpable, pathologic axillary node in the left axilla. Neither the two previous screening mammograms nor an AI algorithm applied to the prior mammograms could detect a tumour mass or microcalcifications (Figure 1).

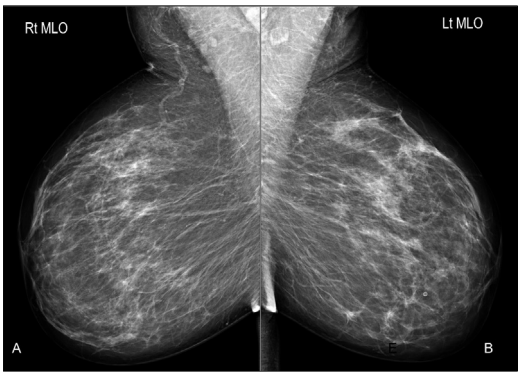

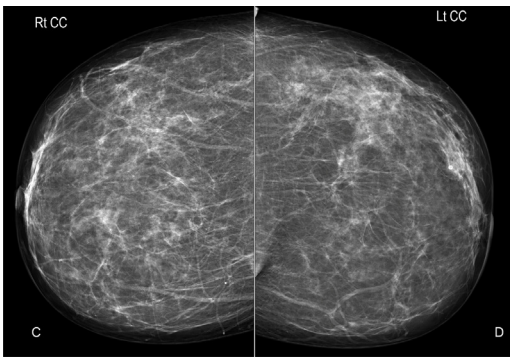



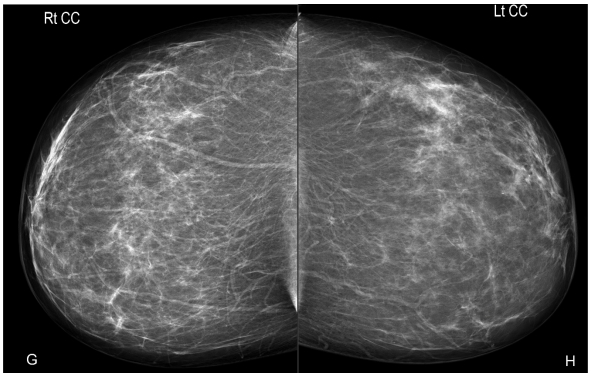

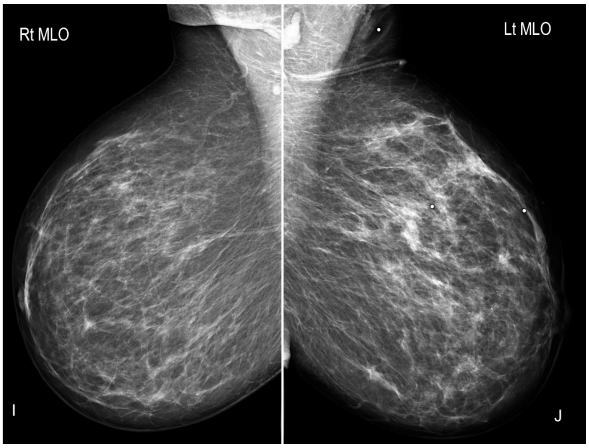

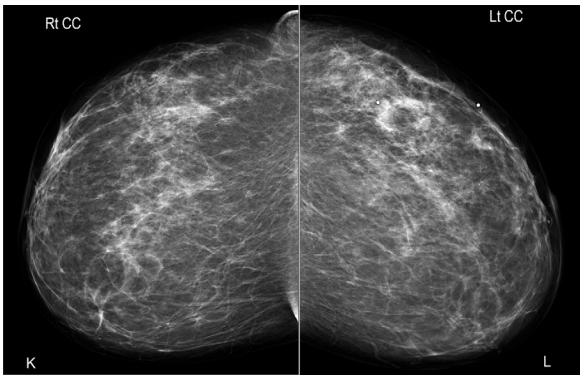

Citation: Tabár L, Dean PB, Tarján M. Structural dedifferentiation of breast cancer arising within the major lactiferous ducts: imaging-histopathologic correlation in two fatal cases, part III. *J Cancer Prev Curr Res*. 2026;17(4):167–175. DOI: 10.15406/jcpcr.2026.17.00624

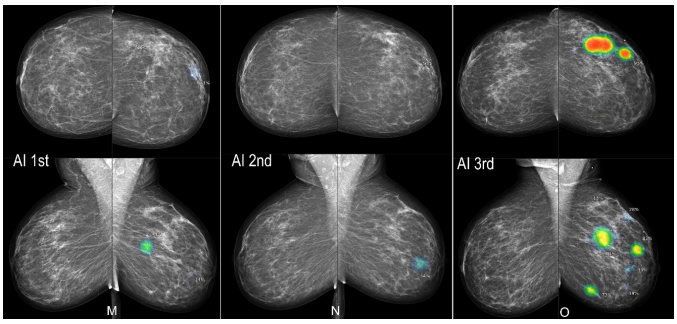

Figure 1 Two consecutive mammographic examinations (A-H) 19 months apart did not show a tumour mass or malignant type microcalcifications. Twenty months following the second examination the patient felt a diffuse, firm thickening in the upper-outer quadrant of her left breast. Clinical breast examination also revealed a pathologic lymph node in the left axilla. Lead pellet markers were placed over the palpable findings (I-L). The mammograms showed a non-specific asymmetric density located in most of the left upper-outer quadrant. No microcalcifications or tumour mass were demonstrable at this examination either. The AI algorithm showed only equivocal signs at various locations in the first two examinations (M,N), but detected a suspicious malignancy over a large region at the time when there was an extensive palpable finding at clinical breast examination (O).

14G core biopsy established the diagnosis of breast cancer. Following mastectomy, large format histopathology images showed a 48x40 mm low-grade cribriform DAB (official histopathology report: DCIS) associated with several small invasive dedifferentiated DAB foci (ddDAB) (official histopathology report: multifocal, well-differentiated invasive ductal carcinoma) (Figure 2).

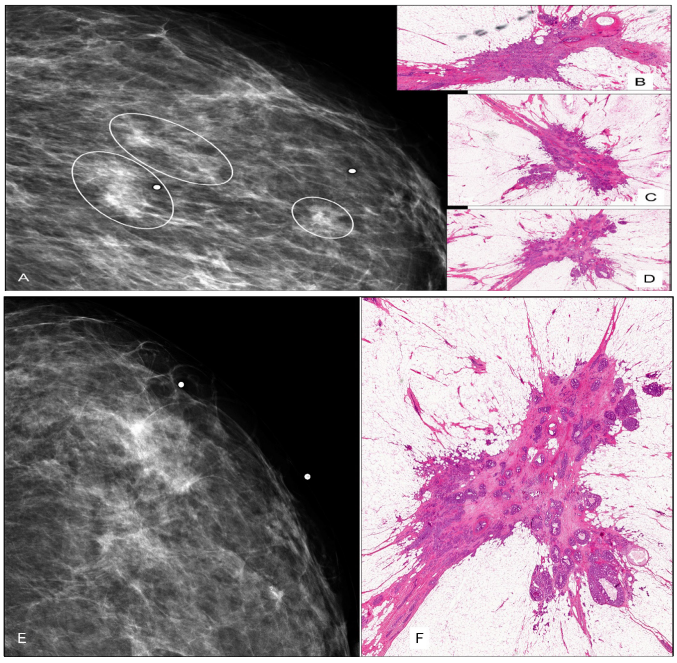

Figure 2 Microfocus magnification images in the left MLO (A) and CC (E) projections show subtle findings of asymmetric densities with ill-defined contours and no associated microcalcifications. Low-power large format histopathology (B-D,F) reveals three individual malignant tumours.

Intermediate-and higher-power histopathology shows neoducts (DAB) distended by low-grade cancer cells having predominantly cribriform tumour growth pattern combined with multifocal dedifferentiated DAB. Two axillary nodes had metastases similar to the cells seen in the dedifferentiated invasive ddDAB of the original breast cancer. The IHC biomarkers predicted a favourable outcome (Figure 3). The patient received post-mastectomy endocrine therapy.

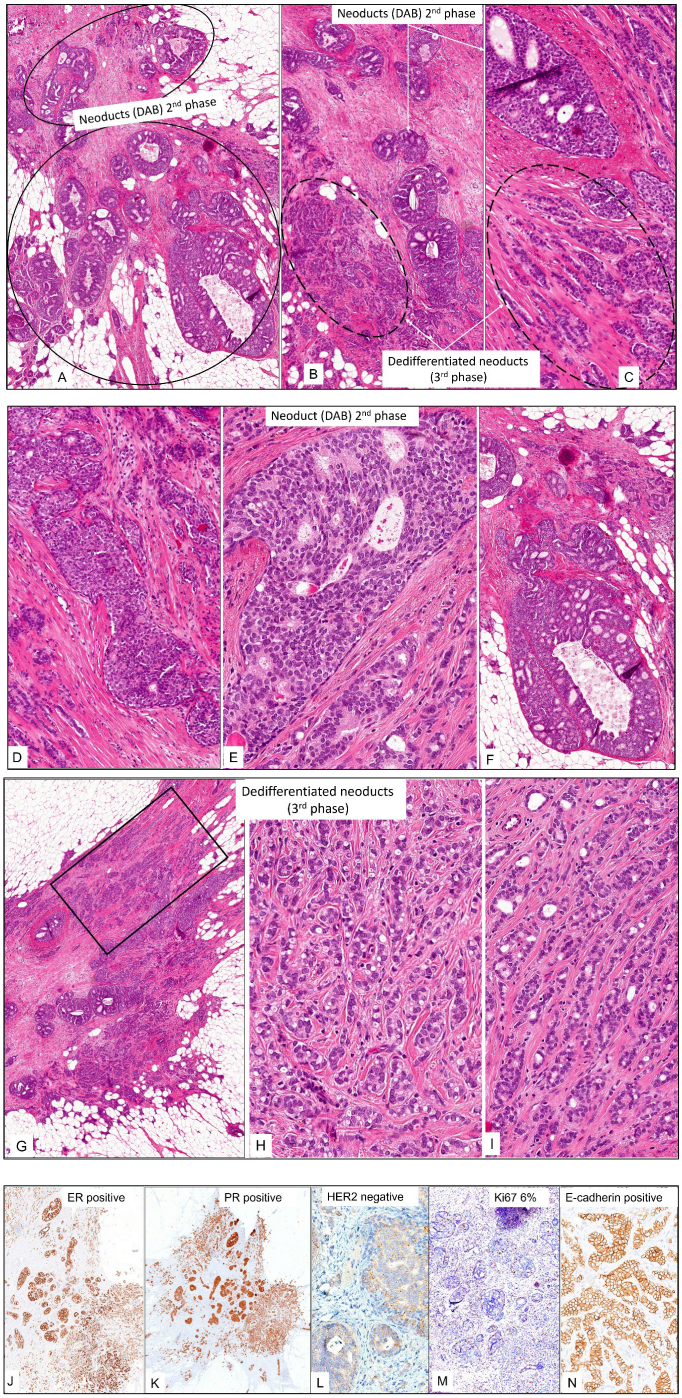

Citation: Tabár L, Dean PB, Tarján M. Structural dedifferentiation of breast cancer arising within the major lactiferous ducts: imaging-histopathologic correlation in two fatal cases, part III. *J Cancer Prev Curr Res.* 2026;17(4):167–175. DOI: 10.15406/jcpcr.2026.17.00624

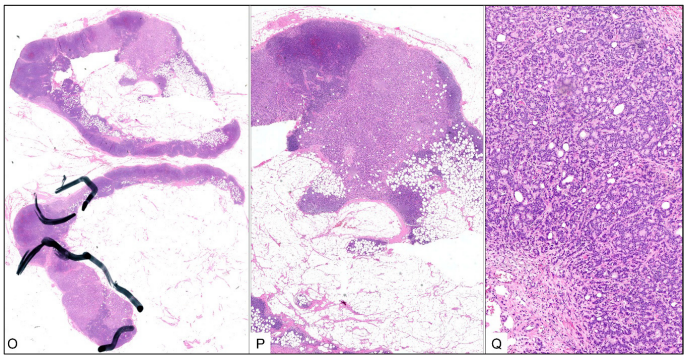

Figure 3 Large format histopathology images (A-I) illustrate numerous neoducts (DAB, 2nd phase) and multifocal invasive dedifferentiated DAB (3rd phase) adjacent to each other. The IHC biomarkers predicted a favourable long-term outcome: ER positive (J), PR positive (K), HER2 negative (L), 6% KI67 (M). E-cadherin positive (N) tumour. Two of the 14 surgically removed axillary lymph nodes (O-P) had multiple macro-metastases, the largest measuring 12 mm. Higher-power histology image of one of the metastases (Q) shows a striking similarity with the microscopic image of the ddDAB (H,I) in the breast cancer.

Official histologic diagnosis: Multifocal well differentiated invasive ductal carcinoma (13x10 mm, 12x11 mm, 7x5 mm) associated with Grade I-II predominantly cribriform DCIS in a region measuring 48x40 mm. IHC biomarkers: ER/PR positive, HER2 negative, Ki67 6%. CK 5/6, CK 14 and EGFR are negative. E-cadherin is positive. Massive LVI. pN 2/14 (12 mm macrometastasis).

Our interpretation: Multifocal Grade 1 invasive cancer of dedifferentiated neoducts type (ddDAB) (13x10 mm, 12x11 mm, 7x5 mm) associated with neoducts (DAB) distended by Grade I-II, predominantly cribriform cancer cells in a region measuring 48x40 mm. IHC biomarkers: ER/PR positive, HER2 negative, Ki67 6%. CK 5/6, CK 14 and EGFR are negative. E-cadherin is positive. Massive LVI. pN 2/14 (12 mm macrometastasis).

Follow-up: Twenty-three months after diagnosis and start of treatment the patient was diagnosed with pleural metastases. The similarity between the pleural metastasis and the "low grade DCIS" in the breast cancer is striking (Figure 4).

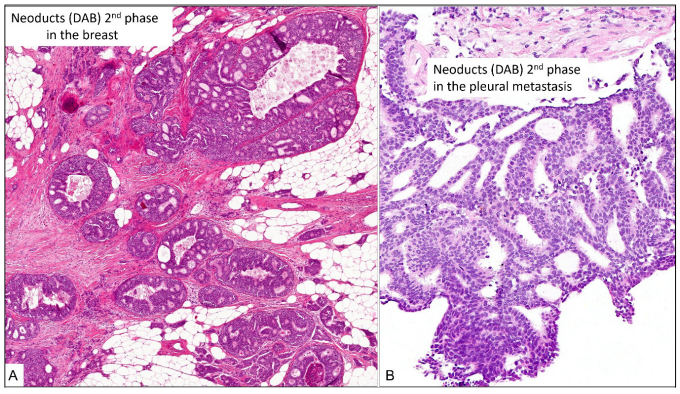

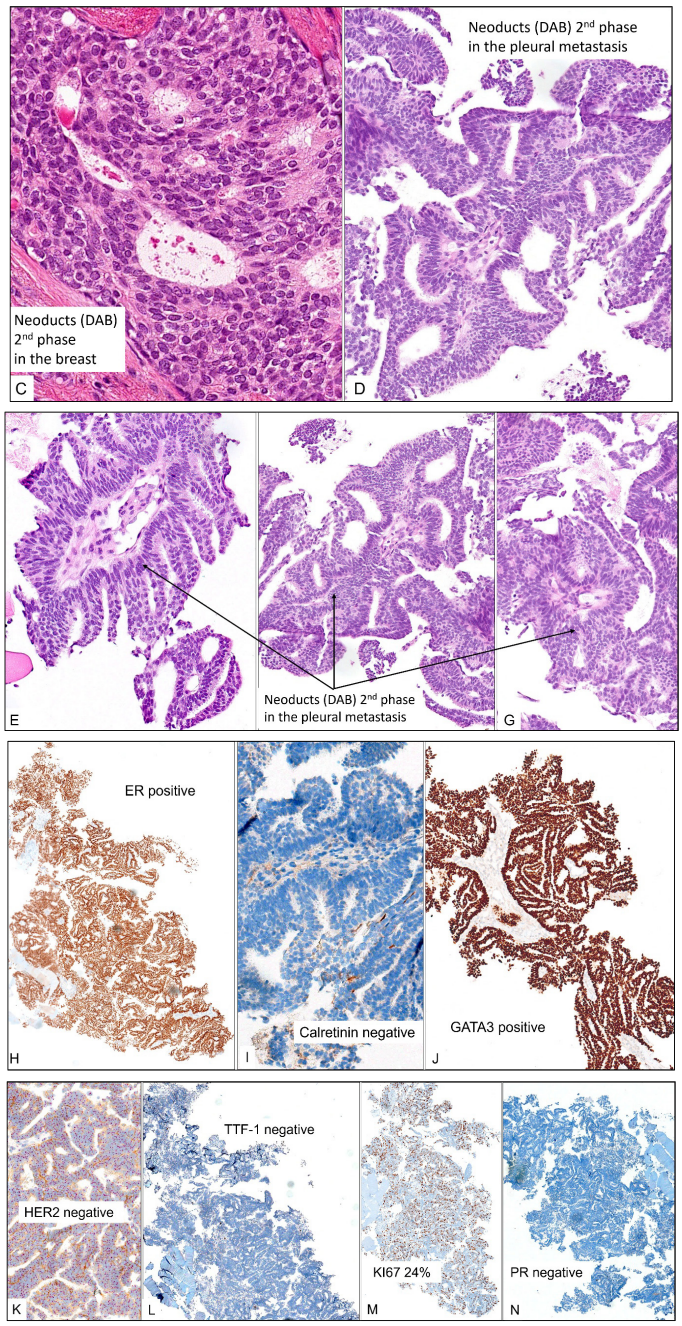

Figure 4 The tumour growth patterns of the primary breast cancer (A,C) and the pleural metastases (B,D-G) are nearly identical. In addition, the combination of positive ER (H), negative Calretinin (I) and positive GATA 3 staining (J) (a breast cancer marker), negative TTF-1 (L) (lung cancer and thyroid cancer marker) support the histologic diagnosis: the metastasis originates from breast cancer.

Follow-up: Five years and one month after diagnosis and initiation of treatment the patient developed liver metastases. The histologic images of the ddDAB in the breast and the liver metastasis were strikingly similar, a diagnosis supported by the IHC biomarkers (Figure 5).

Copyright: ©2026 Tabár et al.

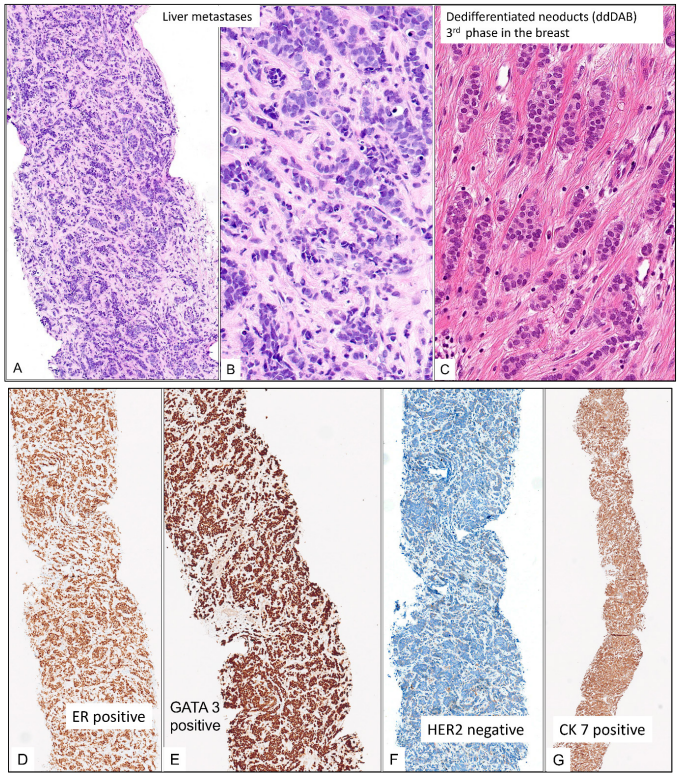

Figure 5 Low- and intermediate-power histopathology images (A,B) of the 14G core liver biopsy compared with the 14G core biopsy specimen of the breast cancer (C) diagnosed five years earlier. The immunohistochemical biomarkers gave support to the diagnosis that the metastases had their origin in the breast. ER positive (D), GATA3 positive (E), HER2 negative (F) and CK 7 (G) positive tumour.

Outcome: Although the low Ki67 and ER/PR positivity would conventionally predict a favourable outcome, five years and four months after diagnosis and initiation of treatment the patient died from metastasizing DAB and invasive dedifferentiated neoducts (ddDAB),

Second case

A 67-year-old woman detected a small, firm tumour mass in the lower-outer quadrant of her left breast. Two previous mammography examinations are shown for comparison. Microfocus magnification image, hand-held ultrasound and ultrasound-guided 14G core biopsy are shown in Figure 6. Mammographic-histopathologic correlation of the segmentectomy specimen (Figure 7).

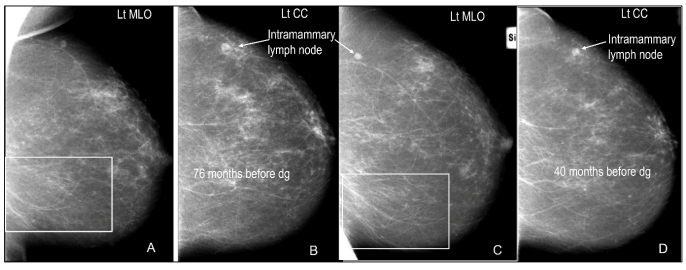

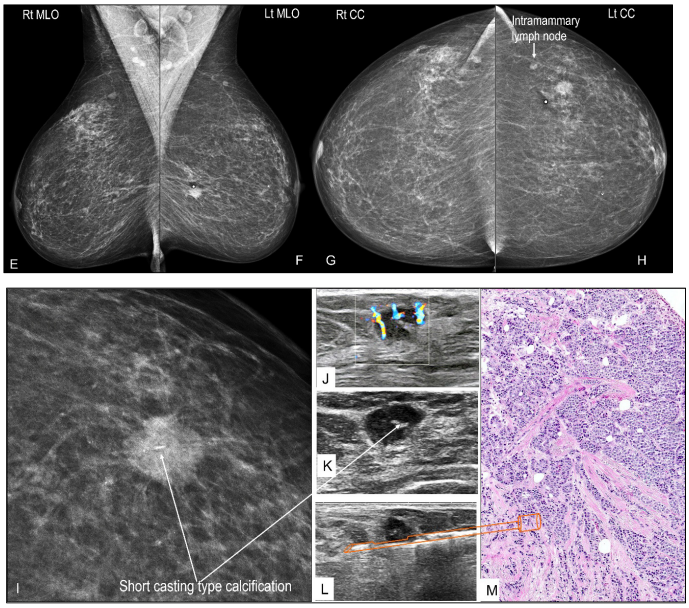

Figure 6 Left MLO (A,C) and CC (B,D) projections of screening mammograms 76 and 40 months, respectively, before diagnosis. The site where the carcinoma eventually developed is marked with rectangles; neither of the previous examinations had any abnormality in that region. At the time of diagnosis (E-H) there was a 13 mm solitary tumour mass in the outer-lower quadrant, eight cm deep to the left nipple. Microfocus magnification (I) and hand-held US (J-L) of the tumour show a microlobulated, ill-defined tumour mass with a single casting type calcification in the central portion of the tumour. Ultrasound Doppler (J) shows a rich blood supply to the tumour. Ultrasound guided 14G core biopsy (L). Intermediate-power histopathology image of the core biopsy specimen (M): invasive dedifferentiated DAB (ddDAB).

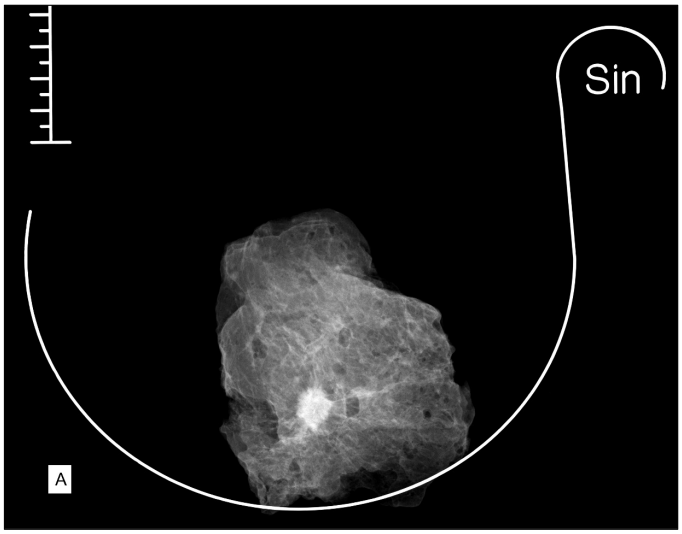

Citation: Tabár L, Dean PB, Tarján M. Structural dedifferentiation of breast cancer arising within the major lactiferous ducts: imaging-histopathologic correlation in two fatal cases, part III. *J Cancer Prev Curr Res*. 2026;17(4):167–175. DOI: 10.15406/jcpcr.2026.17.00624

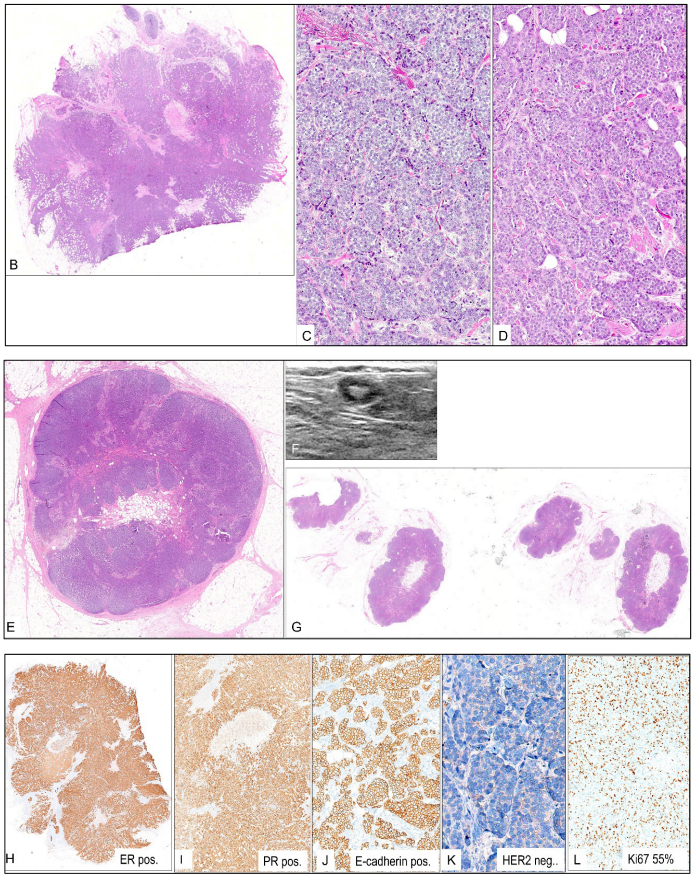

Figure 7 Segmentectomy specimen radiograph (A). Low-(B) and intermediate-power (C,D) histopathology images of this invasive, structurally dedifferentiated cancer. At the time of surgery, the patient had no axillary lymph node metastases (E-G). Immunohistochemical biomarkers: the tumour is ER (H) and PR (I) positive, E-cadherin positive (J), HER2 negative (K), Ki67: 55% (L). CK 5/6, CK 14, EGFR negative (not basal-like).

Official histopathology report: 13x10 mm invasive, poorly differentiated ductal carcinoma associated with Gr2 DCIS with solid and cribriform tumour growth patterns. Total disease extent: 23x13 mm. IHC biomarkers: ER/PR positive, HER2 negative, Ki67 55%, E-cadherin positive, CK 5/6, CK 14, EGFR negative (not basal-like). No LVI. Perivascular infiltration. pN 0/1.

Our interpretation of the microscopic examination: 13x10 mm invasive, dedifferentiated DAB (ddDAB) associated with Gr2 neoducts (DAB) with solid and cribriform tumour growth patterns. Total disease extent: 23x13 mm. IHC biomarkers: ER/PR positive, HER2 negative, Ki67 55%, E-cadherin positive, CK 5/6, CK 14, EGFR negative (not basal-like). No LVI. Perivascular infiltration. pN 0/1.

Follow-up: 53 months later the patient presented with a palpable tumour in the axillary tail of her left breast. Four consecutive mammographic examinations are shown for comparison (Figure 8).

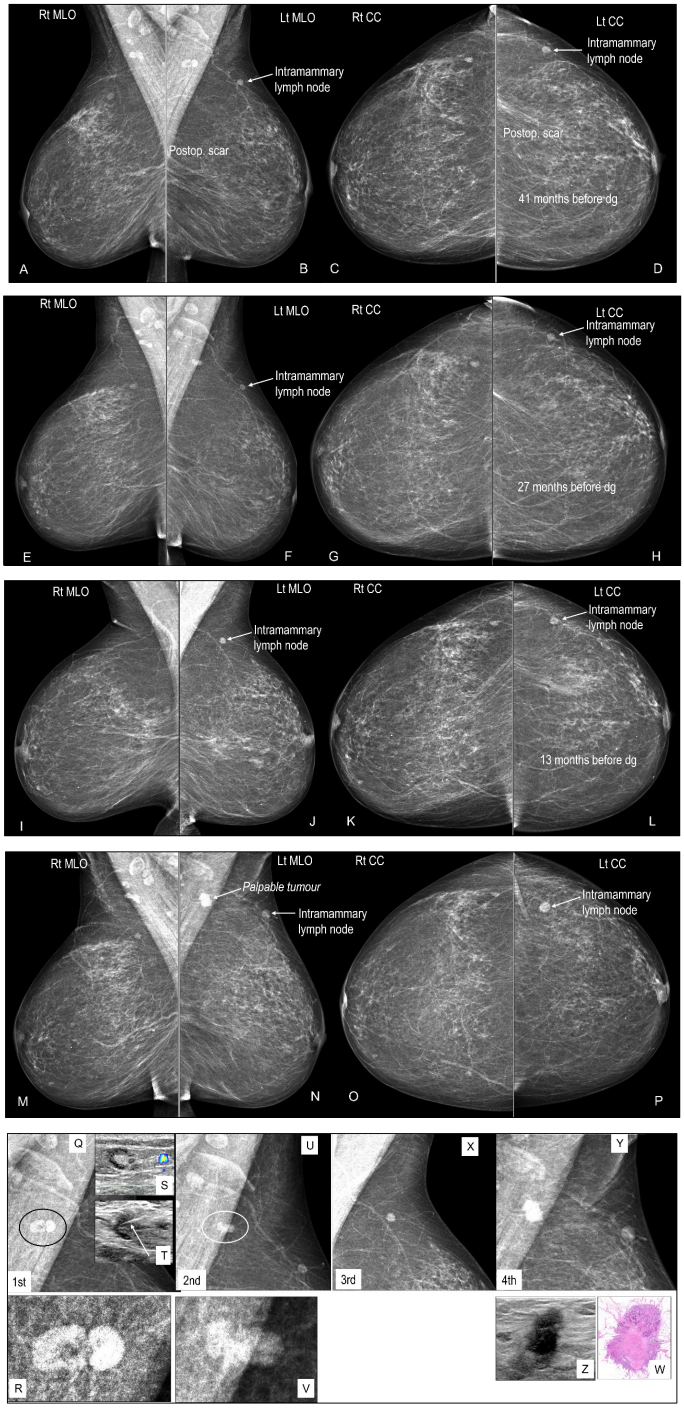

Figure 8 Four consecutive mammographic examinations with 13 month (A-D), 13 month (E-H), 14 month (I-L) and 13 month (M-P) intervals after diagnosis and initiation of treatment. At the fourth examination (M-P) the patient felt a hard lump in the axillary tail of the left breast. Both the ill-defined tumour mass as well as the pathologic intramammary lymph node (which had been normal at each previous examination) are imaged on the mammograms. A collage of the four consecutive examinations (Q,U,X,Y) shows image details of the region where the cancer eventually develops. At the first follow-up examination after surgery (Q,R) the left low axillary lymph nodes were examined with ultrasound (S). Ultrasound-guided fine needle aspiration biopsy was performed (T) on one of these nodes with no malignancy detected. Thirteen months later (U,V) the encircled oval density was considered to be a summation of two lymph nodes, especially because the fine needle aspiration biopsy did not show malignant cells at the prior examination. The site of the

Citation: Tabár L, Dean PB, Tarján M. Structural dedifferentiation of breast cancer arising within the major lactiferous ducts: imaging-histopathologic correlation in two fatal cases, part III. *J Cancer Prev Curr Res*. 2026;17(4):167–175. DOI: 10.15406/jcpcr.2026.17.00624

palpable tumour in the axillary tail was outside the field of view in the left MLO mammogram at the third examination (X), while the two prior examinations revealed only normal lymph nodes. Fourteen months later the patient felt a hard lump in the axillary tail of her left breast, prompting mammography (Y), hand-held ultrasound (Z) and low-power histopathology (W) of the tumour.

Imaging workup of the findings and microscopic examination of the 14G core biopsy specimen are shown in Figure 9.

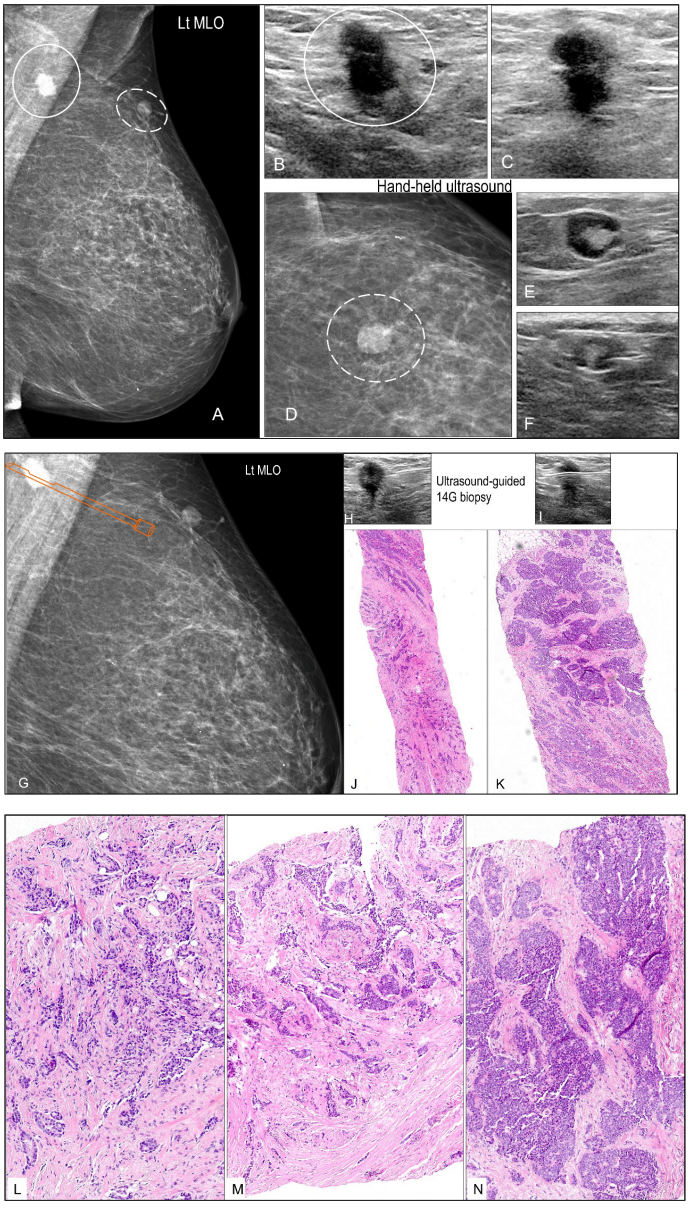

Figure 9 Left MLO projection (A) with the palpable tumour within the solid oval line and the pathologic intramammary lymph node within the dashed circle. Ultrasound images of the tumour (B,C), the mammogram (D), and ultrasound images (E.F) of the pathologic intramammary lymph node. Microfocus magnification of the left axillary tail (G) showing both the enlarged tumour and the pathologic lymph node. Ultrasound-guided 14G core biopsy (H,I) of the tumour localized in the left axillary tail. Low to higher-power histopathology images of the 14G core biopsy specimen (J-N) demonstrate Grade 3 invasive, dedifferentiated DAB (ddDAB). The tumour was considered by the pathologist to be a metastasis of the breast cancer diagnosed 53 months earlier.

Preoperative wire localization of the palpable tumour and the intramammary lymph node is followed by the histologic workup of the findings (Figure 10).

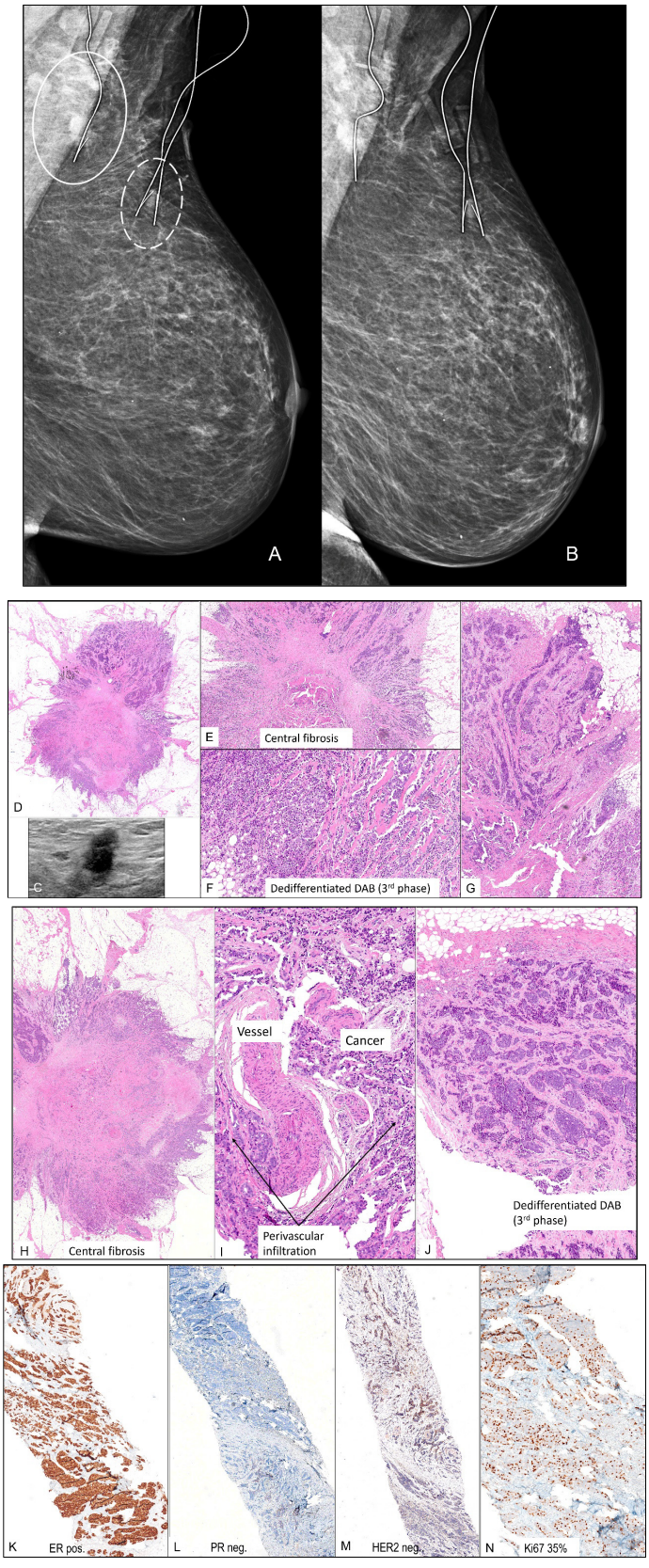

Figure 10 Left MLO projections (A,B). Preoperative wire localization of the palpable tumour and the pathologic intramammary lymph node. Ultrasound image correlated with low-power histopathology image of the tumour (C,D). Intermediate and higher-power histopathology images (E-J) illustrate central fibrosis surrounded by viable, dedifferentiated cancer cells at the periphery.

Citation: Tabár L, Dean PB, Tarján M. Structural dedifferentiation of breast cancer arising within the major lactiferous ducts: imaging-histopathologic correlation in two fatal cases, part III. *J Cancer Prev Curr Res.* 2026;17(4):167–175. DOI: 10.15406/jcpcr.2026.17.00624

Perivascular infiltration by cancer (I). Immunohistochemical biomarkers: the tumour is ER (K) positive, PR (L) negative, HER2 (M) negative, Ki67: 35% (N).

Follow-up: Three months after surgery of the invasive tumour in the left axillary tail, three pathologic axillary lymph nodes were removed surgically. Two of them had macro-metastases (13x10 mm and 11x10 mm) at microscopic examination (Figure 11).

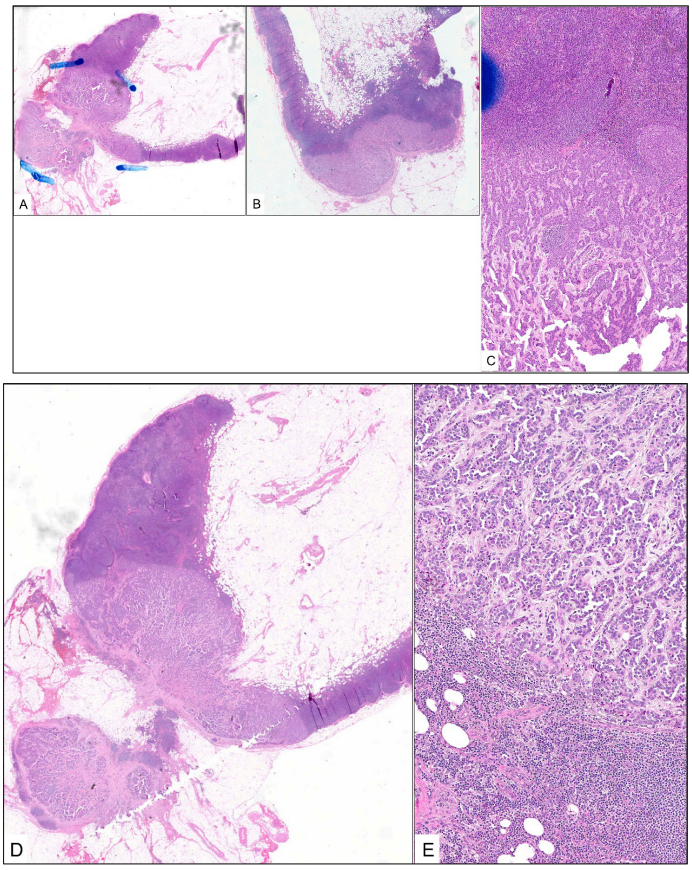

Figure 11 Invasive dedifferentiated DAB (ddDAB) occupies a large portion of the two pathologic axillary lymph nodes (A-E).

Follow-up: 32 months later the patient was diagnosed with liver metastases (Figure 12).

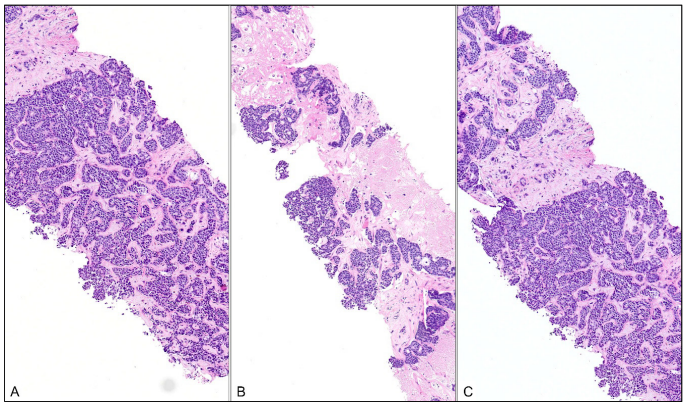

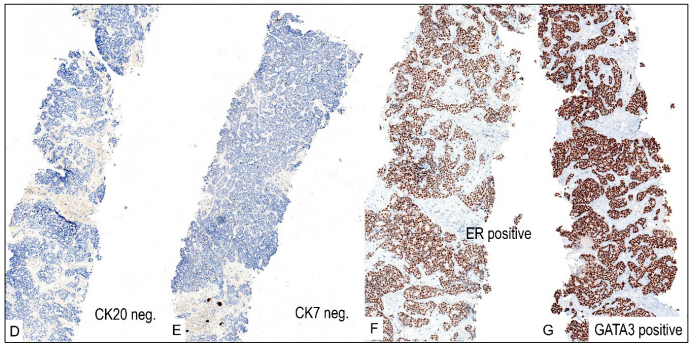

Figure 12 Histologic examination of the 14G core biopsy specimen (A-C) (H&E staining) of the liver shows extensive metastases similar to the invasive, dedifferentiated DAB (ddDAB) in the breast. Both the microscopic examination and the immunohistochemical biomarkers (D-G) (positive ER and GATA3 staining) indicate that the origin of the metastases is the breast cancer diagnosed seven years and three months earlier.

Outcome: Seven years and three months after the first diagnosis, the patient died from metastasizing invasive, dedifferentiated DAB (ddDAB).

Discussion

These two cases provide excellent examples showing DAB and ddDAB adjacent to each other, a phenomenon resulting from the progression of the 2nd phase to the 3rd phase.[3] As Willis wrote in 1953, "Invasive tumours may develop by escape of previously intra-ductal growth from their duct confines."[20] The prognostic reliability of IHC biomarkers in diffuse breast cancers originating in the major lactiferous ducts has recently been brought into question.[21] The fatal Case 1 reported here was an ER/PR positive, HER2 negative tumour with 6% KI67 proliferation index, predicting a favourable outcome. On the other hand, the IHC biomarkers were useful in both reported cases to support the histopathologic diagnosis of breast cancer as the cause of death.

Conclusion

Our recent publications focus on fatal breast cancer cases initially diagnosed as extensive "DCIS" associated with small invasive carcinoma foci.[1-4] The outcome of these cases is at odds with the currently used TNM staging system that considers the tumour burden to be the largest single invasive focus. The term "DCIS" is a misnomer when it is used to describe cancers originating in the major ducts, since these are duct forming invasive carcinomas (DAB), the 2nd phase according to our proposed three-step evolution of these cancers. Our view is that there are two invasive carcinomas in these cases, and the tumour burden should be assessed according to the combined tumour extent, including both the 2nd and 3rd phase of the evolution described above. Appreciation of the invasive nature of the neoducts (2nd phase) is needed instead of using the term "DCIS", since the combined effect of DAB and ddDAB gives a more realistic prediction of the patient outcome and greatly assists in patient management.[1-4,18,19]

Acknowledgements

The authors are greatly indebted to Professor F. Lee Tucker for his contribution to the conception of the process of structural dedifferentiation. Special thanks to Ms. Helena Hermelin, the leader of the Research Laboratory at Falun Central Hospital, for high-quality scanning the histopathology glass slides and organizing the research

archive. This work has been supported by funding from the American Cancer Society through a gift from the Longaberger Company's Horizon of Hope® campaign (Project NHPDCSGBR-GBRLONG).

Conflicts of interest

The authors declare that they have no competing interests.

References

1. Tabár L, Dean PB, Chen TH, et al. Imaging biomarkers are key to recognizing fatal breast cancers arising in the major ducts. *Eur J Radiol*. 2026;195:112564.
2. Tabár L, Dean PB, Tarján M. A specific subgroup of DCIS of the breast cannot be an in situ disease when its structure dominates the distant metastases: a case report. *J Cancer Prev Curr Res*. 2025;16(6):157–159.
3. Tabár L, Dean PB, Tucker FL, et al. Neoduct dedifferentiation is associated with poorer breast cancer-specific survival. *Eur J Radiol*. 2026;205:223295.
4. Tabár L, Dean PB, Tarján M. Structural dedifferentiation of breast cancer arising within the major lactiferous ducts: imaging-histopathologic correlation in two fatal cases. *J Cancer Prev Curr Res*. 2026;17(4):139–147.
5. Sirtori C, Talamazzi F. Carcinoma intraduttale della mammella non e' mai un carcinoma in situ [The intraductal carcinoma of the breast is never a carcinoma in situ]. *Tumori*. 1967;53(6):641–644.
6. Cowen PN, Bates C. The significance of intraduct appearances in breast cancer. *Clin Oncol*. 1984;10(1):67–72.
7. Lee AH, Telfer TP, Millis RR. Metastatic breast carcinoma with appearance resembling micropapillary ductal carcinoma in situ. *J Clin Pathol*. 1995;48(4):380–382.
8. Abecia Martínez EI, Sanromán AC, Leon L, et al. Misleading images of ductal carcinoma in situ: 4 lymph nodes with metastasis. *Rev Esp Patol*. 2023;56(4):252–260.
9. Barsky SH, Doberneck SA, Sternlicht MD, et al. 'Revertant' DCIS in human axillary breast carcinoma metastases. *J Pathol*. 1997;183(2):188–194.
10. Tabár L, Chen HH, Duffy SW, et al. A novel method for prediction of long-term outcome of women with T1a, T1b, and 10-14 mm invasive breast cancers: a prospective study. *Lancet*. 2000;355(9202):429–433.
11. Thurfjell E, Thurfjell MG, Lindgren A. Mammographic finding as a predictor of survival in 1-9 mm invasive breast cancers, worse prognosis for cases presenting as calcifications alone. *Breast Cancer Res Treat*. 2001;67(2):177–180.
12. Zunzunegui RG, Chung MA, Oruwari J, et al. Casting-type calcifications with invasion and high-grade ductal carcinoma in situ: a more aggressive disease? *Arch Surg*. 2003;138(5):537–540.
13. Peacock C, Given-Wilson RM, Duffy SW. Mammographic casting type calcification associated with small screen-detected invasive breast cancers: is this a reliable prognostic indicator? *Clin Radiol*. 2004;59(2):165–170.
14. Tabar L, Chen HH, Yen MF, et al. Mammographic tumor features can predict long-term outcomes reliably in women with 1–14mm invasive breast carcinoma. *Cancer*. 2004;101(8):1745–1759.
15. Kordek R. Ductal carcinoma in situ-like structures in metastatic breast carcinoma. *Pathol Res Pract*. 2005;200(11-12):831–834.
16. Tabár L, Tot T, Dean PB. *Breast Cancer: Early Detection with Mammography, Casting Type Calcifications: Sign of a Subtype with Deceptive Features*. Thieme; 2007.
17. Pervez S, Khan H. Infiltrating ductal carcinoma breast with central necrosis closely mimicking ductal carcinoma in situ (comedo type): a case series. *J Med Case Rep*. 2007;1:83.
18. Tabár L, Dean PB, Tucker FL, et al. Breast cancers originating from the major lactiferous ducts and the process of neoductgenesis: Ductal Adenocarcinoma of the Breast, DAB. *Eur J Radiol*. 2022;153:110363.
19. Tabár L, Dean PB, Tucker FL, et al. Imaging biomarkers of breast cancers originating from the major lactiferous ducts: Ductal adenocarcinoma of the breast, DAB. *Eur J Radiol*. 2022;154:110394.
20. Willis RA. *Pathology of Tumours*. 2nd edn. Butterworth; 1953:237.
21. Tabár L, Dean PB, Tucker FL, et al. Imaging biomarkers are underutilised but highly predictive prognostic factors for the more fatal breast cancer subtypes. *Eur J Radiol*. 2023;166:111021.