

# NK/T Cell Lymphoma - A Case Report and Literature Review

## Abstract

We present here the case of an 87 year old Caucasian female who complained of nasal tumour causing partial nasal obstruction without bleeding. The diagnosis nasal T/NK cell lymphoma was established by immunohistochemistry. The case was diagnosed as stage IE lymphoma because no other site was involved. The patient was treated using 6-15MeV linear accelerators at 2 Gy per daily fraction for a total dose of 44 Gy. The nasal T/NK cell lymphoma is a rare, special entity of nonhodgkin lymphomas and is known to be very aggressive in nature. The choice of treatment depends upon the stage of the lymphoma. In the initial stages locoregional radiotherapy alone or combined with chemotherapy is recommended. For the stage III/ IV NK/T Cell lymphomas combined modality therapy consisting of high-dose chemotherapy followed by auto-PBSC can be an alternative. In short, a high index of clinical suspicion is the key required, in order to reach early diagnosis that could open the doors of treasure i.e. improved disease outcome.

**Keywords:** Nasal NK/T cell lymphoma; Immunohistochemistry; Tumour; Nasal congestion

## Case Report

Volume 5 Issue 1 - 2016

**Piyush Vyas<sup>1</sup>, Seema Vyas<sup>2</sup>, Brygida Zawadzka<sup>2</sup>, Anna Danek<sup>2</sup>, Grażyna Bońkowska<sup>2</sup>, Ania Słoniewska<sup>2</sup> and Ania Skowrońska Gardas<sup>2</sup>**

<sup>1</sup>Department of Hematology, Oncology and Internal Medicine, Medical University of Warsaw, Poland

<sup>2</sup>Maria Skłodowska Curie Memorial Institute - Centrum Oncology, Poland

**\*Corresponding author:** Seema Vyas, Department of Teleradiotherapy, Maria Skłodowska Curie Memorial Institute - Centrum Oncology, Warsaw, Poland, Email: [vyas\\_piyush20@yahoo.co.in](mailto:vyas_piyush20@yahoo.co.in)

**Received:** April 27, 2016 | **Published:** May 18, 2016

## Case Report

A Caucasian 87 year old woman was referred to department of Teletherapy, Maria Skłodowska Curie Centre and Institute of Oncology for the radical treatment of T cell lymphoma of nasal type. The patient noticed about 8 months ago, a small mass on the right side of the nasal vestibule that caused partial nasal obstruction. She was referred to the surgical outdoor by her general practitioner where she underwent surgical resection of tumour. Postoperatively, after about 3 weeks she observed reappearance of the tumour which aggressively increased in size resulting in about 3 cm cauliflower shaped irregular mass, this time involving the left vestibule and the nasal septum.

Patient at the time of admission exhibited extensive nasal crusting with clinical symptoms like nasal congestion, pain on touching without bleeding, sensation of increased pressure in the nose. There had been no trauma prior to her complaints and she had no allergies. There were no history of substance abuse and no other general complaints. Patient had a history of travel to U.S.A 5 years back.

ENT examination revealed an extensive amount of friable granular tissue along the left side of the nasal vestibule with infiltration of nasal septum, columella and skin of the nose. There were no other abnormalities detected during ENT and general physical examination and laboratory blood tests were as shown in below.

Laboratory findings on admission and on discharge (in brackets)

### Peripheral blood

White blood cells 6400/L (6600), Red blood cells  $4.95 \times 10^6$  (4.86), Hemoglobin 14.1g/ dl (13.7), Platelets  $26.7 \times 10^4/L$  (14.5), Hematocrit 43.1 (42.2)

## Biochemical data

Na 145mEq/L (142), K 4.4mEq/L (4.5), Blood urea nitrogen 28 mg/dl (30), Creatinine 0.8 mg dl (0.64), Uric acid 3.6 mg/dl (3.8), Aspartate transaminase 25U/L (28), Alanine aminotransferase 23U/L (20), Lactate dehydrogenase 629 U/L (655), Alkaline phosphatase 104 (92), GGTP 21 (21), Bilirubin 8.8 (14), Glucose 89 (87), Total protein 73, D-dimer 817

Immunohistochemical staining was consistent with nasal T cell lymphoma. It showed that the infiltrate consisted of T cells (CD3, CD30 positive). The B cell markers CD 20 were negative. Cytotoxic markers like CD56 were negative. Anticytokeratin antibodies which serve to identify micrometastases to lymph nodes were also negative (CKAE1/CKAE3 negative). Ki67 was + in 80% cells showing very aggressive nature of the tumour. CT of the head and neck revealed a localized mass over the nasal columella infiltrating nasal vestibules bilaterally without any involvement to the lymph nodes. CT of the chest to pelvis was negative for tumour involvement. Accordingly, the patient was diagnosed as stage IE nasal T cell lymphoma

We qualified patient for the radical treatment with radiotherapy alone without preceding CHOP (Cyclophosphamide, doxorubicin, Vincristine and Prednisolone) regimen. IMRT was delivered using 6-15MeV linear accelerators at 2 Gy per daily fraction for a total dose of 44 Gy. The radiation therapy alone resulted in CR (complete remission). During treatment patient had experienced dryness of nasal cavity resulting in severe nasal crusting. Patient was treated with vitamin E nasal drops and ointment. She also had inflammatory changes in buccal cavity and oropharyngeal fungal infection. Accordingly was treated with antifungal and antibacterial preparations.

CT of nasopharynx (with contrast) which was done at the end of treatment revealed that we had achieved complete remission

of the lymphoma. According to the recommendations of NCI post follow up investigations i.e. routine blood tests, ENT examination and follow up CT of nasopharynx were done every 4 weeks in our institute. Unfortunately patient died after four years due to distant metastasis post palliative chemotherapy.

## Discussion

Non Hodgkin's lymphoma (NHL) is a heterogeneous group of malignancies of the lymphoid system characterized by an abnormal clonal proliferation of Bcells, Tcells or both. Presented here is a rare entity of NHL- the Nasal NK/Tcell lymphoma. Nasal natural-killer- (NK)/T-cell lymphoma is an extranodal lymphoma of the nasal cavity and nasopharynx. This disease for a number of years was believed to be caused by uncertain cause but is now believed to represent a T cell lymphoma. It has been named differently in the past as lethal midline granuloma, midline malignant reticulosis, polymorphic reticulosis, angiocentric lymphoma (in the revised European-American (REAL) classification), extranodal NK/T-cell lymphoma, nasal and nasal type (in the new World Health Organization classification). However for staging NHL Ann arbor classification is applied routinely [1-5].

The prevalence of nasal lymphomas is estimated at 0.17-1.5% for all non-Hodgkin's lymphomas (NHL), of which 45% are thought to be of origin from NK/T cell Lymphomas of nasal cavity are seen more commonly in Asia (China, Hong Kong, Taiwan), Mexico, and in native population in Peru. A consistent association with EB virus infection is demonstrated in the lymphoma cells, suggesting a probable pathogenic role of EBV. The disease affects men more than women. The age of incidence is generally in the fifth decade. It is characterized by poor prognosis with an aggressive clinical course involving unrelenting ulceration and necrosis. Extra nodal sites invariably involved include nose, palate, upper airway, GIT and skin). Disease appears to spread locally with only a small predilection for regional or systemic failure. International Prognostic index developed by 16 different institutes of U.S., Europe and Canada is used which includes adverse factors like age  $\geq 60$  years, Ann Arbor stage III/IV, serum LDH level above normal, number of extranodal sites of involvement  $\geq 2$ , performance status  $\geq$  ECOG 2 or equivalent [2,3,6,7]. Treatment approaches include Radiotherapy alone, chemotherapy alone or the combined modality treatment with the two different sequence of Chemotherapy which could prove beneficial in these cases i.e. either chemotherapy after Radiotherapy or alternate scheduling of RT and Chth in contrast to induction chemotherapy followed by RT in other head and neck lymphomas. High dose Chemotherapy is indicated for patients with stage III-IV and patients with local recurrence or systemic tumor spread after locoregional radiotherapy. Intrathecal methotrexate can be considered in the case of paranasal sinus and orbit involvement to decrease the risk of leptomeningeal spread [1,2,8]. In a recent study L-asparaginase was an effective option to improve the chemotherapeutic efficacy on NK/T cell lymphoma, nasal type, and is worth further study. There have been some reports that high dose Chth and autologous or allogeneic bone marrow transplantation has been successful for NK/T-cell lymphomas, and recently Sasaki et al. [9] reported that double auto-PB SCT achieved CR in a therapy resistant nasal NK/T-cell lymphoma [5,8,10] (Figure 1 & 2).

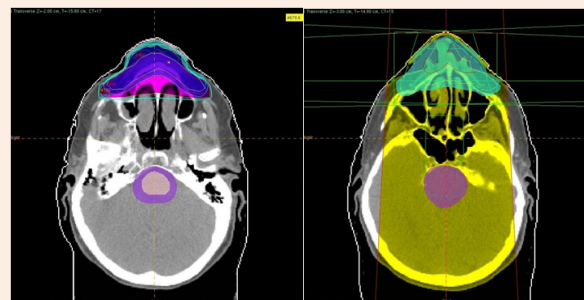


Figure 1: 3D-CRT plan.

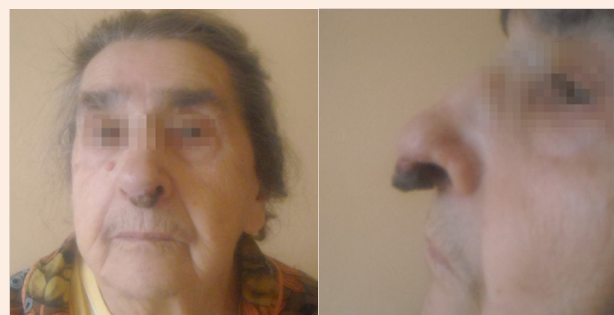

Figure 2: Exophytic NK lymphoma at nasal vestibulum at presentation.

## Conclusion

Extranodal NK/T cell nasal-type pursues an aggressive clinical course with poor prognosis. Several recent clinical investigations have reported 5-year overall survival (OS) rates ranging from 36% to 49.5% for patients with stage I-IV disease. Up to now, optimal treatment strategies have not been fully recognized. Although radiotherapy and chemotherapy are both effective for NK /T cell nasal -type lymphoma, approximately 50% of the patients still fail in locoregional recurrences or systemic disease progression. Thus, an innovative therapy is urgently needed. However, immuno-histochemical staining has enabled a better estimation of disease course and prognosis but despite these improvements high index of clinical suspicion is imperative to ensure early diagnosis and ultimately improve disease outcome [11-15].

## References

1. Dalla-Favera R, Gaidano G (2001) Cancer: principles and practice of oncology. In: DeVita VT, et al. (Eds.), (6<sup>th</sup> edn), Lippincott Williams & Wilkins, Philadelphia, USA, pp. 2295.
2. Halperin EC, Perez CA, Luther WB (2008) Perez and Brady's Principles and Practice of Radiation Oncology. (5<sup>th</sup> edn), Lippincott Williams & Wilkins, Philadelphia, USA.
3. Armitage JO (2005) Staging Non-Hodgkin lymphoma. *CA Cancer Clin* 55(6): 368-376.
4. Kato T, Tanabe J, Kanemoto M, Kobayashi C, Morita S, Karahashi T (2009) A case of extranodal NK/T-cell lymphoma, nasal type mimicking typical manifestations of adult-onset Still's disease (AOSD) with hemophagocytic syndrome: diagnostic consideration between malignant lymphoma without lymphadenopathy and AOSD. *Modern Rheumatology* 19(6).

5. Yong W, Zheng W, Zhu J, Zhang Y, Wang X, et al. (2009) L-Asparaginase in the treatment of refractory and relapsed extranodal NK/T-cell lymphoma, nasal type. *Ann Hematology* 88(7): 647-652.
6. Katsounis P, Alexopoulou A, Dourakis SP, Smyrnidis A, Marinos L, et al. (2008) An extranodal NK/T cell lymphoma, nasal type, with specific immunophenotypic and genotypic features. *Int J hematol* 88(2): 202-205.
7. Ketharanathan N, Kipshagen PJ, Vasmel W, Barbé E, Vries N (2008) T/NK cell lymphoma presenting as a "blocked nose". *Eur Arch Otorhinolaryngol* 265(9): 1131-1134.
8. Chan JK, Jaffe E, Ralfkiaer E (2001) Extranodal NK/T cell lymphoma, nasal type. In: Jaffe ES, et al. (Eds.), *Tumours of haematopoietic and lymphoid tissues*. IARC, Lyon, France, pp. 204-2074.
9. Sasaki M, Matsue K, Takeuchi M, Mitome M, Hirose Y (2000) Successful treatment of disseminated nasal NK/T-cell lymphoma using double autologous peripheral blood stem cell transplantation. *Int J Hematol* 71(1): 75-78.
10. Rodrigo JP, Suárez C, Rinaldo A, Devaney KO, Carbone A, et al. (2005) Idiopathic midline destructive disease: fact or fiction. *Oral Oncol* 41(4): 340-348.
11. Takaomi S, Iida SA, Ito AM, Tsuboi AK, Miura AK, et al. (2001) Successful Treatment of Nasal T-Cell Lymphoma With a Combination of Local Irradiation and High-Dose Chemotherapy. *Int J Hematol* 75: 195.
12. Savage KJ (2005) Aggressive peripheral T cell lymphomas (Specified and unspecified types). In: Berliner N (Ed.), *Hematology Am Soc Hematol Educ Program*, American Society of Hematology, Atlanta, USA, pp. 267-277.
13. Barrionuevo C, Zaharia M, Martinez MT, Taxa L, Misad O, et al. (2007) Extranodal NK/Tcell lymphoma, nasal type: study of clinicopathologic and prognosis factors in a series of 78 cases from Peru. *Appl immunohistochem Mol Morphol* 15(1): 38-44.
14. Chiang AKS, Chan ACL, Srivastava G, Faith CS (1998) Nasal T/natural killer (NK)-cell lymphomas are derived from Epstein-Barr virus infected cytotoxic lymphocytes of both NK- and T-cell lineage. *Int J Cancer* 73(3): 332-338.
15. Matsue K, Asada N, Takeuchi M, Yamakura M, Kimura S, et al. (2008) A clinicopathological study of 13 cases of intravascular lymphoma: experience in a single institute over a 9-yr period. *Eur J Haematol* 80(3): 236-244.