

# Breast attenuation artifact on the gated-spect of women with low/intermediate pretest probability

## Summary

**Objective:** To establish the significance of the mammary attenuation in women with low/intermediate pretest probability who come to Nuclear Medicine for suspected coronary artery disease.

**Material and method:** Fifty-four women with a low/intermediate pretest probability as they presented perfusion defects were studied for  $46\pm 10.2$  months.

**Results:** In 19 the defect was anterior, in 18 anterolateral and in 14 lateral. Significant lesions appeared in 3, in 2 of them the ergometry was positive.

The 51 without CAD were compared with a control group. No significant differences were observed in baseline characteristics, contractility and thickening. During the follow-up period no major cardiovascular event occurred.

**Conclusions:** The appearance of perfusion defects in the anterior or lateral left ventricular wall by mammary attenuation is relatively frequent. These are not associated with alterations of thickening and motility.

For a correct interpretation of the results, clinical and electrocardiographic correlation are crucial.

**Keywords:** ischemic heart disease, women, gated-Spect, mammary attenuation artifact

Volume 17 Issue 4 - 2024

Berta Covadonga Lorente Castro, Pablo Jané Soler, Isabel López Villar, Alberto Martínez Lorca, Juan Antonio Pérez Iruela, María del Val Gómez Martínez

Nuclear Medicine Service, Ramón y Cajal University Hospital, Spain

**Correspondence:** Berta Covadonga Lorente Castro, Nuclear Medicine Service, Ramón y Cajal University Hospital, Carretera de Colmenar Viejo, Km 9.100, 28034 Madrid, Spain, Email bertalor@yahoo.es

**Received:** July 08, 2024 | **Published:** August 05, 2024

## Introduction

Myocardial perfusion scintigraphy is a widely accepted, noninvasive method of myocardial perfusion scanning,<sup>1,2</sup> and cost-effective method for the diagnosis and prognostic evaluation of ischemic heart disease (IHD). However, one of the major limitations in the specificity of the scan is the attenuation of photons by soft tissues which results in false positive scans. In men the most frequent cause of attenuation is infradiaphragmatic tissues that cause defects in the inferior aspect but in women perfusion defects occur mainly in the anterior and lateral aspects of the left ventricle (LV) as a consequence of mammary attenuation.<sup>3,4</sup> These artifacts are more prominent in women with large breasts.<sup>1,5</sup>

This difficulty in the noninvasive diagnosis of IHD in women is coupled with other characteristics of this pathology in the female population, such as the atypical clinical presentation or the different profile of cardiovascular risk factors (CVRF), which leads to a gender bias in the management of IHD in women.<sup>6</sup>

The use of metastable technetium-99 (<sup>99m</sup>Tc) for the study of myocardial perfusion, whose physical characteristics make it particularly well suited for imaging, has substantially reduced the problem of attenuation artifacts due to soft tissues.<sup>7</sup> However, even today it is still a significant limitation to the accuracy of SPECT interpretation in women.<sup>8,9</sup>

The purpose of the present work has been to show our experience in the interpretation of perfusion defects that appear in women with suspected IU and intermediate/low pretest probability and that can be attributed to breast attenuation. The recognition of these artifacts is essential to avoid misdiagnoses that decrease the specificity and accuracy of the test.

## Material and method

### Patients

From April 2013 to October 2016, data were consecutively collected from a total of 441 women who attended the Nuclear Medicine service for IC diagnosis. For the present study, 54 (12.24%) women were considered who met the following inclusion criteria: low pretest probability for IC<sup>10</sup> and with stress imaging defects greater than or equal to 10%.<sup>11</sup> Holly TA, et al. were in the anterior and/or lateral aspect of the LV in the stress study. The patients were followed up for a mean time of  $46\pm 10.3$  months. The results were compared with those obtained in a database of 359 women with normal myocardial perfusion studies in whom the presence of IHD was ruled out in the myocardial perfusion study.

Pretest probability was defined according to current European Society of Cardiology guidelines, according to sex, age category, and type of angina pectoris (typical, atypical, or non-angina).<sup>12</sup> as well as the criteria of Diamond and Forrester.<sup>10</sup> Exclusion criteria were having a history of IHD, and cardiomyopathy (both hypertrophic and dilated). The major cardiovascular events considered during the follow-up period were acute myocardial infarction (AMI) and sudden death.)

All patients underwent a structured survey that included their personal history, age, CVRF, clinical manifestations, treatments, systemic and cardiovascular comorbidities, and baseline ECG. Data were collected during a follow-up time of  $46\pm 10.2$  months and were obtained by reviewing their clinical history. Clinical data were taken into account, as well as the results of other complementary examinations and the occurrence of coronary events.

## Stress test/ergometry

The stress test was performed by treadmill exercise following the Bruce or modified Bruce ramp protocol. Electrocardiographic (horizontal ST-segment depression), hemodynamic (HR max, % of HR max, SBP max, double product (HR x SBP), and clinical (angina) parameters were evaluated. Functional class, functional capacity in metabolic equivalents (METs), and clinical and electrical response were also considered.

## Myocardial perfusion

Gated-SPECT synchronizes the acquisition of images with the ECG and makes it possible to obtain the representation of each of the tomographic slices. The radiopharmaceutical used was MIBI labeled with <sup>99m</sup>Tc with minimal redistribution and very good image quality. The doses were 555 MBq for both stress and rest, using the 24-hour protocol. Images were acquired 30 minutes after radiotracer administration. A dual-headed INFINIA HAWKEYE gamma camera arranged at 90°, equipped with a high-resolution, low energy, parallel-hole collimator (LEHR), was used for image acquisition. Sixty-two images were obtained, by traversing 180° in elliptical orbit from the right anterior oblique position to the left posterior oblique position, in *step-and-shoot* mode and the images were obtained in supine position.

Image reconstruction was performed with the 4D-MSPECT program of the University of Michigan, obtaining qualitative images and quantitative data by means of a polar map. The perfusion defects in the stress images and, when appropriate, in the resting images were expressed as a percentage of affected myocardium with respect to the total myocardium or in each coronary territory separately: territory of the anterior descending artery (AD), circumflex artery (CX) and right coronary artery (RCA). Perfusion defects were classified semiquantitatively into small or nonsignificant defects (extent ≤9%) and significant defects, with extent ≥10% (within which moderate defect was considered between 10% and 20%, and large defect as 20% or more of the total percentage of the LV).<sup>10</sup> Perfusion defects were classified as fixed, reversible, or partially reversible after the study was performed at rest.

Global LV function was quantified using ejection fraction (LVEF) and end-diastolic (EDV) and end-systolic (ESV) volumes, as well as regional function using thickening and motility. The cutoff point for LVEF was taken as 50% so that patients were determined to have normal LVEF if it was ≥50% and in case of LVEF <50% to be in heart failure.<sup>13,14</sup>

In order to carry out the present research study, a small sample of the population data that made up the observational study entitled “registry of patients with nuclear medicine explorations of the cardiopulmonary and vascular areas” approved by the ethics committee of our hospital was used.

## Statistical analysis

Statistical analysis was performed with the SPSS version 23 software package. The description of the population in terms of sociodemographic and clinical characteristics was carried out using descriptive statistics (proportions and measures of centralization, mean and standard deviation). The analysis of continuous variables was performed with Student's t-test, the analysis of proportions/percentages by Chi-square and the ANOVA test was used to compare quantitative variables between the different study groups. Statistical significance was considered if  $p < 0.05$  in all tests.

## Results

### Prevalence of women with defect in anterior, lateral and anterolateral face

The prevalence of perfusion defects attributable to breast attenuation, based on the clinical and imaging characteristics of the patients, that we found in our study was 12.24% in the group of women who came to our service for isotope testing after exercise stress test for suspected IHD.

Of the 54 women diagnosed with a perfusion defect due to breast attenuation, 19 underwent coronary angiography for suspected IHD. Of these patients, only 3 (5%) showed significant lesions (2 patients showed a severe lesion in the DC and 1 in the proximal LAD). These women presented perfusion defects in the stress study: mild defect in the anterior aspect (1 patient), moderate defect in the anterior and lateral aspects (1 patient) and severe defect in the lateral aspect (1 patient). Resting study was performed in all three patients, in two of them the defect was fixed and in one partially reversible.

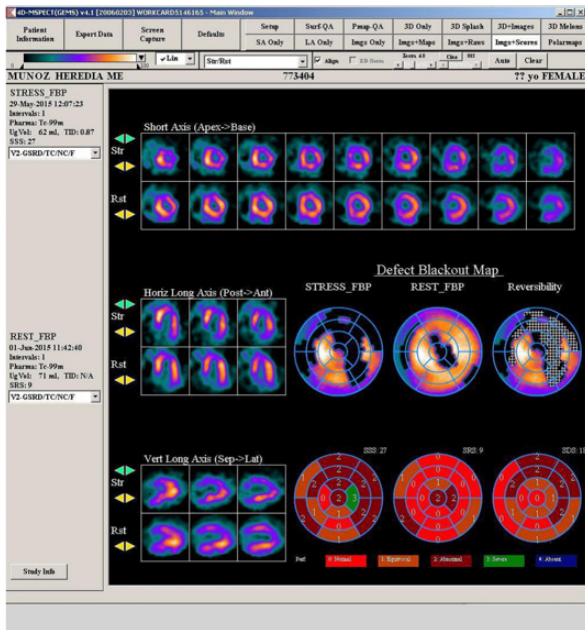
The baseline characteristics of this group of 54 patients with a perfusion defect suggestive of breast attenuation on isotope imaging are shown in Table 1.

**Table 1** Baseline characteristics of the patients

Basal characteristics	(n=54)
<b>Age (years)</b>	69±10,5
<b>FRCV</b>	
Hypertension	66,2%(45)
Dyslipemia	54%(27)
Diabetes	32,4%(22)
Obesity	27,9(19)
Menopause	67,6%(46)
Tobacco	11,8%(8)
<b>CLINIC</b>	
angina	10,3%(7)
chest pain	39,7%(27)
asymptomatic	22,1%(15)
others	20,6%(14)
<b>ERGOMETRY</b>	
Stimulus	
Exercise	91,2%(62)
Dipyridamole	8,8%(6)
Duration (min)	5,5±2,3
HR max (bpm)	132,5±29,9
PS max (mmHg)	165±26,7
METS	4,4±1,5
Ergo clinic	
refusal	89,7%(61)
positive	5,9%(4)
doubtful	4,4%(3)
not appreciable	0
Ergo electric	
refusal	42,6%(29)
positive	2,9%(2)
doubtful	2,9%(2)
not appreciable	51,5%(35)

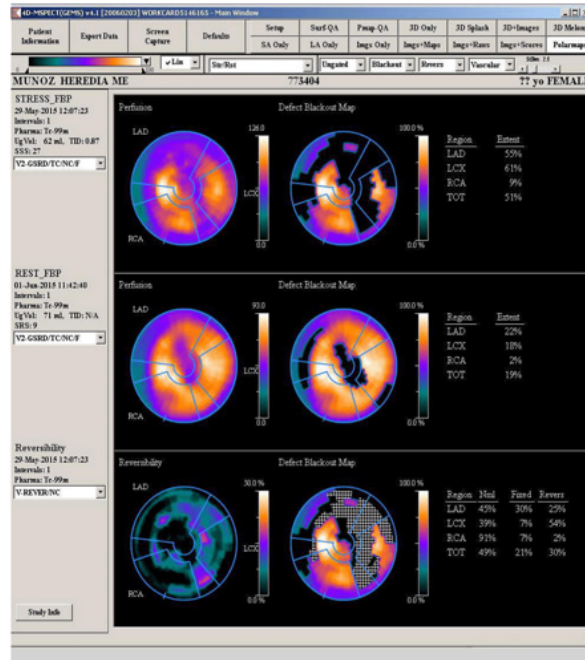
CVRF, cardiovascular risk factors; HR max, maximum heart rate; PS max, maximum systolic pressure; METS, metabolic equivalents

As an illustrative example, we can observe the gated-SPECT image of a breast attenuation defect in one of the women in our study (Figure 1a, Figure 1b).



**Figure 1a Breast attenuation artifact on gated-SPECT.**

Stress-rest study in a female patient with a perfusion defect in the anterior and lateral faces above all, with a low pretest probability of ischemic heart disease, where we observed that there is no alteration of the motility and thickening in these areas, so it is an artifact due to a defect of mammary attenuation.



**Figure 1b Breast attenuation artifact on gated-SPECT.**

In this image we observe the percentages of involvement by arterial territories (size of the defect) in a stress situation together with the resting study as well as the reversibility of the defect, which, assessed with the clinical, ergometry and electrocardiographic tracing, lead us to think of an artifact due to mammary attenuation.

## Comparison of the group with defect due to attenuation without ci with the control group

The remaining 51 patients (94%) were considered not to have IHD either because they had a normal coronary angiography or because of their evolutionary data: absence of major cardiovascular events, absence of clinical symptoms of IHD and discharge from cardiology consultations.

If we proceed to compare the baseline characteristics of the 51 women in whom a perfusion defect corresponding to attenuation artifact was found with the control group of 359 women with normal perfusion results belonging to the group of 441 women with suspected IC, we observe that age is higher ( $69.57 \pm 10$  vs  $67.5 \pm 11$  years), the most frequent clinic was chest pain in both groups (45% vs 43%), the prevalence of hypertension (65% vs 63%), dyslipidemia (51% vs 48%) and obesity (27% vs 22%) that we obtained was similar, while the percentage of diabetics turned out to be somewhat higher (29% vs 20%) and that of smokers lower (8% vs 21%).

Regarding ergometry, we can see that the result was negative in both groups of patients (94% in the group of the 51 women vs 91% in the control group in the case of clinical and 69% vs 49% in the electrical ergometry). The stimulus used in the stress test was exercise in both groups (92% in the group of women with artifact vs 95% in the women in the control group). Within the ergometry parameters, the duration was shorter in the group of the 51 women ( $5.6 \pm 2$  vs  $6.4 \pm 2$  minutes) as they were older women than the control group (the differences between both groups however were not significant), the maximum HR was similar in both groups ( $136.5 \pm 28.4$  vs  $138.2 \pm 23.3$  bpm), as was the maximum percentage of HR ( $89.5 \pm 15.7\%$  vs  $89.3 \pm 14.4\%$ ) and maximum BP ( $168.5 \pm 26$  vs  $165.2 \pm 20.2$  mmHg), however the METS were lower ( $4.5 \pm 1.6$  vs  $5.3 \pm 1.8$ ).

Regarding the semiquantitative study of perfusion defects in percentage we observed that women in whom breast attenuation artifact was diagnosed presented statistically significant differences versus the control group in stress images both in the DA territory ( $15.7 \pm 16.6\%$  vs  $1.6 \pm 5.2\%$ ;  $p=0.000$ ) and in the case of total defect ( $13.3 \pm 10.3\%$  vs  $1.8 \pm 3.3\%$ ;  $p=0.000$ ).

If we take into account thickening and motility defects (regional function) we obtained significant differences between both groups of patients in both thickening and motility defect in stress situation in the DA territory (thickening defect:  $14 \pm 7.9\%$  vs  $4.3 \pm 1.1\%$ ;  $p=0.002$  and motility defect:  $15.2 \pm 8.9\%$  vs  $6.6 \pm 1.5\%$ ;  $p=0.002$ ) and in total defect (thickening defect:  $5.2 \pm 8.7\%$  vs  $0.8 \pm 2.9\%$ ;  $p=0.001$  and motility defect:  $8.1 \pm 13.9\%$  vs  $1.4 \pm 4.6\%$ ;  $p=0.002$ ).

Regarding the results of global ventricular function we see that in the group of 51 women who presented artifacts due to breast attenuation, the LVEF in stress showed lower values ( $62.5 \pm 15\%$  vs  $74 \pm 9\%$ ) compared to the control group, however the diastolic ( $84.9 \pm 32.8$  ml vs  $67.4 \pm 23$  ml) and systolic ( $33.4 \pm 25.6$  ml vs  $19.1 \pm 11.9$  ml) volumes in stress were higher than those presented by the patients in the control group. In the control group, the older the age of the patients, the LVEF increased significantly ( $p=0.036$ ) but the values of the volumes also decreased significantly (in the case of VTD with a  $p=0.000$  and in VTS with a  $p=0.000$ ). Significant differences were found in LVEF under stress ( $p=0.000$ ), TDV ( $p=0.001$ ) and STV ( $p=0.000$ ) between both groups of patients.

The results of the comparison of the two groups are shown in Table 2.

**Table 2** Differences between control group and artifact group

	Control (n=359)	Artefacto (n=51)	P
<b>Age (years)</b>	67,2 ±10,8	69,5±10,2	0,14
<b>FRCV</b>			
Hypertension	63%(226)	64,7%(33)	0,87
Dyslipemia	48,2%(173)	51%(26)	0,76
Diabetes	20,1%(72)	24,4%(15)	0,14
Obesity	22,6%(81)	27,5%(14)	0,47
Menopause	74,7%(288)	74,5%(38)	1
Tobacco	20,9%(75)	7,8%(4)	0,02
<b>CLINIC</b>			0,81
angina	11,1%(40)	7,8%(4)	
atypical pain	12%(43)	7,8%(4)	
chest pain	43,2%(151)	45,1%(23)	
asymptomatic	15,3%(55)	17,6%(9)	
others	18,4(66)	21,6%(11)	
<b>ERGOMETRY</b>			
Duration (min)	6,4±2	5,6±2,2	0,05
HR max (bpm)	138,2±23,3	136,5±28,4	0,79
PS max (mmHg)	165,2±20,2	168,5±25,9	0,55
METS	5,3±1,8	4,5±1,6	0,004
Ergo clinic			0,46
refusal	91,4%(328)	94,1%(48)	
positive	5,3%(19)	2%(1)	
doubtful	1,9%(7)	3,9%(2)	
not appreciable	1,4%(5)	0	
Ergo electric			0,000
refusal	68,8%(247)	49%(25)	
positive	18%(5)	0	
doubtful	4,2%(15)	2%(1)	
not appreciable	22%(79)	49%(25)	
<b>gated-SPECT</b>			
LADs (%)	1,6±5,2	15,7±16,6	0,000
CXs (%)	3,7±8,2	18,1±20,4	0,000
TOTALs (%)	1,8±3,3	13,3±10,	0,000
FEs (%)	74,3±9,3	62,5±15	0,000
VTDs (ml)	67,4±23	84,9±32,8	0,001
VTSs (ml)	19,1±11,9	33,4±25,6	0,000
ENG-LADs (%)	1,1±4,3	7,9±14,3	0,002
ENG-CXs (%)	07±4,	0±0,2	0,17
ENG-TOTALs (%)	0,8±2,9	5,2±8,7	0,001
CON-LDAs (%)	1,5±6,6	8,9±15,2	0,002
CON-CXs (%)	0,2±2	0±0,2	0,13
CON-TOTALs (%)	1,4±4,6	8,1±13,9	0,002

CVRF, cardiovascular risk factors; EF, ejection fraction; LAD, anterior descending artery;

HR max, maximum heart rate; VTD, volume telediastolic volume; CX, circumflex artery; PS max, maximum systolic pressure; VTS, telesystolic volume; CON, contractility; METS, metabolic equivalents; ENG, enlargement

### Perfusion defects in patients with attenuation artifact without CI

The location of the attenuation perfusion defect in women without IC was as follows: in 19/51 women (37.2%) the defect was located on the anterior aspect, in 14/51 (27.4%) it was on the lateral aspect and in 18/51 (35.2%) on the anterolateral aspect.

Resting images were obtained in 31/51 women (60%). Analyzing the results of the resting study, a reversible defect was observed in 15/31 women (48.3%), partially reversible in 10/15 (66.6%) and totally reversible in 5/15 (33.3%) and a defect presenting a fixed size in 16/31 women (55.6%).

Of the 19 (37.2%) patients who presented with anterior perfusion defect, 14/19 (73.6%) patients had normal thickening, 13/19 (68.4%) normal motility, and 11/19 (57.8%) patients showed normal thickening and motility.

There were 14 patients (27.4%) with lateral aspect defect, of which 12/14 (85.7%) had normal thickening, 13/14 (92.8%) had normal motility and 12/14 patients (85.7%) showed normal thickening and motility.

We see that in the 18 patients (35.2%) with anterolateral defect, 11/18 (61.1%) had normal thickening, 11/18 patients (61.1%) had normal motility and 9/18 (50%) had normal thickening and motility.

Table 3 shows the number of patients with normal thickening and motility according to the location of the perfusion defect (patients with attenuation artifact).

**Table 3** Patients with localized perfusion defect and normal thickening and motility.

Location	Perfusion defect	N(%)	Engrossment	Motility	Eng+con
PREVIOUS		19(37,2%)	14(73,6%)	13(68,4%)	11(57,8%)
SIDE		14(27,4%)	12(85,7%)	13(92,8%)	12(85,7%)
ANTEROLATERAL		18(35,2%)	11(61,1%)	11(61,1%)	9(50%)

ENG, thickening; CON, motility

### Evolutionary follow-up of the group with artifact due to breast attenuation

During the follow-up period (of the 54 women with perfusion defects in the anterior and lateral aspect), no major cardiovascular events occurred in any of the patients studied. Of these, 3 (5.5%) did, but minor events did occur in 24 (44.4%) women (angina and/or chest pain).

### Discussion

In the literature on the subject of IC in women, the differences between women and the rest of the population in terms of clinical symptoms are well known. Women more frequently present atypical symptoms such as dyspnea, nausea, dizziness, reflux, dyspepsia, and even diaphoresis, and they are older, which affects the diagnosis and treatment of coronary artery disease.<sup>15,16</sup>

Improving the accuracy of myocardial perfusion imaging in all patients is an important goal especially in women. The two main causes that decrease test specificity in women appear to be smaller heart size and the highly variable effects of breast attenuation. Breast attenuation in gated-SPECT myocardial perfusion studies has perhaps been treated somewhat less than it should in our opinion in the medical literature. There have been, for example, authors such as Ficaró<sup>17,18</sup> Hendel<sup>19,20</sup> o Fessler<sup>21,22</sup> who since the last century have been considered the great promoters of this subject that we have studied, since it is a relatively frequent finding in routine clinical practice. Thus, in our study it appeared in 12.24% of women with intermediate/low pretest probability who attended our service for

suspected IC. For authors such as Hansen et al.<sup>4</sup> breast attenuation artifacts produce a pattern of decreased uptake in the anterior face with relative preservation of uptake in the apex. However, in our study the perfusion defects attributed to breast attenuation appeared not only in the anterior face but also in the anterolateral and lateral faces, giving rise to an image of hypocaptation in the territories irrigated by the DA and CX arteries.

The artifacts related to soft-part attenuation appear in any of the softwares used in the gated-Spect studies, in our case we use the software called Corridor 4DM (University of Michigan) with a high accuracy and good reproducibility of the data, although the appearance of such artifacts is also described with the use of other computer programs different from the one we use.<sup>23</sup>

Women who present breast attenuation artifact in myocardial perfusion studies are patients with baseline characteristics very similar to the population without defect but differ in age and in presenting a slightly lower LVEF with larger ventricular volumes. These data, in turn, could be related to the older age of the patients who present perfusion defects due to mammary attenuation.

Several methods have been proposed to decrease the effect of artifacts in myocardial perfusion studies, the most widely accepted being the correction of attenuation by using an external source or by performing low-dose CT, prone imaging or also the introduction of gamma cameras with cadmium-zinc-telluride detectors with which better results have been found to be obtained than with conventional gamma cameras.<sup>24</sup> Each of these methods has its advantages and disadvantages. Attenuation correction improves specificity but decreases sensitivity, especially in the case of inferior defects corresponding to the territory of the CD artery.<sup>25</sup> Prone imaging improves patient dosimetry but increases scanning time and some authors argue that it is less efficient than using attenuation correction to diagnose these artifacts.<sup>26</sup> But it must be taken into account that the new gamma cameras with cadmium-zinc-telluride detectors are not yet available in some health centers, so we can affirm that in routine clinical practice the diagnosis of breast attenuation is made mainly on the basis of the experience that the nuclear physician may have in this field of the specialty.

From our point of view, the recognition of breast attenuation artifact requires an adequate clinical assessment of the patient. Our study shows that only 3 of the women studied in the group of 54 women with low pretest probability and with gated-SPECT findings of anterior, lateral or anterolateral defects had significant coronary lesions. None of the women who presented artifact had electrically positive ergometry and the ergometry was clinically positive in a very low percentage (2%), data that indicate the great contribution of ergometry in the diagnosis of women with artifacts.

The prognosis of patients with perfusion defects on the anterior and lateral sides that were interpreted as breast attenuation artifacts on gated-Spect was excellent, since only three of them had major cardiovascular events during follow-up.

The fact that attenuation defects are accompanied by normal parietal motility and parietal thickening<sup>27</sup> allows us to detect defects that are an artifact of mammary attenuation of gated-SPECT of necrosis defects.

The results obtained in our study suggest that anterior and lateral perfusion defects in women with low/intermediate pretest probability of IHD accompanied by normal motility can be interpreted as breast attenuation artifacts, but also require adequate clinical assessment of the patients and negative ergometry for myocardial ischemia.

Finally, visual analysis of gated-SPECT studies may likely overestimate functional abnormalities, particularly in those patients with marked attenuation artifact.

## Limitations

This study, like any other included in the literature on the subject, is not without limitations, most of them due to the sample size, the number of patients in the study is perhaps a small number, but among the 441 women who made up the patients with suspected IC we only found 54 patients who presented breast attenuation artifact in the gated-SPECT image, which we logically used despite being few for our objective and which were also compared with a much larger group such as the patients without perfusion defects (n=359), which is a bit striking, but it was what we had at the time of completing the study.

There were also few women who underwent coronary angiography (n=19), but this is a strictly cardiological issue and it is the cardiologists who decide whether to perform them or not. If more had been performed, our results could possibly have changed, leaning towards the true defects, because although out of 19 there were only 3 patients with significant lesions, in my opinion few, the fact of increasing the number of tests could have given us more women with true perfusion defects and fewer with breast attenuation defects, which would have changed the conclusions.

## Conclusions

The appearance of perfusion defects in the anterior or lateral aspect due to breast attenuation artifacts is relatively frequent in women who come to our service for the diagnosis of IC (12.24%).

The baseline characteristics of those patients with attenuation artifact defects are indistinguishable from the population without defects on imaging tests.

The artifact defects that were located on the anterior, lateral and anterolateral aspect in a large number of patients were not accompanied by alterations in thickening and motility.

For an adequate interpretation of perfusion defects caused by breast attenuation, it is essential to correlate them with the patient's clinical symptoms as well as with the ergometry results.

Only 3 of 54 women with low or intermediate pretest probability of IHD and anterior, lateral or anterolateral perfusion defects had lesions on coronary angiography.

Breast attenuation artifacts tend to occur more frequently in older patients.

The LVEF in patients with breast attenuation artifact was normal but somewhat lower than that of normal patients. This lower LVEF is probably due to an increase mainly in VTD.

The difficulties in diagnosing IHD in a woman together with the difficulties in diagnosing an artifact make us go with special care in the interpretation of perfusion imaging. It is therefore important to identify those specific subgroups of patients in whom gated-SPECT offers increased diagnostic and prognostic value.<sup>28</sup>

Adequate clinical and ergometric assessment (clinical and electrical, duration, METS) in women presenting for the diagnosis of IC is essential to identify anterior and lateral facet defects as attenuation artifacts.

The recognition of this device in women in our environment is essential to avoid unnecessary catheterizations.

During the follow-up period of patients with breast attenuation artifact, no major event occurred, regardless of the location, size or degree of reversibility of the perfusion defect.

## Acknowledgments

I owe and have the honor to thank all that I am in terms of my postgraduate doctorate in Health Sciences, to my thesis director Dr. María Julia Buján Varela, and to the University of Alcalá de Henares, which provided me with the appropriate framework to carry out a great research from which two articles of my own have already borne fruit and I hope many more in the time to come.

## Conflicts of interest

None.

## References

- Judelson DR. Examining the gender bias in evaluating coronary disease in women. *Medscape Women's Health*. 1997;2(2):5.
- Hung J, Chaitman BR, Lam J, et al. Noninvasive diagnostic test choices for the evaluation of coronary artery disease in women: a multivariate comparison of cardiac fluoroscopy, exercise electrocardiography and exercise thallium myocardial perfusion scintigraphy. *J Am Coll Cardiol*. 1984;4(1):8–16.
- Stinis CT, Lizotte PE, Movahed M–R. Impaired myocardial SPECT imaging secondary to silicon– and saline–containing breast implants. *Int J Cardiovasc Imaging*. 2006;22(3–4):449–455.
- Hansen CL, Sundaram S. The ratio of the apex/anterior wall: A marker of breast attenuation artifact in women. *Nucl Med Commun*. 2006;27(10):803–806.
- Goodgold HM, Rehder JG, Samuels LD, et al. Improved interpretation of exercise TI–201 myocardial perfusion scintigraphy in women: characterization of breast attenuation artifacts. *Radiology*. 1987;165(2):361–366.
- Acevedo M, Varleta P. Exámenes diagnósticos cardiovasculares: ¿diferencias de género en su interpretación? *Rev Colomb Cardiol*. 2018;25(S1):66–72.
- Taillefer R, DePuey EG, Udelson JE et al. Comparative diagnostic accuracy of TI–201 and Tc–99m sestamibi SPECT imaging (perfusion and ECG–gated SPECT) in detecting coronary artery disease in women. *J Am Coll Cardiol*. 1997;29(1):69–77.
- Botvinick EH. Breast attenuation artifacts in TI–201 scintigraphy. *Radiology*. 1988;168(3):878–879.
- Garver PR, Wasnich RD, Shibuya AM, Yeh F. Appearance of breast attenuation artifacts with thallium myocardial SPECT imaging. *Clin Nucl Med*. 1985;10(10):694–696.
- Diamond GA, Forrester JS. Analysis of probability as an aid in the clinical diagnosis of coronary–artery disease. *N Engl J Med*. 1979;300(24):1350–1358.
- Holly TA, Abbott BG, Al–Mallah M, et al. Single photon–emission computed tomography. *J Nucl Cardiol*. 2010;17(5):941–973.
- Task Force Members, Montalescot G, Sechtem U, Achenbach S, et al. 2013 ESC guidelines on the management of stable coronary artery disease: the Task Force on the management of stable coronary artery disease of the European Society of Cardiology. *Eur Heart J*. 2013;34(38):2949–3003.
- Alexiou S, Georgoulas P, Angelidis G, et al. Myocardial perfusion and left ventricular quantitative parameters obtained using gated myocardial SPECT: Comparison of three software packages. *J Nucl Cardiol*. 2018;25(3):911–924.
- Romero–Farina G, Candell–Riera J, Aguadé–Bruix S, et al. Predictive variables for hard cardiac events and coronary revascularization in patients with normal left ventricular myocardial perfusion and systolic function. *Eur J Nucl Med Mol Imaging*. 2013;40(8):1181–1189.
- Wenger NK. Clinical presentation of CAD and myocardial ischemia in women. *J Nucl Cardiol*. 2016;23(5):976–985.
- Sørensen NA, Neumann JT, Ojeda F, et al. Relations of sex to diagnosis and outcomes in acute coronary syndrome. *J Am Heart Assoc*. 2018;7(6):e007297.
- Hendel R, Ficaro E, Williams K. Timeliness of reporting results of nuclear cardiology procedures. *J Nucl Cardiol*. 2007;14(2):266–266.
- Corbett JR, Kritzman JN, Ficaro EP. Attenuation correction for single photon emission computed tomography myocardial perfusion imaging. *Curr Cardiol Rep*. 2004;6(1):32–40.
- Hendel RC, Cerqueira M, Douglas PS, et al. A Multicenter Assessment of the use of single–photon emission computed tomography myocardial perfusion imaging with appropriateness criteria. *J Am Coll Cardiol*. 2010;55(2):156–162.
- Hendel RC, Abbott BG, Bateman TM, et al. The role of radionuclide myocardial perfusion imaging for asymptomatic individuals. *J Nucl Cardiol*. 2011;18(1):3–15.
- Ficaro EP, Fessler JA, Ackermann RJ, et al. Cardiac SPECT: effect of attenuation correction on myocardial tracer distribution.:12.
- Noh J, Fessler JA, Kinahan PE. Statistical sinogram restoration in dual–energy CT for PET attenuation correction. *IEEE Trans Med Imaging*. 2009;28(11):1688–1702.
- Malek H, Yaghoobi N, Hedayati R. Artifacts in quantitative analysis of myocardial perfusion SPECT, using cedars–sinai QPS software. *J Nucl Cardiol*. 2017;24(2):534–542.
- Liu C–J, Cheng J–S, Chen Y–C, et al. A performance comparison of novel cadmium–zinc–telluride camera and conventional SPECT/CT using anthropomorphic torso phantom and water bags to simulate soft tissue and breast attenuation. *Ann Nucl Med*. 2015;29(4):342–350.
- Sharma P, Patel CD, Karunanithi S, et al. Comparative accuracy of CT attenuation–corrected and non–attenuation–corrected SPECT myocardial perfusion imaging. *Clin Nucl Med*. 2012;37(4):332–338.
- Gutstein A, Bental T, Solodky A, et al. Prognosis of stress–only SPECT myocardial perfusion imaging with prone imaging. *J Nucl Cardiol*. 2018;25(3):809–816.
- DePuey EG, Rozanski A. Using gated technetium–99m–sestamibi SPECT to characterize fixed myocardial defects as infarct or artifact. *J Nucl Med*. 1995;36(6):952–955.
- Chatziioannou SN. Gating of myocardial perfusion imaging for the identification of artifacts. *Tex Heart Inst J*. 2000;27(1):14–18.