

# Robot-Assisted Pericardial Drainage

## Research Article

### Abstract

**Background:** The feasibility, safety, and efficacy of robot-assisted pericardial drainage (RAPD) with the da Vinci Surgical System were evaluated.

**Methods:** Subjects with pericardial effusions (PE) who were treated with RAPD were included for study. Patients with tamponade physiology with hemodynamic instability and altered respiratory function were excluded. Data regarding the ability to perform RAPD, operation time, hospital stay, need for additional incision, morbidity, and outcome were evaluated.

**Results:** A single operator attempted RAPD for 5 cases. There were no pericardial tamponade and the effusion was diffuse in all patients. Three of patients had previously undergone pericardiocentesis. All cases completed without conversion to thoracotomy. No operative complication and no in-hospital mortality were observed. The post-operative courses were uneventful and patients were discharged between post-operative days 7 and 14.

**Conclusion:** In spite of the small sample size, this study presents, for the first time, the successful use of da Vinci Surgical System for both diagnostic confirmation and therapeutic relief of pericardial fluid drainage.

**Keywords:** Pericardial effusion; Pericardial drainage; Minimally-invasive surgery; Video-assisted thoracic surgery; Robotics; Da Vinci robotic system

Volume 7 Issue 5 - 2016

**Ahmet Akgul**<sup>1,2,3\*</sup>

<sup>1</sup>Department of Gerontology, Faculty of Health Sciences, Istanbul University, Turkey

<sup>2</sup>Department of Cardiovascular Surgery, Bakırköy Dr. Sadi Konuk Training and Research Hospital, Turkey

<sup>3</sup>Department of Health Management, Faculty of Health Sciences, Istanbul University, Turkey

**\*Corresponding author:** Ahmet Akgul, Dean, Health Sciences Faculty, Istanbul University, Head, Department of Gerontology, Health Sciences Faculty, Istanbul University, Head, Department of Health Management, Health Sciences Faculty, Istanbul University, Chief, Department of Cardiovascular Surgery, Bakırköy Dr. Sadi Konuk Training and Research Hospital, İstanbul Üniversitesi, Sağlık Bilimleri Fakültesi, Demirkapı Caddesi, Karabal Sokak, 34740, Bakırköy, İstanbul, Turkey, Tel: + 90 212 414 15 00/40100; Fax: + 90 212 414 15 15; Email: info@ahmetakgul.com.tr

**Received:** November 14, 2016 | **Published:** December 21, 2016

## Introduction

Pericardial effusions compress the heart, and lead to decrease in cardiac output with haemodynamic collapse. The treatment of PE remains experimental (i.e. not standardized, based on the clinician's experience) due to lack of large randomized studies. Available treatments differ from observation with/without anti-inflammatory chemotherapy to pericardiocentesis with/without percutaneous catheter drainage, percutaneous balloon pericardiotomy and eventually to surgical interventions. Commonly two surgical techniques are being used: Transthoracic or subxiphoid surgical approach for creating pericardial window and the video-thorascopic pericardial window [1-4].

A pericardial window is a procedure which can be used both for diagnosis and treatment. Both biopsy and cytologic materials can be taken with the procedure and diagnosis for pericardial fluid accumulation can be made. Furthermore, it creates a passage allowing drainage which leads to treatment. To create such a window, pericardial resection should be performed. Thoracotomy as well as thoracoscopy, with their advantages and disadvantages, are having been used for creating pericardial window [5-7].

The video-assisted thoracoscopy (VATS) offered high benefits over thoracotomy in treating pericardial effusions in terms of less postoperative pain, shorter intensive care unit and hospital stay and better cosmetic results, however, there are some limitations, such as impaired vision and limited maneuverability of the instruments [8,9]. In order to overcome these limitations, the da Vinci Surgical Robotic System is used for minimally invasive

thorax surgery with providing three-dimensional (3D) video imaging, and telemanipulated flexible effector instruments [10]. This study reports, for the first time, the case series that highlights the role of the da Vinci Surgical Robotic System in both diagnosis and treatment of PE.

## Materials and Methods

### Study objectives

The primary objective was to characterize technical success in patients underwent RAPD. The secondary objective was the evaluation of major adverse events, defined as bleeding requiring surgical intervention, post-surgical recurrence of PE, complications and outcomes of RAPD. All patients provided written informed consent and all of them were aware of other techniques for pericardial drainage.

### Patients and Methods

The treatment of diagnosed pericardial effusion, performed between August 2014 to February 2016 at the Department of Cardiovascular Surgery at Bakırköy Dr. Sadi Konuk Training and Research Hospital, İstanbul, Turkey, was investigated. Patients were not selected for RAPD if any of the following pertained: tamponade physiology with hemodynamic instability, altered respiratory function. The most frequent symptoms were progressive exertional dyspnea, and lower extremity edema. Physical findings revealed pulsus paradoxus, elevated neck veins and positive Kussmauls signs.

X-ray and echocardiographic data prior to RAPD were reviewed for pericardial effusion size and the presence of tamponade physiology. Tamponade was indicated as pericardial effusion performed right atrial compression and/or right ventricular diastolic collapse. Computerized tomography scan was performed for diagnosis as well as to determine the predominant localization of the pericardial effusion and concomitant findings of thorax for planning the side of intervention. All data were recorded. Primary and secondary objectives were evaluated. Post-surgical recurrence of PE defined as an effusion on postoperative echocardiography/tomography that was hemodynamically significant, requiring a second procedure.

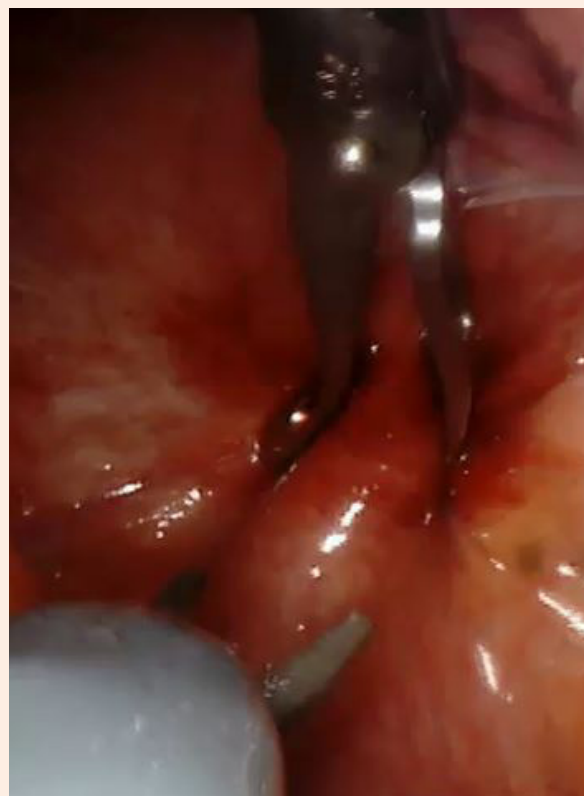Operative time (the time from induction of anesthesia until the time the patient left the operative room), intraoperative and postoperative complications, technical complications, postoperative bleeding, drainage tube-related complications, wound-related problems, mortality (intraoperative and in-hospital mortality), and hospital lengths of stay which was calculated from the day of RAPD until discharge from the hospital.

Follow-up was done for all the patients following discharge from the hospital.

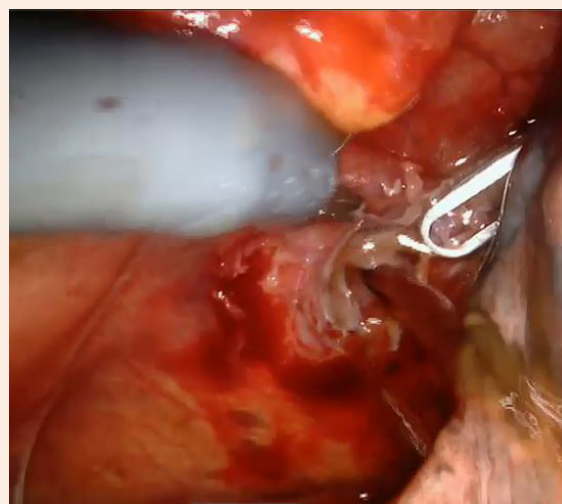
### Operative techniques

General anesthesia was used in all patients. A single prophylactic dose of antibiotic was administered just at the beginning of operation. All patients underwent single lung ventilation using a dual lumen endotracheal tube. The patient is positioned with a roll under the left chest beneath the scapula. The chest was initially entered with a blunt instruments to prevent damage to the internal structures. The chest was insufflated with carbon dioxide at 10 - 15 mmHg. The camera port was inserted into fifth interspace, 2-3 fingerbreadths lateral to the midclavicular line. This allows optimal visualization of the pericardium but adequate distance away for manipulation. Ventilation was continued by only right lung and two 8.5-mm trocars were placed into third and seventh interspaces under direct vision by the intrathoracic camera. The da Vinci Robotic surgical system (Intuitive Surgical, Inc., Mountain View, CA) was then docked and instruments inserted. This robotic system has two main parts which one is the surgeon console and the other is the patient unit. During the operation, the chief surgeon was located in surgeon console which was set up approximately 250-300 cm away from the patient. The other surgeon was located nearby the patient unit in order to manipulate the instruments.

The pleural cavity was examined, and any pleural effusion was evacuated and sent for cytology. The pericardium and phrenic nerve were visualized and the distended pericardium was grasped with forceps and incised anterior to the phrenic nerve with scissors (Figure 1). A pericardial window was created (Figure 2), and the pericardium was sent for pathological evaluation as well as pericardial fluid was collected for cytological and microbiological analysis. A single thoracostomy tube was placed in pleural cavity and connected to underwater seal drainage. The incisions were closed in layers. All patients were transferred to intensive care unit for routine 24-hour postoperative evaluation and returned to ward. The thoracostomy tube was removed when the amount of daily drainage was below 100 mL.



**Figure 1:** The distended pericardium was grasped and prepared for incision by robotic instruments.



**Figure 2:** Robotically resected pericardium and robotic pericardial window performed. Pericardial fluid drainage can be seen.

### Results

The RAPD was applied in five patients (four male and one female patient, mean age, 65.2 years). Associated diseases were COPD and gastric cancer in one patient, two patients had PE due

to renal failure, one patient had idiopathic PE and one patient (only female) had massive PE due to excessive anticoagulation treatment for previous mitral valve replacement (MVR) with tricuspid valve repair. Three of patients had previously undergone pericardiocentesis. History of cardiac and chest-related procedures and outcomes are summarized in Table 1. There were no pericardial tamponade and the effusion was diffuse in all patients except one patient had relatively posterior

accumulation. Biopsies of pericardium and cytological analysis of pericardial fluid revealed the most common diagnosis as chronic inflammation (4 patients). One patient had cardiac operation (MVR) with excessive use of anticoagulants (warfarin). In spite of the sample size is insufficient to draw any conclusions, however, RAPD provided an excellent view of both pleural cavity and pericardium and appropriate selection of biopsy sites.

**Table 1:** Pre-, intra- and post-operative data.

Case	History of thorax-related procedures	Total area of resection (cm <sup>2</sup> )	Operative time (minutes)	Bleeding (ml)	Duration of chest tube (days)	Complications	Mortality	Hospital lengths of stay(days)
1	Pericardiocentesis	18	170	5	5	none	none	9
2	MVR + Tricuspid valve repair	12	180	30	8	none	none	14
3	Pericardiocentesis	8	120	5	4	none	none	8
4	Pericardiocentesis	9	110	5	4	none	none	7
5	Thoracentesis	12	130	5	5	none	none	8

MVR: Mitral Valve Replacement.

During operations, no haemodynamic instability was observed. Cardiac rhythmias were normal during pericardiectomy. There were no intraoperative complications as well as no postoperative complications. There was no superficial or deep wound infection. No recurrence of effusion was observed. At follow-up, there was no recurrence of the effusion detected by computerized tomography. There was no RAPD-related re-do surgery, however, one case (female patient) with previously had cardiac surgery (MVR with tricuspid valve repair) underwent bariatric surgery for obesity.

## Discussion

Pericardial effusion varies from asymptomatic fluid accumulation to life-threatening cardiac tamponade. The PE may result from a variety of causes. Assessment of patient with PE includes chest X-ray, transthoracic echocardiography, computerized tomography and eventually invasive techniques [11,12]. Various techniques have been described for the diagnostic and also therapeutic management of PE, which includes ultrasound-guided pericardiocentesis [12-14], catheter drainage [4,11,15], pericardioperitoneal shunt [16-18], pericardial fenestration/window [3,7,19]. The size and duration of fluid accumulation in pericardial space are the key points for management. In patients with large (>20 mm) and long-standing (>3 months), pericardiocentesis should be considered due to progression of haemodynamic instability [20]. Ultrasound-guided pericardiocentesis was the option for diagnosis and treatment, however, patients with mediastinal trauma, pericardial adhesions, pacing wires, and vascular conduits are high risk for pericardiocentesis. Furthermore, pericardiocentesis is associated with high rates of recurrence, therefore now, it is not considered as a gold standard therapy [8].

Thoracotomy and/or minimally invasive thoracic surgery for creating pericardial window be the treatment option for drainage of effusions in pericardial space. A pericardial window procedure can be used both for diagnosis and treatment. When pericardial window is required for the management of PE, there were two main options [21-23]:

- Thransthoracic or subxiphoid surgical intervention.
- Video-assited thoracoscopic surgery (VATS).

And now, for the first time, the other option remains:

- Robot-assisted pericardial drainage.

Practically, these 3 techniques can easily be performed in clinically stable patients, however, patients who are unstable from tamponade physiology often need echocardiographic-guided percutaneous approaches.

As expected, there may be difference in morbidity, diagnostic accuracy, recurrence of effusion, intra- and post-operative complications, and cost between these procedures. Among the first two techniques, the use of VATS as a preferred procedure for the treatment of PE is increasing, since VATS has many advantages over thransthoracic/subxiphoid surgery as: less traumatic, better cosmesis than thoracotomy, and a more extensive pericardial resection as well as a better visualization are possible when compared with the subxiphoid approach [3,7,9].

Like VATS, robot-assisted pericardial drainage (RAPD) is minimally invasive procedure of the thorax with access to the pericardial cavity via small incisions for port access for camera and surgical instrumentation. RAPD has the similar advantages with VATS as reduced hospital stay, better cosmetic results and

less pain. Additionally, RAPD has more advantages than VATS as: more extensive pericardial resection and better visualization. The high quality 3D virtual operating field and the stable camera platform allow for precise dissection and when needed suturing as well [10]. As presented by Piehler, there is direct relationship between the size of resected-pericardium and the incidence of recurrence of PE as well as constriction of pericardium remained [5]. The extent of the pericardial resection can be easily controlled with intraoperative evaluation of the pericardial window due da Vinci visualization system. The superb 3D vision helps surgeon at the console during RAPD for more precisely differentiate tissue margin than the surgeon looking into a conventional monitor during VATS [10,24].

Restricted maneuverability of the instruments of VATS [24] is also another limitation of the use of VATS when compared with RAPD. Hand movements in the grips of the console of the da Vinci robotic system are naturally and intuitively transmitted to the instruments located in chest. Additionally, movements of the instruments are superior than conventional laparoscopic instruments, i.e. ergonomics for surgeon are much better than in VATS. Various complex surgical maneuvers can be performed in tiny and remote operational sites. This is extremely important if any complication occurs and in fact, during creating a pericardial window located nearby phrenic nerve especially in complex PE. One of the other superior feasibility is due to the excellent movements of the robotic instruments with the active elevation of thorax which is suitable for complex PE [10,24].

One of the concern is the operative time in our cases which was relatively longer when compared with previous studies [21-23]. This may be attributed to “learning-curve” period, however, as our team performed the first isolated robotic and hybrid procedures for robotic-assisted cardiac surgery among state and university hospitals in our country in 2011, we have been quite experienced in robotic cardiac surgery [25]. This relatively longer operative time may be due to the definition of “operative time”. As presented in Methods section, we describe the operative time as: the time from induction of anesthesia until the time the patient left the operative room, which includes positioning of the patient, placement of a double-lumen endotracheal tube, full sterile draping, the setup of the robotic system, positioning of the instruments and attachment to the trocars as well as preparation of the patient leaving the operative room following skin closure. Furthermore, the studies comparable with our study in regard of operative time, may be evaluated by “skin-to-skin” time.

In the present study, both biopsy and cytologic materials were taken during RAPD. To have data for diagnosis is very important during pericardial drainage therapy in PE since systemic therapy would be based on these findings. For increasing the probability for precise diagnosis, both the pericardial fluid and pericardial tissue would be sent for examination. With RAPD, the inner surface of the pericardium and the epicardium can be easily explored, pericardial fluid and biopsies can be taken under direct visual control while creating a passage allowing drainage which leads to treatment. Additionally, for therapeutic purposes, during the same procedure, if necessary, sclerosing agents can be instilled for pericardiodesis and RAPD is more likely to be used when concomitant intrapleural procedures are required.

It should be noted that RAPD is not recommended for patients with tamponade and failed respiratory function. Additionally, as presented, the RAPD procedure is associated with a longer operative time, relatively higher cost and could not be performed with local anesthesia. In other circumstances, RAPD offers its specific advantages over conventional surgical procedure including VATS especially in both diagnosis and treatment of complex PE.

## Conclusion

The study shows that, in spite of the small sample size, RAPD is a safe, minimally-invasive technique which allows for effective pericardial drainage with accurate diagnosis of PE while avoiding the complications of conventional surgical procedures and performs its specific advantages over conventional VATS.

## References

1. Muhammad MI (2011) The pericardial window: is a video-assisted thoracoscopy approach better than a surgical approach? *Interact Cardiovasc Thorac Surg* 12(2): 174-178.
2. Melfi FMA, Fanucchi O, Mussi A (2016) Minimally invasive mediastinal surgery. *Ann Cardiothorac Surg* 5(1): 10-17.
3. Toth I, Szucs G, Molnar TF (2012) Mediastinoscope-controlled parasternal fenestration of the pericardium: definitive surgical palliation of malignant pericardial effusion. *Journal of Cardiothoracic Surgery* 7: 56.
4. Tsang TS, Oh JK, Seward JB (1999) Diagnosis and management of cardiac tamponade in the era of echocardiography. *Clin Cardiol* 22(7): 446-452.
5. Piehler JM, Pluth JR, Schaff HV, Danielson GK, Orszulak TA, et al. (1985) Surgical management of effusive pericardial disease. *J Thorac Cardiovasc Surg* 90(4): 506-516.
6. Mack MJ, Landreneau RJ, Hazelrigg SR (1993) Video thoracoscopic management of benign and malignant pericardial effusions. *Chest* 103(4 Suppl): 390S-293S.
7. Yoshida M, Sakiyama S, Kondo K, Tangoku A (2015) Thoracoscopic pericardial fenestration for effective long-term management of non-tuberculous mycobacterium pericarditis. *Gen Thorac Cardiovasc Surg* 63(1): 49-51.
8. Shapira OM, Aldea GS, Fonger JD, Shemin RJ (1993) Video-assisted thoracic surgical techniques in the diagnosis and management of pericardial effusion in patients with advanced lung cancer. *Chest* 104(4): 1262-1263.
9. Georgios PG, Alon S, Erez S (2005) Video-assisted thoracoscopic pericardial window for diagnosis and management of pericardial effusions. *Ann Thorac Surg* 80(2): 607-610
10. Bodner J, Wykypiel H, Wetscher G, Schmid T (2004) First experiences with the da Vinci operating robot in thoracic surgery. *Eur J Cardiothorac Surg* 25(5): 844-851.
11. Kirkland LL, Taylor RW (1992) Pericardiocentesis. *Crit Care Clin* 8(4): 699-712.
12. Nagdev A, Mantuani D (2013) A novel in-plane technique for ultrasound-guided pericardiocentesis. *Am J Emerg Med* 31(9): 1424.e5-9.
13. Zerth H, Harwood R, Tommaso L, Girzadas DV (2012) An inexpensive,

- easily constructed, reusable task trainer for simulating ultrasound-guided pericardiocentesis. *J Emerg Med* 43(6): 1066-1069.
14. Garth AP, Hwang JQ, Schuur JD, Rosborough S (2009) Ultrasound guided pericardiocentesis of cardiac tamponade. *Acad Emerg Med* 16(8): 811.
  15. Martinoni A, Cipolla CM, Cardinale D, Civelli M, Lamantia G, et al. (2004) Long-term results of intrapericardial chemotherapeutic treatment of malignant pericardial effusions with thiotepa. *Chest* 126(5): 1412-1416.
  16. Molnar TF, Biki B, Horváth OP (2002) Pericardioperitoneal shunt: further development of the procedure using VATS technique. *Ann Thorac Surg* 74(2): 593-595.
  17. Pataki N, Szelig L, Horvath OP, Biki B, Molnar TF (2002) Pericardial drainage using the transdiaphragmatic route: refinement of the laparoscopic technique. *Surg Endosc* 16(7): 1105.
  18. Izzat MB, Prendergast B, Thorpe JA (1993) Pericardioperitoneal shunt for persistent effusions. *Ann Thorac Surg* 55(2): 568.
  19. de Ceuninck M, Demedts I, Trenson S (2013) Malignant cardiac tamponade. *Acta Cardiol* 68(5): 505-507.
  20. Shabetai R (2004) Pericardial effusion; haemodynamic spectrum. *Heart* 90(3): 255-256.
  21. Altman E, Rutsky O, Shturman A, Yampolsky Y, Atar S (2015) Anterior parasternal approach for creation of a pericardial window. *Ann R Coll Surg Engl* 97(5): 375-378.
  22. Katlic MR, Facktor MA (2015) Non-intubated video-assisted thoracic surgery in patients aged 80 years and older. *Ann Transl Med* 3(8): 101.
  23. Celik S, Celik M, Aydemir B, Tanrikulu H, Okay T, et al. (2012) Surgical properties and survival of a pericardial window via left minithoracotomy for benign and malignant pericardial tamponade in cancer patients. *World J Surg Oncol* 10: 123.
  24. Dieter Jr RA, Kuzycz GB (1997) Complications and contraindications of thoracoscopy. *Int Surg* 82(3): 232-239.
  25. Akgul A (2011) First isolated robotic and first hybrid procedures for robotic-assisted cardiac surgery among state hospitals. *Turkiye Klinikleri J Cardiovasc Surg-Special Topics* 3(3): 18-21.