

# Intermediate outcome of transcatheter closure of secundum atrial septal defect on cardiac remodeling in egyptian children and adults

## Abstract

**Background:** Atrial septal defects (ASDs) are the second most common congenital lesion in adults. ASD closure is followed by symptomatic improvement and regression of pulmonary artery pressure (PAP), reduction in right heart volume overload and hence the prevalence of arrhythmias, thus quantification of the RV function is an important prognostic factor. Tissue Doppler and strain imaging are helpful tools for the assessment of RV systolic and diastolic function.

**Purpose:** To evaluate the intermediate-term outcome of transcatheter closure of ASD by Atrial Septal Occluder (ASO) on the cardiac remodeling especially RV using 2D Echocardiography and Tissue Doppler.

**Methods:** From April 2011 to January 2012, 30 patients with secundum type ASD were treated by transcatheter closure of their defects. One year after the procedure Patients included in the study were subjected to thorough history taking, physical examination and 12 leads surface electrocardiogram. Full 2D and color Doppler echocardiographic study was performed in addition to Tissue Doppler Assessment of right ventricular function via measurement of Tricuspid annular Tissue Doppler velocities, strain and strain rate from the RV free-wall and the interventricular septum and RV Tei index.

**Results:** At the 1year follow up of transcatheter ASD closure, the RVEDD had decreased from  $22.93 \pm 5.889$ mm to  $18 \pm 4.06$ mm ( $P=0.000$ ), and the LVEDD had increased from  $33.23 \pm 5.393$ mm to  $36.27 \pm 6.75$ mm ( $P=0.001$ ). Mean PAP decreased from  $18.37 \pm 4.796$ mmHg to  $14.77 \pm 4.75$ mmHg ( $P=0.022$ ). RVSP decreased from  $28.9 \pm 4.425$ mmHg to  $15.83 \pm 4.17$ mmHg ( $P=0.000$ ). Regarding electrocardiography, the P wave duration decreased from  $107.13 \pm 19.62$  ms to  $77 \pm 14.18$  ms ( $P=0.000$ ) and the PR interval decreased from  $177.97 \pm 21.932$  ms to  $160.33 \pm 26.06$  ms ( $P=0.000$ ). The QRS duration decreased from  $134.40 \pm 4.97$ ms to a mean of  $119.87 \pm 4.12$  ms ( $P=0.000$ ). All the patients had normal sinus rhythm before closure and no one developed arrhythmia until 1 year after closure. 50 % of the patients had normal RV size at the 1-year follow up. Tricuspid annular velocities, longitudinal strain, and strain rate measurement showed no significant difference as compared to normal values, which suggest improvement of the RV systolic and diastolic function after transcatheter closure.

**Conclusion:** Transcatheter ASD closure leads to a significant improvement in heart cavity dimensions and RV function and reversal of electrical and mechanical changes. Novel parameters for assessment of RV function are promising and appear to be helpful for the assessment of RV function and its response to correction of volume.

Volume 6 Issue 5 - 2016

**Ahmed Ammar, Tamer M Abu Arab, Walid A El Hammady, Maiy H El Sayed**

Ain Shams University Hospitals, Cairo, Egypt

**Correspondence:** Ahmed Ammar, Ain Shams University Hospitals, Cairo, Narges 1, Fifth settlement, New Cairo, Egypt, Tel 201001500138, Email [ahmed\\_ammam@med.asu.edu.eg](mailto:ahmed_ammam@med.asu.edu.eg)**Received:** September 21, 2016 | **Published:** October 07, 2016

## Introduction

Trans-catheter ASD closure has become an important alternative to surgical repair in the management of patients with Secundum-type ASD.<sup>1</sup> It is a simple, effective technique with low complication rate. Transcatheter ASD device closure leads to significant improvement in the heart cavity dimensions in particular the right sided dimensions in children and adults in the intermediate-term follow up period.<sup>2,3</sup>

Transcatheter ASD device closure can reverse electrical and mechanical changes in the atrial and ventricular myocardium.<sup>4</sup> Novel echocardiographic methods have been developed to quantify global and regional left ventricular (LV) function. Its major importance for diagnostic and prognostic evaluation in various cardiovascular diseases is well established. In contrast, quantitative assessment of right ventricular (RV) function is still challenging due to its complex anatomy and thin wall structure, and therefore not incorporated into

daily clinical practice.<sup>5</sup> Reduction in right heart volume overload and improvement in right atrium and ventricular diameters after percutaneous ASD closure decrease the prevalence of cardiac arrhythmias<sup>6</sup>, thus quantification of the RV function is an important prognostic factor. RV systolic and diastolic function has been evaluated using several parameters including RV myocardial performance index (RMPI) “The tie index” which has been reported to determine RV global systolic and diastolic function, tricuspid annular plane systolic excursion (TAPSE), 2D RV fraction area change (FAC) expressed as a percentage change in the RV chamber area from end-diastole to end-systole, Tissue Doppler Tricuspid annular velocities and longitudinal strain and strain rate.<sup>5,7,8</sup>

Tissue-Doppler-based techniques allow for quantification of myocardial function. Myocardial strain is a dimensionless index of tissue deformation expressed as a fraction or percent change. Strain rate (SR) measures the local rate of deformation per time unit.<sup>9</sup>

Therefore, the aim of this study was to evaluate intermediate and long-term outcome of transcatheter closure of ASD by Atrial Septal Occluder (ASO) on Cardiac Remodeling in Children and Adults using 2D Echocardiography and Tissue Doppler.

## Methods

### Patients

From April 2011 to January 2012, 30 patients with secundum type ASD were treated by transcatheter closure of their defects in Ain Shams University hospitals. One year after the procedure those patient were followed up and studied for the intermediate term outcome.

### Study protocol

All patients were subjected to proper history taking with emphasis on residual symptoms especially dyspnea with New York Heart association (NYHA) class and palpitations, full clinical examination especially signs of pulmonary hypertension (accentuated second heart sound) and residual sizable defect (wide fixed splitting of S2). Twelve lead ECG was recorded for all patients commenting on P wave, PR interval, QRS duration and R wave amplitude and any arrhythmias especially atrial fibrillation, atrial flutter and supraventricular tachycardia.

### Transthoracic Echocardiography (TTE)

All patients underwent full echocardiographic assessment using Philips machine (3.5 MHz phased array transducers for children and 2.5 MHz for adult patients) with proper sedation for agitated infants and children if needed, the measurements were normalized to body surface area: The following echocardiographic data were obtained:

1. Device assessment: using different views (subcostal, apical 4 chambers, parasternal short axis and RV inflow) to assess size, shape, location, relation to adjacent structure and any residual shunt using color Doppler.<sup>10</sup>
2. Left and right atrial dimensions: measured in apical 4-chamber view in both transverse and longitudinal axis.<sup>10</sup>
3. Mitral Valve: The mitral valve was examined in apical 4-chamber view regarding mobility of the leaflets and presence of mitral regurgitation (MR).
4. Tricuspid valve and right ventricular systolic pressure (RVSP): The tricuspid valve was examined in apical 4 chamber and RV inflow parasternal long axis views regarding mobility of the leaflets and presence of tricuspid regurgitation (TR). If TR was present, a continuous wave Doppler was applied to the TR jet after being properly aligned to determine the TR velocity and hence the right ventricular systolic pressure was calculated according to the modified Bernoulli equation which states right ventricular systolic pressure (RVSP) = (TR velocity)<sup>2</sup> + P (RA) where TR velocity is the maximal velocity of the TR jet (in meters per second) and P (RA) is right atrial pressure estimated by IVC diameter and presence of inspiratory collapse.<sup>10,11</sup>
5. Right ventricular dimensions and size: RV end diastolic dimension (RVEDD) was measured in parasternal longa axis view using M-Mode,<sup>10</sup> also in apical 4 chamber view RV was measured in both longitudinal and transverse axis at end diastole and relative size of RV was compared to that of LV.<sup>11</sup>
6. Fractional area change (FAC) and Tricuspid Annular Plane Systolic Excursion (TAPSE): both to roughly assess systolic RV function.

7. RV FAC= RV end diastolic area – RV end systolic area / RV end diastolic area x 100.<sup>11</sup>
8. TAPSE is the measure of RV base to apex shortening during systole using M-Mode in apical 4-chamber view.<sup>10</sup>
9. Left ventricular dimension and systolic function (ejection fraction) using M-Mode in parasternal long axis view.<sup>12</sup>
10. Pulmonary valve and mean pulmonary artery pressure (MPAP): the pulmonary valve was examined in RV outflow parasternal long axis and parasternal short axis views (at level of aortic valve) if pulmonary regurgitation (PR) was present, the MPAP was calculated according to the modified Bernoulli equation where:

$$\text{MPAP} = 4 (\text{Peak PR velocity})^2 + \text{P (RA)}.$$

### Tissue Doppler Imaging (TDI)

**A-Tissue Doppler Velocities:** An apical 4-chamber window is used with a tissue Doppler mode region of interest highlighting the RV free wall. The pulsed Doppler sample volume was placed across the lateral tricuspid annulus. Peak diastolic velocity during early filling (E'), Peak diastolic velocity during late filling (A) and peak systolic velocity (S) are obtained in three to five cardiac cycles and averaged.<sup>11</sup>

**B- Strain and Strain rate:** A narrow imaging sector focusing on the RV free wall and interventricular septum (IVS) in color-coded tissue Doppler mode was taken, and  $\geq 3$  beats were acquired with suspended respiration and a frame rate was adjusted at 150 frames/second. Care was taken to align the segment in the center of the sector to avoid errors due to the angle dependence of Doppler. Values for strain and strain rate are then derived offline on the system using equipment-specific algorithms by placing regions of interest of varying sizes in the mid portion of the RV free wall and interventricular septum.<sup>11</sup>

**C- RV Tei index:** The RV myocardial performance index (RVMPI) is the ratio of the total isovolumic time (isovolumic contraction time ICT and isovolumic relaxation time IRT) divided by the RV ejection time and is calculated as follows:

- a. Pulsed Doppler across the tricuspid annulus was obtained. The tricuspid (valve) closure opening time (TCO) was measured from the cessation of the A wave to beginning of the subsequent E wave. Ejection time (ET) was measured from the beginning of the S wave to the cessation of the S wave. 4. RV Tei index = (TCO - ET)/ET.<sup>13</sup>

### Statistical analysis

All data were statistically analyzed using the Statistical Package for Social Science Program (SPSS) TM version 16. The quantitative data were presented as mean and SD for the parametric data and as median and interquartile ranges (IQR) for the non-parametric data while the qualitative data was presented as a number and percentage. Chi square test was used to compare between two groups with qualitative data. While, paired sample t-test was used to compare between two paired groups with quantitative data. The Confidence Interval (CI) was set to be a 95% and the probability (p-value) was considered significant at the following levels: Statistical significance was defined as  $P < 0.05$ , highly significant (HS) as  $P \text{ value} < 0.01$ .

### Results

From April 2011 to January 2012, 30 patients with secundum ASD were treated successfully by transcatheter closure of their defects. One year after closure the patients were followed up to assess

the intermediate term outcome of the procedure and the data were compared with the preintervention and short term follow up data. The 30 patients were 12 males (40%) and 18 females (60%) with age ranging from 3 to 40years and median of 10years. The weight of the patients ranged from 15 to 120kg with mean  $\pm$  SD  $31.20 \pm 24.4$ . The body surface area (BSA) of the patients ranged from 0.7-2.4 with mean  $\pm$  SD  $1.12 \pm 0.47$ .

The ASD diameter using TTE ranged from 7mm to 35 mm with mean  $16.13 \pm 6.51$ mm, and using TEE ranged from 10mm to 36mm with mean  $18.67 \pm 6.63$ mm, Amplatzer device was used to close the ASD in 22 patients (73.3%) with size ranged from 12-36mm and Occlutech device was used in 8 patients (26.7%) with size ranged from 12-34mm. All patients improved clinically with no one complained of dyspnea or palpitation through the year and no specific clinical signs were observed.

### Electrocardiographic characteristics

All the patients had normal sinus rhythm before closure and no one developed arrhythmia till 1year after closure. Comparing the ECG parameters measured before closure to those measured after one month and after one year there was a highly significant reduction in the values of P wave duration (P= 0.005), the PR interval (P= 0.000)

and QRS duration (P= 0.000) 1 month after closure. The reduction continued highly significant till 1year after closure regarding P wave duration (P= 0.000) and QRS duration (P= 0.000) and significant regarding PR interval (P= 0.017). There was no significant change in the P wave amplitude and R wave amplitude till 1year after closure. Although there was evident change in RBBB morphology, however it was not statistically significant (Table 1), (Figure 1& 2).

### Echocardiographic parameters

By comparing the echocardiographic parameters measured before closure with those measured 1month after closure there was a highly significant difference in all parameters; the LVEF, LVEDD, LAD1, LAD2 showed a significant increase while the RVEDD, RAD1, RAD2, RVSP and mean PAP showed a significant decrease.

And when compared to that measured after one year there was a significant improvement in RVEDD and RVSP while LVEF, LVEDD, LAD1, LAD2, RAD1, RAD2, mPAP showed no statistically different changes.

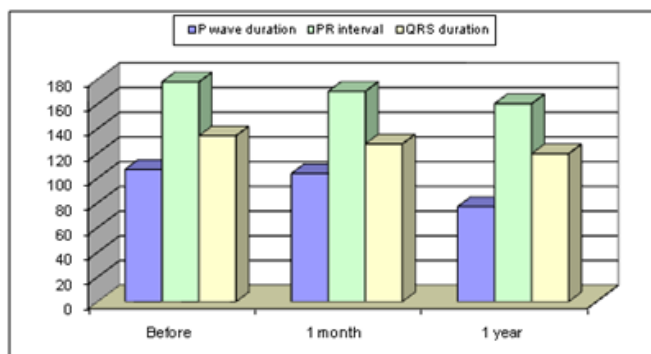
Also the improvement of RV dilatation was highly significant one month after closure however no more significant improvement was noticed after one year (Table 2).

**Table 1** ECG results before device closure, 1 month and 1 year after device closure

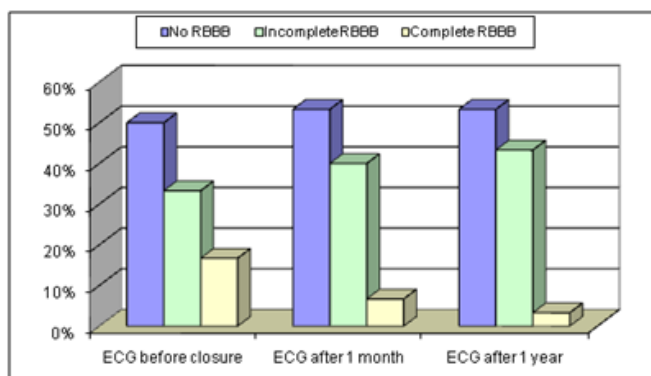
		ECG Before Closure		1 Month After Closure		1 Year After Closure	
Rhythm disturbance	Positive	0		0		0	
P wave duration	Mean $\pm$ SD	107.13 $\pm$ 19.62		103.8 $\pm$ 19.17		77 $\pm$ 14.18	
P wave amplitude	Mean $\pm$ SD	0.18 $\pm$ 0.05		0.18 $\pm$ 0.05		0.18 $\pm$ 0.05	
PR interval	Mean $\pm$ SD	177.97 $\pm$ 21.93		170.33 $\pm$ 19.8		160.33 $\pm$ 26.06	
QRS duration	Mean $\pm$ SD	134.4 $\pm$ 4.9		127.8 $\pm$ 4.4		119.87 $\pm$ 4.12	
R wave amplitude	Mean $\pm$ SD	0.21 $\pm$ 0.05		0.19 $\pm$ 0.05		0.17 $\pm$ 0.07	
RBBB	No RBBB	15	50.00%	16	53.30%	16	53.30%
	Incomplete RBBB	10	33.30%	12	40.00%	13	43.30%
	Complete RBBB	5	16.70%	2	6.70%	1	3.30%

**Table 2** Echo results before closure, 1 month and 1 year after closure

		Before Closure		1 Month		1 Year	
EF	Mean $\pm$ SD	66.97 $\pm$ 6.6		72.9 $\pm$ 6.205		70.5 $\pm$ 5.72	
	Range	55 - 81		60 - 85		58 - 81	
LVEDD	Mean $\pm$ SD	33.23 $\pm$ 5.39		35.37 $\pm$ 5.468		36.27 $\pm$ 6.75	
	Range	21 - 43		26 - 46		26 - 51	
RVEDD	Mean $\pm$ SD	22.93 $\pm$ 5.89		19.7 $\pm$ 4.162		18 $\pm$ 4.06	
	Range	14 - 32		14 - 32		26-Nov	
LAD1	Mean $\pm$ SD	26.47 $\pm$ 5.82		29.37 $\pm$ 5.756		28.73 $\pm$ 5.30	
	Range	17 - 38		21 - 43		21 - 40	
LAD2	Mean $\pm$ SD	35.47 $\pm$ 6.46		37.87 $\pm$ 6.54		37.27 $\pm$ 6	
	Range	25 - 52		28 - 52		28 - 52	
RAD1	Mean $\pm$ SD	32.23 $\pm$ 5.75		28.37 $\pm$ 5.24		28.97 $\pm$ 3.74	
	Range	25 - 45		21 - 45		25 - 45	
RAD2	Mean $\pm$ SD	38.13 $\pm$ 6.54		35.17 $\pm$ 6.32		34.97 $\pm$ 5.13	
	Range	28 - 51		28 - 51		28 - 55	
mPAP	Mean $\pm$ SD	18.37 $\pm$ 4.8		14.57 $\pm$ 6.135		14.77 $\pm$ 4.75	
	Range	30-Aug		28-Aug		25-Sep	
RVSP	Mean $\pm$ SD	28.93 $\pm$ 4.43		23.53 $\pm$ 5.513		15.83 $\pm$ 4.17	
	Range	20 - 40		15 - 40		30-Oct	
RV	No RV	4	13.30%	16	53.30%	15	50%
	Mild RV	21	70.00%	14	46.70%	15	50%
	Moderate	5	16.70%	0	0.00%	0	0.00%
Residual shunt	Negative	-		30	100.00%	30	100.00%
	Positive	-		0	0.00%	0	0.00%



**Figure 1** Comparison between P wave duration, PR interval and QRS duration before closure, 1 month and 1 year after closure.



**Figure 2** Comparison between RBBB before closure, 1 month and 1 year after closure.

The Aorta, mitral valve and tricuspid valve were not encroached on by the occluder in any patient in the study. The caval veins, right pulmonary veins, and coronary sinus drained freely in all patients during the 1 year follow-up period.

Other echocardiographic parameters: RVD1 (horizontal RV dimension), TAPSE, tissue Doppler velocities:  $E$  (Peak diastolic velocity during early filling),  $A$  (Peak diastolic velocity during late filling),  $S'$  (peak systolic velocity),  $S(IVS)$  (strain from the interventricular septum),  $SR(IVS)$  (strain rate from the the interventricular septum),  $S(RV)$  (strain from RV free wall),  $SR(RV)$  (strain rate from RV free wall), RV FAC and RV Tei index, those parameters were measured only during the intermediate follow up period (1 year after device closure) and compared to the standard reference values.<sup>11,12,14-16</sup> There was no significant difference in all parameters measured 1 year after closure to the normal reference value.

## Discussion

Atrial septal defects account for 5–10% of all congenital heart defects. Although surgical closure of secundum type ASD has been considered the standard treatment for more than 45 years with very low rate of complication,<sup>17</sup> trans-catheter ASD closure has become an important alternative to surgical repair with an excellent outcome.<sup>3,18</sup>

The present study demonstrates an excellent intermediate outcome of trans-catheter closure of secundum type ASDs during a follow-up period up to 1 year. The study included 30 patients (12 males and 18 females) with median age of 10 years; all the patients had successful device closure (100%) with no embolization or residual shunts till 1 year after device closure.

Device embolization, malposition and residual shunts are well known complications that can be avoided by proper sizing and TEE guidance.<sup>19</sup> Following ASD device closure right heart volume load is decreased. Thus, reduction in PAP and right heart cavity dimensions is established.<sup>4,20,21</sup> Previous studies have shown a significant cardiac remodeling early after percutaneous ASD closure.<sup>23</sup> In our study, we compared ECG, echocardiographic parameters before device closure, 1 month and 1 year after closure. The current study showed a highly significant reduction in the right sided dimensions and pressures including RVEDD, RVSP and mean PAP after 1 month, the reduction in RVEDD and RVSP continued significantly after one year but no significant difference were reported for mean PAP.

Walker et al.,<sup>22</sup> showed that cardiac remodeling occurs quite quickly after ASD device closure. Reduced right atrial and ventricular volumes are apparent within 1 month.<sup>22</sup> Varma et al.,<sup>23</sup> showed that the remodeling process appears to continue for at least 1 year and is more advanced in the right ventricle than the right atrium. Furthermore, the magnitude of right atrial remodeling is inversely related to patient age at the time of closure, as demonstrated in another study that reported persistent right atrial dilation in up to 64% of patients who underwent late ASD closure, which in turn was associated with elevation of brain natriuretic peptide levels and right ventricular diastolic dysfunction. All these data clearly argue for early and timely closure of ASDs at the time of diagnosis.<sup>23</sup> In the current study there was a highly statistically significant increase in the LVEDD after 1 month (6%), but there was no significant difference after 1 year as compared to 1 month follow up, also there was highly significant improvement in the ejection fraction 1 month after closure and there was no decline in the ejection fraction at 1 year, also we were able to show highly significant increase in the horizontal LAD and vertical LAD through the follow up period at 1 month but no significant difference at 1 year follow up compared to 1 month follow up.

Several studies showed similar results regarding improvement in cardiac geometric remodeling after ASD device closure, Yew and Wilson<sup>24</sup> showed that ASD trans-catheter device closure resulted in the increase in LV size and LV ejection fraction.<sup>24</sup> Pascotto et al.,<sup>3</sup> reported a 30% reduction in the RVEDD/LVEDD ratio (an indicator of cardiac geometry) 6 months after closure.<sup>3</sup> Kaya et al.,<sup>4</sup> found statistically significant reductions in RVEDD and systolic PAP and a significant increase in left ventricular end-diastolic dimension (LVEDD) during 1 year of follow-up.<sup>4</sup> Mehmet et al.,<sup>19</sup> found a significant increase in LVEDD (7%), a significant reduction in RVEDD (14%), and a significant reduction (24%) in the RVEDD/LVEDD ratio.<sup>19</sup> Hanninen et al.,<sup>25</sup> found statistically significant reductions in right ventricular end-diastolic dimension (RVEDD) and a significant increase in left ventricular end-diastolic dimension (LVEDD) during 3 years of follow-up evaluation.<sup>25</sup> Ströker et al.,<sup>26</sup> found that before closure, ASD patients had a higher right ventricular end-diastolic diameter (RVEDD), right (RA) and left atrial (LA) dimensions, and PASP when compared to controls. After closure, RVEDD and PASP decreased but not normalized whereas LVEDD and E/A-ratio increased.<sup>26</sup>

In the current study, the RAD showed a highly statistically significant decrease at 1 month follow up where the horizontal RAD decreased at 1 month and continued to decrease significantly after 1 year while the vertical RAD decreased significantly after 1 month but no significant difference at 1 year. Henry et al.,<sup>27</sup> conducted a study including 38 patients who underwent successful ASD closure and showed a highly statistically significant reduction in the RAD and RV dimension in a follow up period of 3-6 months.<sup>27</sup> The current study also evaluated RV dimensions quantitatively. Wilson et al.,<sup>28</sup> investigated RV size quantitatively by subjective TTE assessment. Before closure,

3% of the cohort had a normal RV size, 35% had a mildly dilated RV, 54% had a moderately dilated RV, and 7% had a severely dilated RV. At the last follow-up evaluation, RV had returned to normal for 75%, 19% had persistent mildly dilated RV, 5% had a moderately dilated RV, and 1% had a severely dilated RV.<sup>28</sup>

Veldtman et al.,<sup>6</sup> also showed that only 29% of their patients had persistent RV enlargement 1 year after percutaneous ASD closure.<sup>6</sup> Mehmet et al.,<sup>19</sup> also showed that only 33% of the patients had persistent RV enlargement at a 2-year follow up assessment.<sup>19</sup> In agreement with other studies, the current study confirmed that the RV generally decreased in size after ASD closure in children and adult patients. In the current study; before closure 13.3% had a normal RV, 70% had a mildly dilated RV and 16.7% had a moderately dilated RV. At 1 month follow up 53.3% had a normal RV, 46.7% had a mildly dilated RV and there were no patients having moderately dilated RV; while 1 year after ASD closure 50% had normal RV and 50% had mildly dilated RV and there were no patients having moderately dilated RV.

Previous studies have shown that persistent RV enlargement continues in approximately 50% of both adults and children after surgical treatment despite elimination of right heart volume load.<sup>29</sup> This situation can be explained by a few mechanisms including myocardial changes due to long-term volume load, functional abnormalities due to cardiopulmonary bypass, and geometric modifications of the heart due to opening of the pericardium. Pearlman et al.,<sup>30</sup> investigated this phenomenon of persistent RV enlargement after surgical ASD closure and showed the importance of early treatment specifically for patients older than 40 years.<sup>30</sup>

As a non invasive marker, P-wave duration and PR interval are especially useful in predicting atrial arrhythmias.<sup>31-34</sup> Arrhythmias, particularly atrial fibrillation and flutter, are significant causes of morbidity among patients with ASD. A few studies evaluating electrocardiographic (ECG) variables among patients with Secundum-type ASD have demonstrated an increase in P-wave duration. After comparing 62 patients with Secundum-type ASD and 47 healthy individuals, Guray et al.<sup>35</sup> reported that P wave duration and PR interval were prolonged for patients with Secundum-type ASD due to mechanical and electrical changes in the atrial myocardium<sup>35</sup>. The reasons for the increase in P-wave duration in patients with ASD may be increased atrial stretch, atrial dilation, or atrial conduction disturbance. Guray et al.<sup>35</sup> also demonstrated a reduction in P wave duration after surgical ASD closure.<sup>35</sup>

Mehmet et al.,<sup>19</sup> was the first to demonstrate statistically significant reductions in P wave duration and PR interval after trans-catheter closure of ASD. Trans-catheter ASD closure can reverse electrical and mechanical changes in the atrial myocardium and result in a reduction in P wave duration and PR interval.<sup>19</sup> In the current study we were able to show highly statistically significant reduction in the P wave duration and PR interval; the P wave duration was reduced from a mean of 107 +/- 19.62 ms to a mean of 103.8±19.17ms after 1 month (P = 0.005) and after 1 year reduced to a mean of 77±14.18(P=0.000). The PR interval was reduced from a mean of 177.97±21.932ms to a mean of 170.33±19.8ms 1 month after closure (P = 0.000) and to a mean of 160.33 ± 26.06 ms 1 year after closure (P=0.017). The current study also showed significant reduction in the PR interval value after 1 month (P = 0.000) and after 1 year (P=0.017) as well as for the QRS duration which decreased after 1 month from a mean of 134.40±4.97 ms to a mean of 127.8±4.4 ms (P= 0.000) and after 1 year decreased to a mean of 119.87±4.12 ms (P=0.000). R-wave amplitude in lead V1 did not change significantly and there was no significant change in RBBB morphology during one-year follow up.

Veldtman et al.,<sup>6</sup> studied 40 patients who had successful ASD trans-catheter device closure and showed after 1 month of follow up a highly statistically significant reduction in the PR interval (P= less than 0.001) and QRS duration (P= 0.001). R-wave amplitude in lead V1 did not change significantly during the one-year follow-up and there was no significant change in RBBB morphology.<sup>6</sup>

Reductions in right heart volume overload and improvements in right atrium and ventricular diameters after percutaneous ASD closure decrease the prevalence of cardiac arrhythmias.<sup>2,28</sup> However, other studies demonstrated increased prevalence of atrial arrhythmias due to unknown causes after surgical ASD closure.<sup>36,37</sup> Gatzoulis et al.,<sup>37</sup> suggested that older age and mean PAP are risk factors for persistent atrial arrhythmias and the development of new atrial arrhythmias after surgical ASD closure.<sup>37</sup> Du et al.,<sup>2</sup> in their study comparing surgical and trans-catheter methods, reported a higher occurrence of cardiac arrhythmias in the surgical group, although the difference did not reach statistical significance.<sup>2</sup> Wilson et al.,<sup>28</sup> documented the presence of arrhythmias (most frequently atrial fibrillation and atrial flutter) in 26 of 211 patients (12%) before trans-catheter ASD closure. During a mean follow up period of 1.8 years, arrhythmias had resolved for 16 patients and new arrhythmias had occurred for 6 (3%) patients after ASD closure.<sup>28</sup>

Johnson et al.,<sup>38</sup> reported an incidence of 5.2% of arrhythmias (32 patients among 610 patients) in the 4 months following device placement, including 29 patients with atrial tachyarrhythmias (22 atrial fibrillation, 7 atrial flutter), 1 with junctional tachycardia, and 2 with heart block. Among other findings, the average P-wave duration was increased on intermediate follow-up as compared to early follow-up (P < 0.001). Development of new-onset 1st degree AV Block after the procedure was associated with an increased risk of ATs post-procedure (P < 0.0001).<sup>38</sup>

Mehmet et al.,<sup>19</sup> assessed arrhythmias over a longer follow-up period (mean 2-years). Before ASD closure, three patients had paroxysmal atrial fibrillation, one patient had supraventricular tachycardia, and two patients had frequent atrial extra beats. After ASD closure, arrhythmias were eliminated in five patients, and only one patient had ongoing paroxysmal atrial fibrillation.<sup>19</sup> In the current study, no patient had a history of arrhythmia nor developed any arrhythmia after device closure during 1 year follow up period. This may be due to limited number of patients included in the study.

Silversides et al.,<sup>39</sup> reported that the greatest likelihood of remaining arrhythmia free was found in patients without a history of arrhythmia and those younger than 40 years at the time of ASD closure. They did not investigate ECG parameters such as P wave duration.<sup>39</sup> Quantification of the RV function is an important prognostic factor especially in patients with intracardiac shunts or other RV diseases. RV systolic function has been evaluated using several parameters, namely, RIMP, TAPSE, 2D RV FAC, tissue Doppler-derived tricuspid lateral annular systolic velocity (S'), and longitudinal strain and strain rate.

Strain and Strain rate measurements are a novel approach to quantitatively assess myocardial wall motion, which can also be applied to the right ventricle. This method allows exact and objective assessment of global and regional myocardial function. Volume overload is associated with increased strain values, which return to normal after abolishment of the volume overload. Smita et al.,<sup>5</sup> assessed global longitudinal strain (GLS), global longitudinal strain rate (GLSR), and regional peak systolic strain (PSS) of right ventricle in 33 ASD patients. Global longitudinal strain of the right ventricle

was significantly higher than in the control group (23.4+/-4.5 vs.21.4+/-4.3%, P = 0.05). After interventional closure of the defect, a significant reduction of the global RV strain and the PSS of the lateral mid, the lateral apical, and the septal apical segment were observed. There was no significant change in the global RV SR.<sup>5</sup> Smita et al.,<sup>5</sup> reported that cardiac remodeling is an early post-interventional effect and appears during the first months after ASD closure, so a 3-month follow-up period seems to be sufficient to reflect the major part of remodeling of the right ventricle.<sup>5</sup> The end-diastolic RV diameters decreased significantly after ASD closure by abolishment of the left-to-right shunt. The consecutive improvement of LV filling resulted in an increase in LV end-diastolic diameter. The patients with chronic RV volume overload due to an ASD have increased strain values when compared with age-matched healthy adults. The increased myocardial strain values return to normal after ASD closure. Vitarelli et al.,<sup>40</sup> reported that RV longitudinal strain were significantly higher than control group before percutaneous closure and decreased significantly after closure.<sup>40</sup>

Our study showed that longitudinal strain and strain rate of the RV free wall and interventricular septum measured 1year after ASD device closure showed no significant difference from normal values. Lange et al.,<sup>5</sup> reported that TAPSE and RV systolic velocity(S ' ) decreased significantly after ASD closure indicating reverse RV remodeling.<sup>5</sup> Ağaç et al.,<sup>8</sup> studied 20 patients who underwent percutaneous ASD closure by Amplatzer device. Echocardiography was done before closure and 1month after closure. S' (peak systolic velocity) had a mean 16.9 ± 3.2cm/sec before closure vs. 14.3 ± 3.3cm/sec after closure (P < 0.05), E' (early diastolic tricuspid annular velocity) had a mean 15.3 ± 3.1cm/sec before closure vs. 13.4 ± 2.4cm/sec after closure (P < 0.05), A' (late diastolic tricuspid annular velocity) had a mean 16.2 ± 5.4cm/sec before closure vs. 14.3 ± 6.3cm/sec after closure (P < 0.05, and TAPSE had a mean 29.9 ± 6.2mm before closure vs. 22.4 ± 7.4mm after closure (P < 0.001). He concluded that Closure of ASD by using Amplatzer devices led to decrease tissue Doppler-derived tricuspid annular velocities and TAPSE within 1month of closure.<sup>8</sup>

Our study showed that TAPSE and RV tissue Doppler velocities 1year after closure have no significant difference from normal values, which suggest improvement of the RV systolic and diastolic function after transcatheter closure. The results were compared with normal values due to lack of these measurements before ASD closure.

Kalimanovska Ostric et al.,<sup>41</sup> reported that Tei index as a parameter of global myocardial function improved after closure (0.53±0.07 before vs. 0.39±0.04 a year after, P=0.000). These values approached to those in healthy controls (0.39±0.04 a year after vs. 0.38±0.04 in healthy controls, P=ns) indicating that closure of ASD improves global RV function.<sup>41</sup> Wu et al.,<sup>42</sup> reported that while LV Tei index improved soon after the procedure, RV Tei index worsened until 1month after the procedure, then recovered by the 3-month follow-up visit indicating that Device closure of ASDs caused rapid improvement of LV function, but RV function underwent transient deterioration, probably due to delayed changes in RV ventricular mass in the face of acute volume reduction.<sup>42</sup> Our study showed non-significant difference between RV Tei index 1year after ASD closure and normal values.

## Conclusion

Trans-catheter ASD closure has become an important alternative to surgical repair in the management of patients with Secundum-type ASD. It is a simple, effective technique with low complication rate. Transcatheter ASD device closure leads to significant improvement in

the heart cavity dimensions in particular the right sided dimensions in children and adults in the intermediate –term follow up period. Novel parameters for assessment of RV function are promising and appear to be helpful for the assessment of RV function and its response to correction of volume overload.

## Acknowledgments

None.

## Conflicts of interest

Author declares there are no conflicts of interest.

## Funding

None.

## References

1. Howaida G, Louis I, Ronald G, et al. Sizing of Atrial Septal Defects to Predict Successful Closure with Transcatheter Cardio SEAL device. *Tex Heart Inst J*. 2001;28(3):177–182.
2. Du ZD, Cao QL, Koenig P, et al. Speed of normalization of right ventricular volume overload after transcatheter closure of atrial septal defect in children and adults. *Am J Cardiol*. 2001;88(12):1450–1453.
3. Pascotto M, Santoro G, Cerrato F, et al. Time course of cardiac remodeling following transcatheter closure of atrial septal defect. *Int J Cardiol*. 2006;112(3):348–352.
4. Kaya MG, Baykan A, Dogan A, et al. Intermediate-term effects of transcatheter secundum atrial septal defect closure on cardiac remodeling in children and adults. *Pediatr Cardiol*. 2010;31(4):474–482.
5. Smita RJ, Werner S, Thomas B, et al. Two dimensional strain and strain rate imaging of the right ventricle in adult patients before and after percutaneous closure of atrial septal defects. *Eur J Echocardiogr*. 2009; 10(4):499–502.
6. Veldtman GR, Razack V, Siu S, et al. Right ventricular form and function after percutaneous atrial septal defect device closure. *J Am Coll Cardiol*. 2001;37(8):2108–2113.
7. Lange SA, Braun MU, Schoen SP, et al. Latent pulmonary hypertension in atrial septal defect: Dynamic stress echocardiography reveals unapparent pulmonary hypertension and confirms rapid normalization after ASD closure. *Neth Heart J*. 2013;21(7–8):333–843.
8. Ağaç MT, Akyüz AR, Acar Z, et al. Evaluation of right ventricular function in early period following transcatheter closure of atrial septal defect. *Echocardiography*. 2012;29(3):358–362.
9. Dandel M, Lehmkuhl H, Knosalla C, et al. Strain and Strain Rate Imaging by Echocardiography – Basic Concepts and Clinical Applicability. *Curr Cardiol Rev*. 2009;5(2):133–148.
10. Feigenbaum H, Armstrong W, Ryan T. Feigenbaum's Echocardiography. 2005;6th (edn), 5:133–148.
11. Rudski GL, Lai WW, Afilalo J, et al. Guidelines for the Echocardiographic Assessment of the Right Heart in Adults. *J Am Soc Echocardiogr*. 2010;23(7):685–713.
12. Seward J, Oh B, Jae K, et al. Echo Manual, Transthoracic Echocardiography: M-mode, Two-Dimensional, and Three-Dimensional. 3rd (edn.). 2006;2:7–28.
13. Therien J, Webb GD, Braunwald E. Congenital heart diseases in adult; textbook of cardiovascular medicine. 6th (edn.). 2001;1592–1621.
14. Horton KD, Meece RW, Hill JC. Assessment of the right ventricle by echocardiography: a primer for cardiac sonographers. *J Am Soc Echocardiogr*. 2009;22(7):776–792.

15. Benjamin WE, Frank C, Patrick W, et al. Echocardiography in Pediatric and Adult Congenital Heart Disease. 2012; 42–43.
16. Koestenberger M, Friedberg M, Wranne B, et al. Non-Invasive Imaging for Congenital Heart Disease: Recent Innovations in Transthoracic Echocardiography. *J Clin Exp Cardiol*. 2012;S8:2–15.
17. Du ZD, Hijazi ZM, Kleinman CS, et al. Comparison between transcatheter and surgical closure of secundum atrial septal defect in children and adults: results of a multicenter nonrandomized trial. *J Am Coll Cardiol*. 2002;39(11):1836–1844.
18. Suchon E, Pieculewicz M, Tracz W, et al. Transcatheter closure as an alternative and equivalent method to the surgical treatment of atrial septal defect in adults: Comparison of early and late results. *Med Sci Monit*. 2009;15(12):612–617.
19. Mehmet G, Ali B, Ali D. Intermediate -term effects of transcatheter secundum atrial septal defect closure on cardiac remodeling in children and adults; *Pediatr cardiol* . 2010;31:474–482.
20. Omeish A, Hijazi ZM. Transcatheter closure of atrial septal defect in children and adults using the Amplatzer septal occluder. *J Interv Cardiol*. 2001;14(1):37–44.
21. Cowley CG, Lloyd TR, Bove EL, et al. Comparison of results of closure of secundum atrial septal defect by surgery versus Amplatzer septal occluder. *Am J Cardiol*. 2001; 88(5):589–591.
22. Walker RE, Moran AM, Gauvreau K, et al. Evidence of adverse ventricular interdependence in patients with atrial septal defects. *Am J Cardiol* . 2004;93(11):1374–1377.
23. Varma C, Benson LN, Silversides C, et al. Outcomes and alternative techniques for device closure of the large secundum atrial septal defect. *Catheter Cardiovasc Interv*. 2004;61(1):131–139.
24. Yew G, Wilson NJ. Transcatheter atrial septal defect closure with the Amplatzer septal occluder: five-year follow-up. *Catheter Cardiovasc Interv* . 2005;64(2):193–196.
25. Hanninen M, Kmet A, Taylor DA, et al. Atrial septal defect closure in the elderly is associated with excellent quality of life, functional improvement, and ventricular remodeling. *Can J Cardiol*. 2011;27(6):698–704.
26. Ströker E, Van De Bruaene A, De Meester P, et al. Transcatheter device closure of atrial septal defects in patients above age 60. *Acta Cardiol* . 2013;68(2):127–32.
27. Henry WK, David TB, Mark CJ. Resolution of right heart enlargement after closure of secundum atrial septal defect with transcatheter technique. *J Am Coll Cardiol*. 2001;38(5):1528–1532.
28. Wilson NJ, Smith J, Prommete B, et al. Transcatheter closure of secundum atrial septal defects with the Amplatzer septal occluder in adults and children-follow-up closure rates, degree of mitral regurgitation and evolution of arrhythmias. *Heart Lung Circ* . 2008;17(4):318–324.
29. Ning SB, Fazal H, Cook D, et al. Right ventricular size and ventricular septal motion after repair of atrial septal defect in children. *Can J Surg*. 1984;27(4):395–398.
30. Pearlman AS, Borer JS, Clark CE, et al. Abnormal right ventricular size and ventricular septal motion after atrial septal defect closure: etiology and functional significance. *Am J Cardiol*. 1978;41(2):295–301.
31. Brandenburg RO, Holmes DR, Brandenburg RO, et al. Clinical follow-up study of paroxysmal supraventricular tachyarrhythmias after operative repair of secundum type atrial septal defect in adults. *Am J Cardiol*. 1983;51(2):273–276.
32. Ho TF, Chia EL, Yip WC, et al. Analysis of P-wave and P-wave dispersion in children with secundum atrial septal closure. *Circulation*. 2001;106:1821–1826.
33. Carcagni` A, Presbitero P. Transcatheter closure of secundum atrial septal defects with the Amplatzer occluder in adult patients. *Ital Heart J* . 2002;3(3):182–187.
34. Guray U, Guray Y, Mecit B, et al. Maximum P-wave duration and P- wave dispersion in adult patients with secundum atrial septal defect: the impact of surgical repair. *Ann non invasive Electrocardiol* . 2004;9(2):136–141.
35. Guray U, Guray Y, Yilmaz MB, et al. Evaluation of P-wave duration and P-wave dispersion in adult patients with secundum atrial septal defect during normal sinus rhythm. *Int J Cardiol*. 2003;91(1):75–79.
36. Brandenburg RO, Holmes DR, Brandenburg RO, et al. Clinical follow-up study of paroxysmal supraventricular tachyarrhythmias after operative repair of secundum type atrial septal defect in adults. *Am J Cardiol*. 1983;51(2):273–276.
37. Gatzoulis MA, Freeman MA, Siu SC, et al. Atrial arrhythmia after surgical closure of atrial septal defects in adults. *N Engl J Med*. 1999;340(11):839–846.
38. Johnson JN, Marquardt ML, Ackerman MJ, et al. Electrocardiographic changes and arrhythmias following percutaneous atrial septal defect and patent foramen ovale device closure. *Catheter Cardiovasc Interv*. 2011;78(2):254–261.
39. Silversides CK, Haberer K, Siu SC, et al. Predictors of atrial arrhythmias after device closure of secundum type atrial septal defects in adults. *Am J Cardiol*. 2008;101(5):683–687.
40. Vitarelli A, Sardella G, Roma AD, et al. Assessment of right ventricular function by three-dimensional echocardiography and myocardial strain imaging in adult atrial septal defect before and after percutaneous closure. *Int J Cardiovasc Imaging*. 2012;28(8):1905–1916.
41. Kalimanovska O, Nastasovic T, Deljanin I, et al. Controversial effects of atrial septal defect closure in adults. *Eur J Echocardiogr*. 2011;32:49.
42. Wu ET, Akagi T, Taniguchi M, et al. Differences in right and left ventricular remodeling after transcatheter closure of atrial septal defect among adults. *Catheter Cardiovasc Interv*. 2007;69(6):866–871.