

Severe aortic regurgitation in degenerative bioprosthetic aortic homograft treated by valve in valve

Abstract

Transcatheter aortic valve implantation (TAVI) is increasingly used to treat bioprosthetic degenerated valves. We report a 79 year old man who had a redo aortic valve replacement using a homograft bioprosthetic valve, presented with recurrent heart failure and severe aortic regurgitation (AR), due to degeneration of his aortic homograft, and because of his age and comorbidities he was labeled as a high risk case. Therefore, he underwent a transfemoral TAVI using core valve as "valve in valve" with an excellent final result and the his AR disappeared completely.

Keywords: transcatheter aortic valve implantation, aortic homograft, aortic regurgitation, bioprosthetic valve, heart failure, valve in valve

Volume 6 Issue 2 - 2016

Mohammed Balghith

King Saud Bin Abdulaziz University for Health Sciences, Saudi Arabia

Correspondence: Mohammed Balghith, King Saud Bin Abdulaziz University for Health Sciences, Riyadh, P O Box 24490, Saudi Arabia, Tel 966504147204, Email mbalghith@hotmail.com

Received: June 29, 2016 | **Published:** July 05, 2016

Introduction

Bioprosthetic valves are increasingly used in patients with aortic valve stenosis. In comparison with mechanical valves, these valves have a lower risk of thromboembolism and no need for anticoagulation.^{1,2} However, the durability is limited; the best current valves are expected to degenerate in 10 to 20 years, resulting in stenosis or regurgitation or combined pathology. Surgical aortic valve replacement is the gold standard therapy for these patients. However, re-operative morbidity and mortality risk is high, not only because of the complexity of repeated surgical procedures but because of advanced age and other associated illnesses they have.³⁻⁵ Transcatheter aortic valve implantation (TAVI) for native valve aortic stenosis has become as a viable, less invasive, alternative option instead of open heart surgery in selected high risk patients.⁶ Recently, TAVI within failed surgically implanted bioprostheses, Valve in Valve has proven feasible.⁷⁻¹⁰

Case history

79 y old male patient, known to have diabetes mellitus, end stage renal failure and chronic obstructive pulmonary disease, this patient had aortic valve replacement (AVR) 15years prior, but because of infective endocarditis 7years ago, he underwent a redo AVR (Aortic valve Bioprosthesis) using a 25mm cry preserved aortic homograft implanted as a full root in another hospital. Patient was admitted with severe heart failure and pulmonary edema. His Echocardiogram showed severe AR (Figure 1). Patient was treated aggressively with anti-failure medications. The case discussed in heart team and both options AVR vs TAVI were raised in this high risk patient, with STS score 18. Both the heart team and Family preferred TAVI, According to sizing application this homograft valve will fit with Size 29mm Core Valve, The CT-scan measurements showed an aortic annulus size 21-25mm at different level, Perimeter range from 71-73, 3mm, Aortic valve area 2.9 cm², and a heavily calcified a tube-like aorta (Figure 2). No clear sinus or junction was seen by CT. A trans-femoral approach for Valve in Valve was used. A 29 mm Medtronic Core valve was deployed and the landmark was the calcium in the root. Unfortunately, it migrated up-ward most probably due to the rigidity of the homograft tube and no real narrowing or calcified leaflet to anchored the valve (Figure 3). Therefore we used another 29 core valve and deployed it through the first one which was well seated in ascending aorta

as support. This method of support was very successful for final deployment (Figure 4). It was similar to the melody valve deployment in treating pulmonary regurgitation. There was no aortic regurgitation by Echocardiogram (Figure 5). Patient was very stable and discharged home after 48 hours.

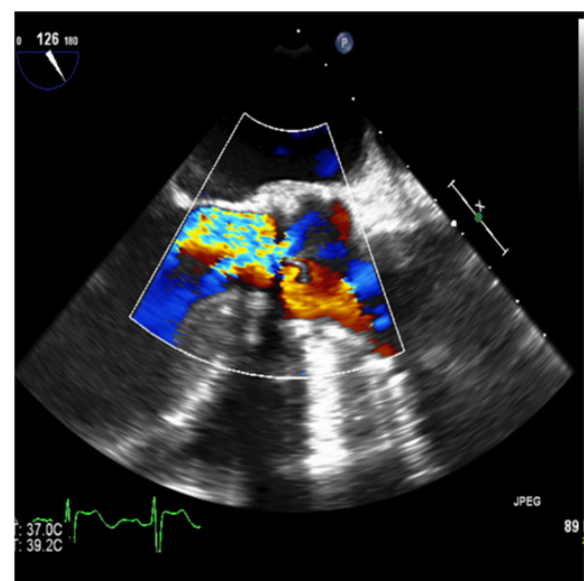


Figure 1 Echocardiogram image showed a color Doppler with a severe aortic regurgitation.

Discussion

Transcatheter aortic valve implantation (TAVI) has become a recognized treatment for patients with severe aortic stenosis (AS) who are at high risk from conventional aortic valve replacement surgery.¹¹ Surgical bioprosthetic valves are commonly divided into two types, stented and stentless valves. Stentless surgical valves are mostly made from porcine or human aortic root tissue. They are liable to have more laminar flow and less transvalvular gradients than stented valves, one important issue here is the durability of those valves which are limited. The sizing of stentless homografts is even less standardized. The most common stentless valves encountered in the Global Valve-in-Valve Registry were homografts (30%).^{12,13}

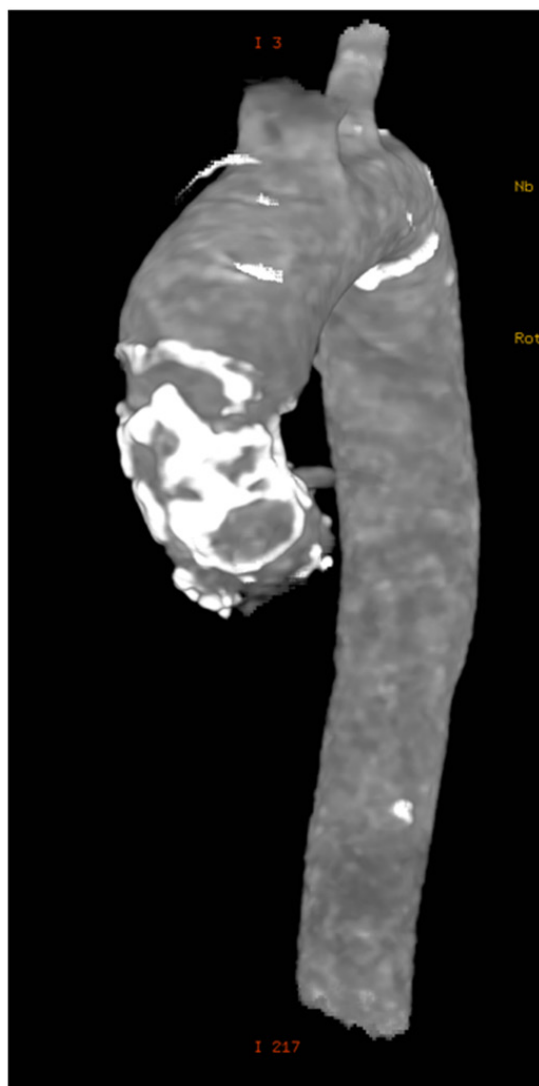


Figure 2 Ct-scan image of ascending aorta with heavy calcification and full root replacement.

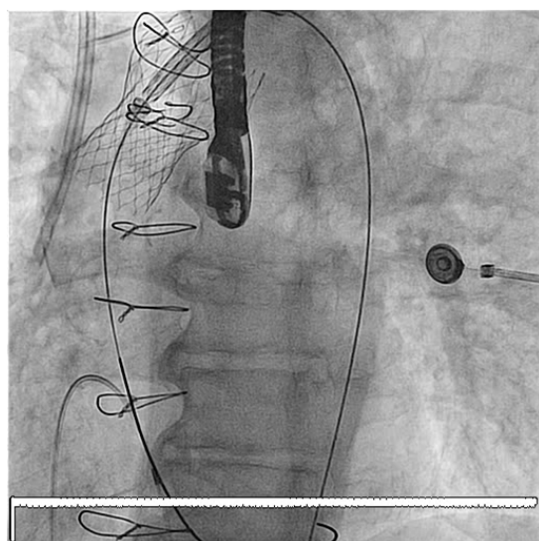


Figure 3 The Core Valve migrated up to the ascending aorta immediately after its deployment.

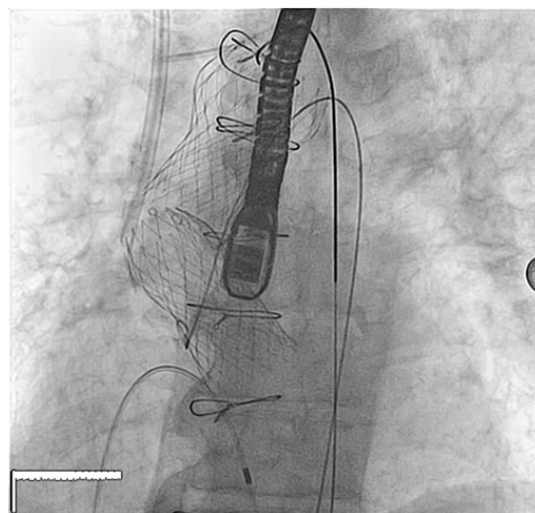


Figure 4 Final deploymement of Valve in valve , showed how the second valve was will supported by the first valve.

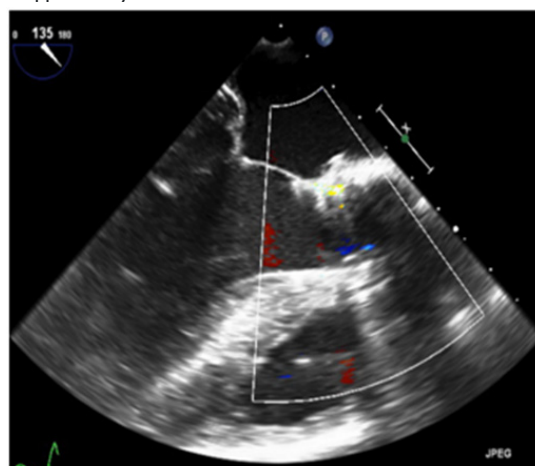


Figure 5 Echocardiogram showed a colored Doppler without aortic regurgitation.

As with all bioprosthetic aortic valve substitutes, homografts are prone to late degeneration characterized by dense calcification and valve dysfunction. Reoperation in patients with prior homograft aortic root replacement may carry a substantial risk, particularly in elderly patients and patients with significant comorbidities. Even in relatively fit patients, it can be technically challenging, especially where there have been multiple previous procedures or when there is calcification around the coronary ostia. A small number of reports.^{14,15} have described the use of TAVI as a valve-in-valve procedure for structural degeneration of bioprosthesis, predominantly in stented prostheses.^{16,17} However in our patient there was few challenges, the aortic root was fully replaced by the homograft and the annulus was large with wide open AR and calcified wall, the method we used for ViV after migration of the first core valve was very effective in keeping the valve in the correct position, recently with development of retrievable Evolute R valve, such difficult case might suitable for this device.

Conclusion

Valve in valve is an approved treatment for degenerated Bioprosthetic valves. However, failure (mostly insufficiency) of a previous homograft aortic valve poses a challenge for any

interventional treatment. In selected patients, TAVI can be a feasible alternative for high risk re-operation. TAVI may also be considered in some cases of native aortic insufficiency where there is favorable anatomy, in our experience, using this method of ViV in a degenerated Homograft with AR is a very challenging but it is safe and effective.

Acknowledgments

None.

Conflicts of interest

None.

Funding

None.

References

1. Jones JM, O'kane H, Gladstone DJ, et al. Repeat heart valve surgery: risk factors for operative mortality. *J Thorac Cardiovasc Surg.* 2001;122(5):913-918.
2. Maganti MRV, Armstrong S, Feindel CM, et al. Redo valvular surgery in elderly patients. *Ann Thorac Surg.* 2008;87(2):521-525.
3. Leontyev S, Borger MA, Davierwala P, et al. Redo aortic valve surgery: early and late outcomes. *Ann Thorac Surg.* 2011;91(4):1120-1126.
4. Bonow RO, Carabello BA, Kanu C, et al. ACC/AHA 2006 guidelines for the management of patients with valvular heart disease: a report of the American College of Cardiology/American Heart Association Task Force on Practice Guidelines. *Circulation.* 2006;114(5):e84-e231.
5. Ruel M, Kulik A, Rubens FD, et al. Late incidence and determinants of reoperation in patients with prosthetic heart valves. *Eur J Cardiothorac Surg.* 2004;25(3):364-370.
6. Webb JG, Wood DA. Current status of transcatheter aortic valve replacement. *J Am Coll Cardiol.* 2012;60(6):483-492.
7. Webb JG, Wood DA, Ye J, et al. Transcatheter valve-in-valve implantation for failed bioprosthetic heart valves. *Circulation.* 2010;121(16):1848-1857.
8. Gurvitch R, Cheung A, Ye J, et al. Transcatheter valve-in-valve implantation for failed surgical bioprosthetic valves. *J Am Coll Cardiol.* 2011;58(21):2196-2209.
9. Piazza N, Bleiziffer S, Brockmann G, et al. Transcatheter aortic valve implantation for failing surgical aortic bioprosthetic valve: from concept to clinical application and evaluation (part 1). *JACC Cardiovasc Interv.* 2011;4(7):721-732.
10. Piazza N, Bleiziffer S, Brockmann G, et al. Transcatheter aortic valve implantation for failing surgical aortic bioprosthetic valve: from concept to clinical application and evaluation (part 2). *JACC Cardiovasc Interv.* 2011;4(7):733-742.
11. Chan PH, Di Mario C, Davies SW, et al. Transcatheter Aortic Valve Implantation in Degenerate Failing Aortic Homograft Root Replacements. *J Am Coll Cardiol.* 2011;58(16):1729-1730.
12. Dunning J, Graham RJ, Thambyrajah J, et al. Stentless vs. stented aortic valve bioprostheses: a prospective randomized controlled trial. *Eur Heart J.* 2007;28(19):2369-2374.
13. Kallikourdis A, Jacob S. Is a stentless aortic valve superior to conventional bioprosthetic valves for aortic valve replacement? *Interact Cardiovasc Thorac Surg.* 2007;6(5):665-672.
14. Gotzmann M, Mugge A, Bojara W. Transcatheter aortic valve implantation for treatment of patients with degenerated aortic bioprosthesis-valve-in-valve technique. *Catheter Cardiovasc Interv.* 2010;76(7):1007-1008.
15. Khawaja MZ, Haworth P, Ghuran A, et al. Transcatheter aortic valve implantation for stenosed and regurgitant aortic valve bioprostheses. *J Am Coll Cardiol.* 2010;55(2):91-101.
16. Walther T, Falk V, Dewey T, et al. Valve-in-a-valve concept for transcatheter minimally invasive repeat xenograft implantation. *J Am Coll Cardiol.* 2007;50(1):56-60.
17. Wenaweser P, Buellesfeld L, Gerckens U, et al. Percutaneous aortic valve replacement for severe aortic regurgitation in degenerated bioprosthesis: the first valve in valve procedure using the Corevalve Revalving system. *Catheter Cardiovasc Interv.* 2007;70(5):760-764.