

Radial Artery Pseudoaneurysm: A Rare Complication after Transradial Coronary Angiography

Abstract

The radial approach for diagnostic and therapeutic procedures offers clear advantages in terms of vascular complications. The pseudoaneurysm following radial artery access is an extremely uncommon complication. We report the case of a patient who developed radial artery pseudoaneurysm 7-months after coronary angiography intervention. The clinical presentation and treatment options are discussed.

Case Report

Volume 5 Issue 6 - 2016

Salma Charfeddine*, Faten Triki, Rania Hammami, Dorra Abid, Leila Abid and Samir Kammoun

Department of cardiology, Hedi Chaker university hospital, Sfax, Tunisia

*Corresponding author: Salma Charfeddine, Department of cardiology, Hedi Chaker university hospital, Sfax, Tunisia, Email: selma_charfeddine@yahoo.fr

Received: May 05, 2016 | Published: May 26, 2016

Introduction

The transradial approach has recently been recommended as the first choice to reduce access-site vascular complications during percutaneous coronary diagnostic and interventional procedures [1]. It may be preferred in anticoagulated patients to avoid those vascular complications associated with the femoral approach, which are compounded by systemic anticoagulation [2]. The radial artery pseudoaneurysm is an extremely rare complication associated with transradial access [1,3,4]. We report a case of radial artery pseudoaneurysm complicating diagnostic coronary angiography in a patient receiving therapeutic oral anticoagulation.

Case Presentation

A 64-year-old female with history of hypertension, maintained on chronic warfarin therapy after mechanical mitral valve prosthesis developed a severe tricuspid regurgitation associated with right ventricular failure symptoms. Before redux tricuspid

surgery, a diagnostic coronary angiography was performed from the right radial artery with a 5 Fr system. The procedure was performed after acenocoumarol had been stopped for 3 days. The International Normalized Ratio (INR) at the time of angiography was 1.6. The diagnostic angiography revealed no-significant atherosclerosis in coronary arteries. A bolus of 5.000 IU unfractionated heparin bolus was administered through the sheath. The vascular sheath was removed just after the procedure and a compressive dressing was performed. The patient presented 7 months later with painful swelling over the radial puncture site (Figure 1).

Colour Doppler ultrasonography demonstrated a pseudoaneurysm with partial thrombosis (Figure 2). A conservative therapy with prolonged local compression failed to close it. The patient required surgical correction. She underwent surgical excision of the pseudoaneurysm and suture of the radial artery. She remained well at follow-up after the procedure, with preserved radial arterial pulse and no residual swelling.

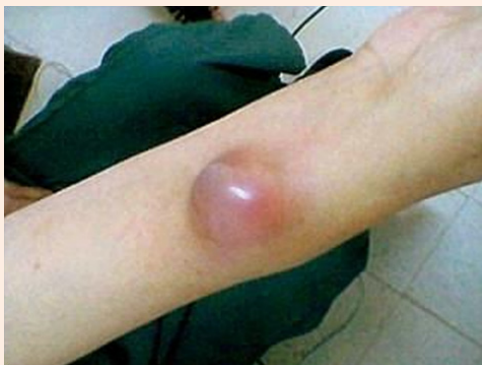

Figure 1: Image of right radial pseudoaneurysm with area of swelling noted at radial access site.




Figure 2: Doppler ultrasonography showing a pseudoaneurysm (horizontal arrow) superior to the radial artery (vertical arrow) access site.

Discussion

The transradial approach for percutaneous coronary interventions surely offers advantages in terms of access-site vascular complications. Although uncommon, these complications may not be trivial as some of them may cause serious clinical consequences such as hand ischemia, compartment syndrome and arterial rupture [4]. Previous meta-analysis found up to 1.0% rate of radial access site complications including major Hemorrhages and a 65% to 80% rate reduction over the transfemoral access [5,6]. In previous large single centre series, radial artery access clinically relevant vascular complications were around 0.4% [7,8]. Among the patients who underwent transradial procedures in the radial versus femoral access for coronary angiography and intervention in patients with acute coronary syndromes (RIVAL) trial, the only major non Hemorrhagic complication was pseudoaneurysm necessitating closure with a 0.2% incidence [6]. Pseudoaneurysm as a transradial access complication is found in the literature with a rate of 0% to 0.5%. In the largest series up to now, this kind of complication has been reported with an incidence of 0.04% [7]. The radial pseudoaneurysm is clearly uncommon when compared to transfemoral access, with less significant morbidity. It was suggested that ongoing systemic anticoagulation may predispose to radial artery pseudoaneurysm formation [1]. Furthermore, the development of radial artery pseudoaneurysm may be related to inadequate compression post procedure or alternatively to delayed bleeding complicating anticoagulation [1]. As reported previously, our patient presented with a typically painful swelling at the site of the radial access. Our patient's INR at the time of the coronary angiography was 1.6 but she received ongoing therapeutic anticoagulation just after the diagnostic procedure. Thereby, delayed bleeding and inadequate compression, may be the potential contributing factors of pseudoaneurysm constitution in this case. The diagnosis of such complication may be done immediately after the procedure or later. In this present example, the patient presented local symptoms 7 months after the procedure. A surgical intervention was required. In fact, the late diagnostic of the radial artery pseudoaneurysm is significantly associated with the need for surgical correction [4]. The management of this complication includes compression with a view to thrombosis of the false aneurysm, thrombin injection and surgical closure [9,10]. Although, the surgical treatment is relatively simple as compared to the femoral artery pseudoaneurysm, a prompt diagnosis may decrease significantly the need for surgery [1,4].

Conclusion

Although infrequent, radial-related vascular complications are possible and may not be trivial. A prompt diagnosis of a radial artery pseudoaneurysm using Doppler ultrasonography is essential to avoid further complications and to decrease the need for surgery.

References

1. Collins N, Wainstein R, Ward M, Bhagwandeem R, Dzavik V (2012) Pseudoaneurysm after transradial cardiac catheterization: case series and review of the literature. *Catheter Cardiovasc Interv* 80(2): 283-287.
2. Popovic B, Freysz L, Chometon F, Lemoine J, Elfarra M, et al. (2010) Femoral pseudoaneurysms and current cardiac catheterization: evaluation of risk factors and treatment. *Int J Cardiol* 141(1): 75-80.
3. Suchoo E, Jąkała J, Dykła D, Depukat R, Krochin M, et al. (2013) Radial artery pseudoaneurysm as an extremely rare complication associated with transradial catheterisation. *Kardiologia Pol* 71(5): 542.
4. Burzotta F, Mariani L, Trani C, Coluccia V, Brancati MF, et al. (2013) Management and timing of access-site vascular complications occurring after trans-radial percutaneous coronary procedures. *Int J Cardiol* 167(5): 1973-1978.
5. Agostoni P, Biondi-Zoccai GGL, de Benedictis ML, Rigattieri S, Turri M, et al. (2004) Radial versus femoral approach for percutaneous coronary diagnostic and interventional procedures; Systematic overview and meta-analysis of randomized trials. *J Am Coll Cardiol* 44(2): 349-356.
6. Jolly SS, Yusuf S, Cairns J, Niemelä K, Xavier D, et al. (2011) Radial versus femoral access for coronary angiography and intervention in patients with acute coronary syndromes (RIVAL): a randomised, parallel group, multicentre trial. *Lancet Lond Engl* 377(9775): 1409-1420.
7. Burzotta F, Trani C, Mazzari MA, Tommasino A, Niccoli G, et al. (2012) Vascular complications and access crossover in 10,676 transradial percutaneous coronary procedures. *Am Heart J* 163(2): 230-238.
8. Hahalis G, Tsigkas G, Kakkos S, Panagopoulos A, Tsota I, et al. (2015) Vascular Complications Following Transradial and Transulnar Coronary Angiography in 1600 Consecutive Patients. *Angiology* 67(5): 438-443.
9. Ganchi PA, Wilhelmi BJ, Fujita K, Lee WP (2001) Ruptured pseudoaneurysm complicating an infected radial artery catheter: case report and review of the literature. *Ann Plast Surg* 46(6): 647-650.
10. Komorowska-Timek E, Teruya TH, Abou-Zamzam AM, Papa D, Ballard JL (2004) Treatment of radial and ulnar artery pseudoaneurysms using percutaneous thrombin injection. *J Hand Surg* 29(5): 936-942.