

The Benefits of Attempting Chronic Total Occlusions for the Interventionalist

Keywords: Chronic total occlusion; PCI; Skills; Interventional cardiology

Editorial

Percutaneous coronary intervention (PCI) for coronary chronic total occlusions (CTOs) still represents one of the major challenges in interventional cardiology. Some interventionalists remain reluctant to attempt CTO PCIs, being these procedures considered to be costly, associated with high radiation exposure and high probability of procedural failure. In the current manuscript, we focused on the benefits of attempting CTO PCI for the interventional cardiologist and how it can greatly enhance his skills.

Percutaneous coronary intervention (PCI) for coronary chronic total occlusions (CTOs) still represents one of the major challenges in interventional cardiology [1]. A CTO is a frequent condition encountered in catheterization laboratory practice and its prevalence in patients undergoing coronary angiography was reported to range from 12-20 % [2]. Although it has been demonstrated that successful PCI was associated with an improvement of symptoms, quality of life and cardiovascular outcome [3], the majority of CTO patients are still not treated percutaneously. Furthermore, some interventionalists remain reluctant to attempt CTO PCIs, being these procedures considered to be costly, associated with high radiation exposure and high probability of procedural failure. However, we believe that in addition to providing benefits to the patient, performing CTO PCI can also greatly enhance the procedural skills of the operator.

First, the operator develops better understanding of how to acquire and interpret the angiogram, in order to define the proximal and distal cap, the quality of the coronary vessels, and the type and course of collaterals. Better understanding of coronary anatomy can translate into better diagnosis and decision making. Second, CTO PCI enhances understanding and facilitates use of various types of equipment, such as microcatheters, guide wires [4], guide catheter extensions, equipment for lesions modification (such as laser and atherectomy), snares, and equipment for management of complications (such as covered stents, coils, and micro particles) [5]. Third, the operator develops and hones skills in managing complex (CTO and non-CTO) lesions, in part by developing challenge-specific algorithms, such as algorithms for treating balloon uncrossable or balloon undilatable lesions [6]. Fourth, he/she also becomes more adept in managing potential complications, such as perforations [5,7]. CTO PCI is especially useful for developing radiation minimization strategies, such as optimal patient and X-ray machine positioning, use of low-frame fluoroscopy, and use of fixes and disposable radiation shields [8]. Fifth, procedural efficiency and safety are improved by learning to start the case with the best possible setup for success (such as upfront use of 8 French guide catheters and long sheaths) and promptly change from a failing treatment mode and by treating the most complex patient and lesion subsets. Moreover, CTO

Editorial

Volume 3 Issue 5 - 2015

Emmanouil S Brilakis¹, Marouane Boukhris^{2,3} and Alfredo R Galassi²

¹Veterans Administration North Texas Healthcare System and University of Texas Southwestern Medical School, USA
²Department of Clinical and Experimental Medicine, University of Catania, Italy
³Faculty of Medicine of Tunis, University of Tunis El Manar, Tunisia

***Corresponding author:** Alfredo R Galassi, Via Antonello da Messina 75, Acicastello, 95021 Catania, Italy, Tel: +39-095-7263122; Fax: +39-095-7263124; E-mail: argalassi@gmail.com

Received: October 24, 2015 | **Published:** October 24, 2015

PCI techniques, such as dissection/re-entry and retrograde can enable bailout in case of a complication occurring during routine PCI, such as acute vessel closure [9]. Sixth, the operator learns to persist using a methodical approach until a successful outcome is achieved. Seventh, the CTO operator learns to be humble and eager to learn, as failure is always possible. Eight, the CTO PCI community is committed to continuous communication and rapid dissemination of novel techniques and technologies [10]. Figure 1 summarizes the different benefits of attempting CTO PCIs for the interventional cardiologist.

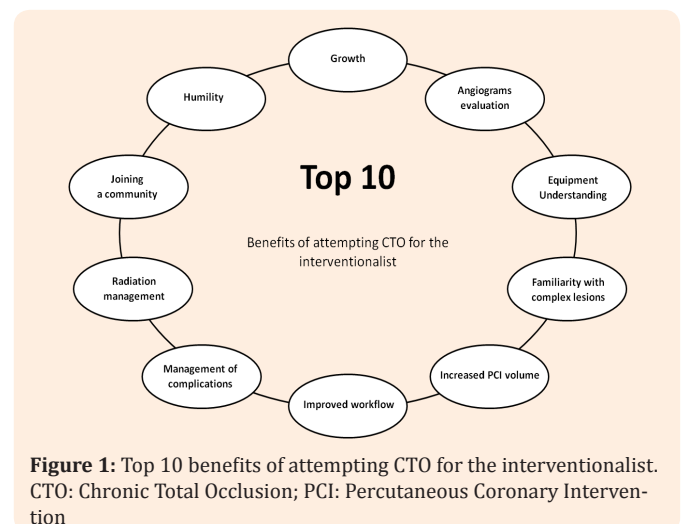


Figure 1: Top 10 benefits of attempting CTO for the interventionalist. CTO: Chronic Total Occlusion; PCI: Percutaneous Coronary Intervention

Conclusion

In conclusion, skills acquired performing CTO PCI are applicable to the entire spectrum of PCI and can significantly improve the operator's efficiency, safety, and success rates.

References

1. Carlino M, Magri CJ, Uretsky BF, Brilakis ES, Walsh S, et al. (2014) Treatment of the chronic total occlusion: A call to action for the interventional community. *Catheter Cardiovasc Interv* 85(5).
2. Tomasello SD, Boukhris M, Giubilato S, Marzà F, Garbo R, et al. (2015) Management strategies in patients affected by chronic total occlusions: results from the Italian Registry of Chronic Total Occlusions. *Eur Heart J pii: ehv450*.
3. Galassi AR, Boukhris M, Azzarelli S, Marzà F, Tomasello SD (201) Percutaneous Coronary Interventions for Chronic Total Occlusions: More Benefit for the Patient or for the Interventionist's Ego? *Can J Cardiol* 31(8): 974-979.
4. Tomasello SD, Giudice P, Attisano T, Boukhris M, Galassi AR (2014) The innovation of composite core dual coil coronary guide-wire technology: A didactic coronary chronic total occlusion revascularization case report. *J Saudi Heart Assoc* 26(4): 222-225.
5. Brilakis ES, Karpaliotis D, Patel V, Banerjee S (2012) Complications of chronic total occlusion angioplasty. *Interventional Cardiology Clinics* 1(3): 373-389.
6. Patel SM, Pokala NR, Menon RV, Kotsia AP, Raja V, et al. (2015) Prevalence and treatment of "balloon-uncrossable" coronary chronic total occlusions. *J Invasive Cardiol* 27(2): 78-84.
7. Boukhris M, Tomasello SD, Marzà F, Azzarelli S, Galassi AR (2015) Iatrogenic aortic dissection complicating percutaneous coronary intervention for chronic total occlusion. *Can J Cardiol* 31(3): 320-327.
8. Michael TT, Karpaliotis D, Brilakis ES, Alomar M, Abdullah SM, et al. (2015) Temporal trends of fluoroscopy time and contrast utilization in coronary chronic total occlusion revascularization: Insights from a multicenter united states registry. *Catheter Cardiovasc Interv* 85(3): 393-399.
9. Patel VG, Zankar A, Brilakis E (2013) Use of the retrograde approach for primary percutaneous coronary intervention of an inferior ST-segment elevation myocardial infarction. *J Invasive Cardiol* 25(9): 483-484.
10. Galassi AR, Sianos G, Werner GS, Escaned J, Tomasello SD, et al. (2015) Retrograde Recanalization of Chronic Total Occlusions in Europe: Procedural, In-Hospital, and Long-Term Outcomes From the Multicenter ERCTO Registry. *J Am Coll Cardiol* 65(22): 2388-2400.