

Orthostatic hypotension presenting as chest pain in a woman with parkinson's disease

Abstract

Parkinson's disease is associated with autonomic deregulation with cardiovascular autonomic dysfunction occurring in 40% of patients.¹ Postural hypotension symptoms, as a major reflection of this autonomic failure, has been reported to be present in one third of parkinson's disease patients. We describe an unusual case of an elderly woman with Parkinson's Disease, coronary artery disease and a dynamic left ventricular outflow tract gradient presenting with chest pain and dizziness resulting from the interaction between abnormal vascular and cardiac physiology.

Keywords: parkinson's disease, autonomic deregulation, orthostatic hypotension, chest pain, lv outflow obstruction

Volume 2 Issue 3 - 2015

Marwan Refaat,¹ Mostafa Hotait,¹ William D Anderson,² Steven E Reis³

¹Department of Internal Medicine, American University of Beirut, Lebanon

²Sisters of Charity of Leavenworth Health System (SCLHS), USA

³University of Pittsburgh Heart and Vascular Institute, USA

Correspondence: Marwan M Refaat, Assistant Professor of Medicine, Department of Internal Medicine, Cardiology/Cardiac Electrophysiology, American University Medical Center, Beirut, Lebanon, Tel 961-78-929290, Email mr48@aub.edu.lb

Received: March 11, 2015 | Published: March 31, 2015

Abbreviations: CAD, coronary artery disease; LVOT, left ventricular outflow tract

Case description

An 80-year-old woman with a history of revascularized coronary artery disease (CAD) and Parkinson's Disease presented with episodic dizziness and left sided chest pressure that occurs when climbing one flight of stairs. Her symptoms resolve only after lying supine at the top of the stairs. Changes in vital signs taken at the bottom of and after climbing one flight of stairs were: systolic blood pressure (SBP): 132 to 82mmHg; heart rate: 70 to 92 beats per minute (bpm). She did not develop symptoms when walking on a treadmill without an incline for 30 minutes. Her medications include metoprolol XL 50mg daily and Carbidopa/levodopa 25/100mg twice daily. On exam, moving from a supine to a standing position was associated with chest pain, orthostasis (a 36mmHg decrease in SBP) and development of a systolic ejection murmur heard loudest at the left sternal border. She was initially treated with midodrine, which was not associated with a significant change in her symptomatology. A treadmill sestamibi stress test was negative for ischemia. Echocardiography demonstrated a small left ventricular (LV) cavity with hypertrophy and hyperdynamic systolic function. Valsalva maneuver was associated with a 49mmHg gradient across the left ventricular outflow tract (LVOT). Diagnostic cardiac catheterization revealed widely patent stents and no obstructive CAD. No significant LVOT gradient was noted at rest. A single dose of intravenous hydralazine was administered to treat hypertension during the catheterization procedure. This resulted in systemic hypotension, which was associated with the development of chest pain and an LV-aortic gradient of 60mmHg with a Brockenbrough sign (Figure 1). As a result of these findings, her Carbidopa/levodopa dose was decreased to treat her orthostatic hypotension. On subsequent follow-up, her orthostatic hypotension improved and she reported significant improvement in lightheadedness, chest pain, and ability to walk stairs without symptoms.

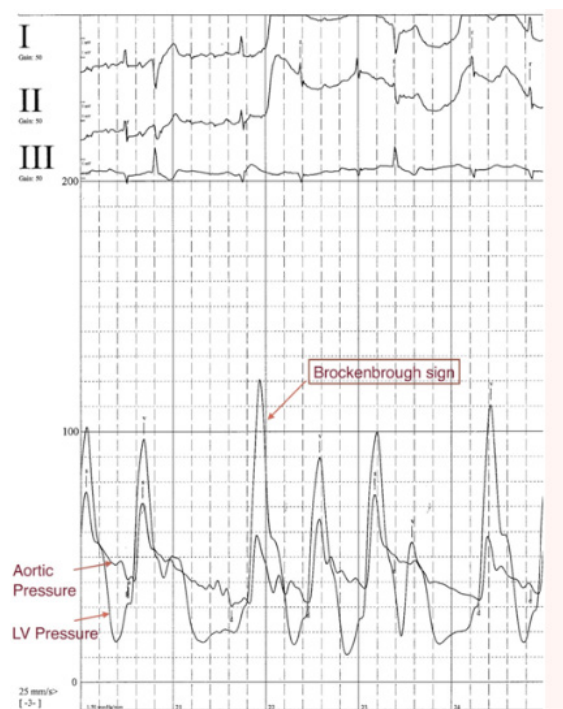


Figure 1 Diagnostic cardiac catheterization showing left ventricular gradient of 60mmHg with Brockenbrough sign exacerbated by systemic hypotension after hydralazine administration.

Comments

Parkinson's disease is associated with neurologic abnormalities including autonomic deregulation. Medications to treat this condition, such as carbidopa/levodopa, are also associated with orthostatic hypotension, which is a feature of sympathetic vasoconstrictor

failure.² In this case, the patient had chronic orthostatic hypotension as a result of Parkinson's disease and its treatment with carbidopa/levodopa. Previous reports indicate that autonomic failure can be associated with chest pain in the precordium,^{3,4} which may be related, in part, to orthostasis causing a form of subclavian steal syndrome due to reduction of blood supply to the internal mammary artery.⁴ However, this patient had another potential mechanism for her chest pain that occurs when she climbs stairs.

To the best of our knowledge, the present case is the first to describe the effect of acute preload reduction from orthostatic hypotension on the development of a dynamic left ventricular outflow obstruction in a patient with treated Parkinson's Disease. Patients with LVOT gradients in the setting of hypertrophic obstructive cardiomyopathy can develop chest pain as a result of impaired sub endocardial perfusion from phasic compression of intramural vessels and dynamic coronary bridges by the hypercontractile left ventricle.^{5,6} This chest pain typically occurs in response to activity or exercise but may occur at rest.⁵ The pain varies in quality from pressure to crushing pain and typically improves with rest.

Conclusion

In this case, Parkinson's Disease, and the medications used to treat it, caused severe orthostasis when the patient climbed stairs, which was associated with the development of a left ventricular outflow tract gradient, dizziness and chest pain from subendocardial ischemia. This case illustrates the importance of assessment of left ventricular physiology and management of orthostatic hypotension in patients with Parkinson's disease and a typical chest pain.

Acknowledgment

None.

Conflicts of interest

There is no conflict of interest.

Funding

None.

References

1. Low DA, Vichayanrat E, Iodice V, et al. Exercise hemodynamics in Parkinson's disease and autonomic Dysfunction. *Parkinsonism Relat Disord.* 2014;20(5):549–553.
2. Schatz IJ, Bannister R, Freeman RL. Consensus statement on the definition of orthostatic hypotension, pure autonomic failure and multiple system atrophy. *Clin Auton Res.* 1996;6(2):125–126.
3. Mathias CJ, Bannister RB, Cortelli P, et al. Clinical autonomic and therapeutic observations in two siblings with postural hypotension and sympathetic failure due to an inability to synthesize noradrenaline from dopamine because of a deficiency of dopamine beta hydroxylase. *Q J Med.* 1990;75(278):617–633.
4. Mathias CJ, Mallipeddi R, Bleasdale-Barr K. Symptoms associated with orthostatic hypotension in pure autonomic failure and multiple system atrophy. *J Neurol.* 1999;246(10):893–898.
5. Sherrid MV, Gunsbug D, Sharma A. Medical treatment of hypertrophic cardiomyopathy. *Curr Cardiol Rep.* 2000;2(2): 148–153.
6. Krams R, Kofflard MJ, Duncker DJ, et al. Decreased coronary flow reserve in hypertrophic cardiomyopathy is related to remodeling of the coronary microcirculation. *Circulation.* 1998;97(3):230–233.