

# Syndromes affecting ear nose & throat

Volume 5 Issue 4 - 2017

**Kalpajoti Bhattacharjee, Shyamala Karnam, Girish HC, Sanjay Murgod, Rajeshwari HS**

Department of oral pathology and microbiology, Rajiv Gandhi University of Health Sciences, India

**Keywords:** genetic disorders, oral manifestations, ear, nose, throat**Abbreviations:** TCS, treacher collins syndrome; RHS, ramsay hunt syndrome; FNP, facial nerve palsy; CHD, congenital heart diseases; AD, alzheimer's diseases; HD, hirsprung disease; DS, down syndrome; ES, eagle's syndrome; OAV, oculo-auriculovertebral; VZV, varicella zoster virus; MPS, myofacial pain syndrome; FMS, fibromyalgia syndrome; NF2, neurofibromatosis type I

## Introduction

The term syndrome denotes set of signs and symptoms that tend to occur together and reflect the presence of a particular disease or an increased chance of developing to a particular disease. There are more than 4,000 genetic disorders that constitute head and neck syndromes of which more than 300 entities involve craniofacial structures.<sup>1</sup>

The heritage of the term syndrome is ancient and derived from the Greek word sundrome: sun, syn – together + dromos, a running i.e., “run together”, as the features do. There are numerous syndromes which involve Ear, Nose, Throat areas with oral manifestations. The aim of this review is to discuss ear, nose and throat related syndromes with oral manifestations.

## Etiopathogenesis

The genetic factors either in isolation or in conjunction with various environmental factors play a role in causation of these craniofacial anomalies. Many syndromes are due to a genetic anomaly, including chromosomal anomalies, monogenic diseases and metabolic disease. The intercommunication between genetics and environment is essential especially during early developmental stages. Any disturbance or alteration in these genetic and environmental factors may lead to various morphological and functional errors and hence to syndromes. Changes in DNA due to alteration can cause errors in protein sequence, creating partially or completely non-functional proteins, resulting into a inherited disorder. Many syndromes are due to a genetic anomaly, including chromosomal anomalies, monogenic diseases and metabolic diseases. Environmental factors are not transmitted hereditarily and establish the progress of disease in those hereditarily predisposed to a particular condition. In terms of syndromes, commonest ecological source is teratogenic exposure. A teratogen is any chemical, substance, or exposure that may cause birth defects to the developing fetus.<sup>1</sup>

If mutations occurs in undifferentiated stem cells during early embryonic life, osteoblasts, melanocytes and endocrine cells that represent the progeny of the mutated cell all will carry that mutation and express the gene. Hence result in multiple bone lesions, cutaneous pigmentation and endocrine disturbances. If mutations occurs during later period, then progeny of mutated cell will disperse and participate in formation of polyostotic fibrous dysplasia. If mutation occurs during postnatal life, progeny of mutated cell are confined to one site and leads to formation of monostotic fibrous dysplasia.<sup>2</sup>

## List of syndromes affecting ear nose & throat

- Goldenhar syndrome,
- Frey syndrome,
- Eagle's syndrome,
- Ramsay Hunt syndrome,
- Down's syndrome,
- Treacher Collins syndrome (TCS).

## Goldenhar syndrome

Goldenhar syndrome is a diverse and poorly understood continuum of disorders of unknown etiology. It is a complex of developmental disorders (face, ears, eyes, spine, etc.), varying in severity in each patient (Berker et al.). The estimated incidence of the syndrome ranges from 1 in 3500 to 5600 live births. The male-to-female ratio is approximately 3:2.<sup>3</sup> Some teratogenic agents associated with this syndrome are thalidomide, malnutrition, tobacco and herbicides which are able to produce free radicals which break the DNA resulting in congenital malformation.<sup>4</sup> The etiology of GS remains unknown. Hartsfield (2007) reviewed the literature and suggested that GS is the outcome some type of vascular perturbation and/or neural crestopathy during a critical time of embryogenesis. In the literature autosomal dominant, autosomal recessive and multifactorial inheritance patterns have been reported, but most of GS cases are sporadic.<sup>5</sup>

## Varied clinical features of syndrome:

- Ear:** Preauricular skin tags, dysmorphic ear, conductive hearing loss.
- Neck:** Branchial cartilage, branchial fistula, webbing, short neck, abnormalities of sternocleidomastoid muscle.
- Abdominal wall:** Divarication of recti, Umbilical hernia, inguinal hernia.

- d. **Eye:** Epicanthal folds, upper/lower lid coloboma, Optic Nerve coloboma, ocular drainage abnormalities, exotropia, epiphora, microphthalmia, epibulbar dermoids, lipodermoids.
- e. **Back:** Pilonidal dimple, kyphoscoliosis, Sprengel's deformity.
- f. **Hands/Fingers:** clubbing, polydactyly, clinodactyly, single palmar crease.
- g. **Skeletal:** Cervical fusion, Hemivertebrae.
- h. **Cardio vascular:** Cardiomegaly, ventricular hypertrophy, ASD, VSD, TOF.
- i. **Gastrointestinal:** TEF and anal anomalies.
- j. **Genitourinary:** Chordee, undescended testes, abnormalities of size of testes.
- k. **Skin and Adnexa:** Low posterior hair line.

Oral manifestations include maxillary hypoplasia, zygomatic hypoplasia, macrostomia, mandibular ramus asymmetry, malocclusion, cleft lip and cleft palate.

Treatment depends on the patient's age and systemic manifestations, but generally requires a multidisciplinary approach. Treatment varies according to age of the patient: Between 2 and 4 years, no treatment is necessary for patients who are mildly affected. Reconstruction by rib bone graft and lengthening of underdeveloped mandible by a bone distraction device is recommended in severe underdeveloped mandible, modifications in the growth of teeth are done with the assistance from orthodontics. Amongst, 6-8 years reconstruction of the external ear is done in several stages over the period of 6-12 months. In 8-10 years, asymmetry of cheek is to be reconstructed. This may be the most important stage in entire treatment program, in terms of physical appearance. In mild involvement no surgery is required while jaw surgery may be done in teenagers.<sup>6</sup>

### Frey syndrome

Frey syndrome most commonly occurs after parotid surgery and refers to a combination of hyperhidrosis, warmth, flushing, and erythema that occurs with gustatory stimulation due to damage of auriculotemporal nerve. The patient who develops this condition may experience only one or a combination of the symptoms that comprise the syndrome. The key component is that gustatory stimulation elicits the symptoms. Oral manifestations include salivation reflex from mastication. They can appear when the affected person eats, sees, dreams, thinks about or talks about certain kinds of food which produce strong salivation.<sup>7</sup>

**Pathophysiology:** The syndrome arises from an alteration of the complex network of nerves found in the preauricular area. The currently accepted pathogenesis of Frey syndrome is that trauma in the area of the parotid gland results in sectioning of both sympathetic and parasympathetic fibers. During their regeneration, parasympathetic fibers originally meant for the parotid or smaller salivary glands begin to aberrantly innervate sweat glands and cutaneous vasculature. This not only results in gustatory sweating, but also the flushing, warmth, and erythema associated with gustatory stimulation characteristic of the syndrome.<sup>7</sup>

A variety of medical and surgical modalities have been used to manage the symptoms of Frey syndrome. Topical therapies target either the cholinergic synapse via acetylcholine receptor antagonism (scopolamine, atropine, and glycopyrrolate) or the eccrine gland via direct inhibition of eccrine gland secretion (aluminum chloride solutions and other antiperspirants).<sup>7</sup>

### Eagle's syndrome

ES which was defined by Eagle, is a condition related to the elongation and ossification of the styloid process that results in orofacial pain. There are two clinical presentations including classic stylohyoid and stylocarotid syndromes. The classic stylohyoid syndrome, due to affection of lower cranial nerves, presents in the form of cervicofacial pain accompanied by dysphagia and foreign body sensation. The stylocarotid syndrome, due to carotid artery compression, may be associated with a neurological focus and even syncope. ES may present unilaterally or bilaterally. The most frequent symptoms are dysphagia, headache, pain on extension of the tongue, change in voice or sensation of hypersalivation and particularly pain during the neck rotation.<sup>8</sup> Following data in literature, it is a rare disease. 0.04-0.08% of population is suffering from it. Radiological analysis is the basic method for the localization of the stylohyoid complex disturbance and the diagnostics of its nature.<sup>9</sup> Oral manifestations include painful trismus, tongue pain in general, sensation of increased salivation, pain triggered by movement of mandible, pain in the molar region of the mandible.

Both surgical and conservative treatment methods exist. Surgical methods involve amputating or removing the elongated styloid process through an intraoral or extraoral approach. In conservative treatment, oral medication with antidepressants and anticonvulsants can be used, and steroid or local anesthesia with long-term effects can be used on the tonsil or tender areas. Other methods include reducing pain through physical therapy, relaxing the muscles that had been constricted due to styloid process stimulation.<sup>10</sup>

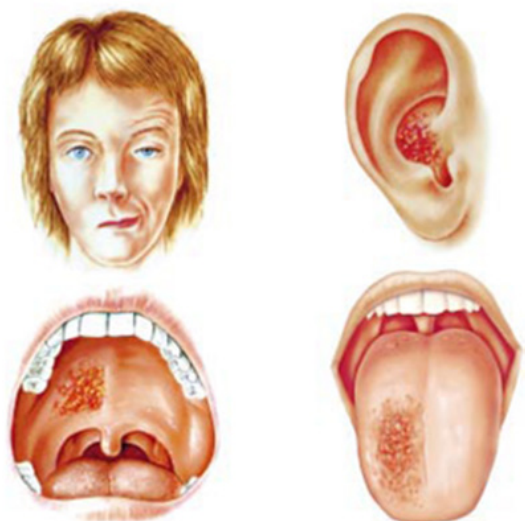
### Ramsay hunt syndrome

Ramsay Hunt syndrome (RHS), first described by J. Ramsay Hunt in 1907, refers to the association of unilateral peripheral facial nerve palsy (FNP) and reactivation of VZV along the sensory nerves innervating the ear (herpes zoster oticus). RHS has been reported to have the incidence of 5 per 100,000, and known to be approximately 12% of all facial nerve paralysis cases.<sup>11</sup> Although Ramsay Hunt syndrome is traditionally defined as zoster oticus and lower motor neuron facial palsy, Hunt noted other regular symptoms and signs such as tinnitus, hearing loss, nausea, vomiting, vertigo, and nystagmus. He explained these eighth nerve features by the close proximity of the geniculate ganglion to the vestibulocochlear nerve within the bony facial canal. Hunt surmised that the gasserian, geniculate, petrous, accessory, jugular, plexiform, and second and third cervical dorsal root ganglia comprised a chain in which inflammation of a single ganglion could extend to nearby ganglia. This hypothesis explained cases of unilateral facial palsy accompanied by contiguous cranial neuropathies associated with vesicles in the mouth—usually on the tongue or hard palate—or ear.<sup>12</sup> Oral manifestation include pain deep in the face, salivation, unilateral facial paralysis, vesicles in the mouth—usually on the tongue or hard palate—or ear. Acyclovir in combination with corticosteroids are considered the correct treatment of RHS<sup>13</sup>(Figure 1).

### Down's syndrome

Down syndrome is one of the most leading causes of intellectual disability and millions of these patients face various health issues including learning and memory, congenital heart diseases (CHD), Alzheimer's diseases (AD), leukemia, cancers and Hirschprung disease (HD). The incidence of trisomy is influenced by maternal age and differs in population (between 1 in 319 and 1 in 1000 live births). DS complex phenotype results from dosage imbalance of genes located on human chromosome 21 (Hsa 21). DS individual have

variety of physical characteristics like a small chin, slanted eye, poor muscle tone, small nose with flat nasal bridge, a single crease of the palm, small mouth and large tongue. Other features includes big toe, abnormal pattern of fingerprint and short fingers.<sup>14</sup> Management of the syndrome require a planned approach of evaluation, monitoring, prevention, and vigilance. Enhancement in the quality of life of individuals with Down's syndrome has resulted from improvements in medical care. Recognition and treatment of psychiatric disorders, and early educational interventions with support in typical educational settings.<sup>15</sup>



**Figure 1** Clinical features of Ramsay Hunt syndrome. Note peripheral facial weakness characterised by a widened palpebral fissure and decreased forehead wrinkling and smile on the right, often associated with vesicles in the ipsilateral ear, on the hard palate, or on the anterior two thirds of the tongue.

### Treacher collins syndrome (TCS)

Treacher Collins syndrome is an autosomal dominant disorder of craniofacial morphogenesis with high penetrance and variable expressivity. It is estimated that the frequency of TCS is 1 in 50,000 live births. Approximately 60% of the autosomal dominant occurrences arise as de novo mutation. Genetically, the treacle gene (TCOF1) is mutated. It is found on chromosome 5q31.3-32 and encodes a serine/alanine rich nucleolar phosphoprotein responsible for the craniofacial development. Symptoms include down slanting eyes with notched lower lids, sunken cheekbones and jawbones, pointed nasal prominence, broad mouth and high arched palate, malformation of the auricular pinnae and conducting hearing loss and preauricular hair extension. A minority of those affected with TCS may have cleft lip and/or palate.<sup>16</sup> Surgical treatments are not fully corrective. Administration of folic acid before and after pregnancy provides measurable protection for the embryo from apoptosis without detrimental side effects during the 3 to 12-week period when the embryo is most susceptible to the development of craniofacial and other anomalies.<sup>17</sup>

### Discussion

A syndrome is a set of sign and symptoms that are related to each other and reveal the presence of a particular disease and an amplified chance of emerging to a particular disease. There are abundant orofacial syndromes and many of them affecting the ear, nose and throat areas and meticulous knowledge of their manifestations and implications is relevant in good oral health care delivery.

The most common syndromes occurring in the Ear, Nose & Throat areas are Goldenhar's syndrome, Treacher-Collins syndrome (TCS), Ramsay Hunt Syndrome (RHS), Down syndrome (DS), Eagle's syndrome (ES), Crouzon syndrome, Stickler syndrome, Frey syndrome.

Goldenhar's syndrome is an inherited condition and several terms are used to describe this rare condition known as oculo-auriculovertebral (OAV) dysplasia, including Goldenhar's syndrome and hemifacial microsomia.<sup>18</sup> The term oculoauriculovertebral dysplasia is used to illustrate the syndrome characterized by epibulbar dermoids and/or lipodermoids, auricular appendages, auricular fistulas, and vertebral anomalies. Syndromes derived from aberrations in the development of the first and second branchial arches are in the spectrum of GS, including Treacher-Collins syndrome (TCS). The presence of facial asymmetry and far less hypoplasia of the malar bones in GS are important features to differentiate it from TCS. The TCS affected patients presented downward slating palpebral fissures, colobomas, zygomatic and mandibular hypoplasia, partial absence of the lower eyelid cilia, and abnormalities of the ears.<sup>5</sup> TCS patients are characterized by absent, small, or unusually formed ears. Hearing loss occurs in about half of all affected individuals; hearing loss is caused by defects of the three small bones in the middle ear, which transmit sound, or by underdevelopment of the ear canal.<sup>19</sup>

Ramsay Hunt Syndrome (RHS) is a viral polineuropathy, occurs after reactivation of Varicella Zoster virus (VZV) hiding inside dorsal roots and cranial nerve ganglions. Aging, malignancy, chemoradiotherapy exposure, immune deficiency may trigger reactivation of this virus. Characteristic features of RHS are painful herpetic vesicles on tympanic membrane and/or external auditory meatus with facial paralysis on the same side and presence of these vesicles fascilitate differential diagnosis from Bell's Palsy.<sup>20</sup> The etiology of Bell's palsy is unknown but viral infection, vascular ischemia, and autoimmune disease have been postulated as the possible pathomechanisms. Severe pain suggests herpes simplex or zoster infection and may precede vesicular eruption and progression to Ramsay Hunt syndrome.<sup>21</sup>

Down syndrome (DS) is caused by trisomy of chromosome 21 (Hsa21) and is related with a number of deleterious phenotypes, including learning disability, heart defects, early-onset Alzheimer's disease and childhood leukaemia.<sup>22</sup> Soon after birth, all children with Down's syndrome should be assessed for congenital heart disease, hearing loss, and ophthalmological problems. The most frequent lesions are atrioventricular septal defect (45% of newborns with Down's syndrome) and ventricular septal defect (35%); isolated secundum atrial septal defects (8%), isolated persistent patent ductus arteriosus (7%), isolated tetralogy of Fallot (4%), and other lesions (1%) can also arise.<sup>15</sup>

Eagle's syndrome represents symptoms brought on by compression of regional structures by elongation of the styloid process or ossification of the stylohyoid or stylomandibular ligaments. symptoms include the throat pain radiating to ipsilateral ear or foreign body sensation in the pharynx causing odynophagia and dysphagia. There are three syndromes closely connected with the styloid process syndrome: Costen's, Trotter's, and Myofacial painful syndromes (Sandev et al.). Clinicians should consider coexisting locomotor system disorders such as Myofacial pain syndrome (MPS), Fibromyalgia syndrome (FMS), and Temporomandibular dysfunction in patients with Eagle's Syndrome.<sup>23</sup> Diagnosis is done through radiography.

Frey syndrome is a sequela observed after parotidectomy and the reported incidence varies enormously in the literature. The classic



syndrome triad is hyperemia, heat and sweating in the pre-mandibular region and the mandible angle area.<sup>24</sup> The most widely accepted explanation for Frey's syndrome is the transection of postganglionic parasympathetic secretomotor fibres from the otic ganglion originally directed to the parotid gland, followed by aberrant re-innervation of the denervated facial cholinergic sweat glands and blood vessels. Mechanisms for flushing include misdirected regeneration or collateral sprouting of parasympathetic fibres into sympathetic pathways in the auriculotemporal and nearby nerves and/or release of bradykinin-producing enzymes by activated sweat glands resulting in vasodilatation.<sup>25</sup> Neurofibromatosis type II (NF2) is not a disorder of the inner ear may present with hearing loss (which can be of sudden onset), tinnitus and recurrent episodes of vertigo.

## Conclusion

Eyes can only see what the brain knows. Importance of this proverb is realized in our lives time and time again. Many lethal diseases leave their footmarks in oral cavity as an early sign. The majority of the craniofacial anomalies have oral manifestations, and many a times they are the only symptoms to present at the particular stage. The role of dentist plays a major role in the identifying and recognizing these oral signs so that measures can be taken at an early stage to prevent the morbidity and mortality associated with these conditions. Till now there is no complete treatment for genetic syndromes, rendering only symptomatic treatment by means of multidisciplinary approach. If the disorder is heritable, there is an added dimension the need to know the genetic risk and the means available to prevent its transmission. Proper genetic counseling, genetic screening should be done along with various antenatal diagnostic methods are there to know about the disorders, so that these devastating conditions can be prevented.

## Acknowledgements

None.

## Conflicts of interest

Author declares there are no conflicts of interest.

## Funding

None.

## References

1. Khanna S, Narendra Singh NN, Brave VR, et al. Oro-Facial Syndromes: An Approach towards Etiopathogenesis, Diagnosis and Management – A Systematic Review. *International Journal of Oral & Maxillofacial Pathology*. 2013;4(1):15–25.
2. Neville BW, Damm DD, Allen CM, et al. *Oral and Maxillofacial Pathology*. (3<sup>rd</sup> edn), New Delhi, India. 2002.
3. Kokavec R. Goldenhar syndrome with various clinical manifestations. *Cleft Palate Craniofac J*. 2006;43:628–634.
4. Sharma JK, Pippal SK, Raghuvanshi SK, et al. Goldenhar-Gorlin's syndrome: A case report. *Indian J Otolaryngol Head Neck Surg*. 2006;58(1):97–101.
5. Martelli H, Miranda RT, Fernandes CM. Goldenhar syndrome: clinical features with orofacial emphasis. *J Appl Oral Sci*. 2010;18(6):646–649.
6. Patil NA, Patil AB. Goldenhar syndrome: Case report. *IJSS Journal of Surgery*. 2015;1(1):18–20.
7. Jahan-Tigh RR, Cohen PR. Frey Syndrome in a Patient with Facial Melanoma: Auriculotemporal Syndrome Presenting with Gustatory Sweating Following Wide Local Excision, Sentinel Node Biopsy, and Superficial Parotidectomy. *J Clin Aesthet Dermatol*. 2012;5(7):48–52.
8. Hadi S, Ozgur C, Serra S, et al. 3D reconstruction computerized tomography findings of an asymptomatic Eagle's Syndrome patient: a case report. *Int J Anat Var*. 2013;6:176–178.
9. Gervickas A, Kubilius R, Sabalyus G. Clinic, diagnostics and treatment peculiarities of Eagle's syndrome. *Stomatologija, Baltic Dental and Maxillofacial Journal*. 2004;6(1):11–13.
10. Han MK, Kim DW, Yang JY. Non Surgical Treatment of Eagle's Syndrome-A Case Report. *J Korean Assoc Oral Maxillofac Surg*. 2013;26(2):169–172.
11. Kim CH, Kang SI, Kim YH. A Case of Ramsay Hunt Syndrome with Cranial Polyneuropathy. *Korean J Audiol*. 2012;16(2):80–82.
12. Sweeney CJ, Gilden DH. Ramsay Hunt syndrome. *J Neurol Neurosurg Psychiatry*. 2001;71(2):149–154.
13. Rasmussen ER, Lykke E, Toft JG, et al. Ramsay Hunt syndrome revisited—emphasis on Ramsay Hunt syndrome with multiple cranial nerve involvement. *Virology Discovery*. 2014;2:1.
14. Asim A, Kumar A, Muthuswamy S, et al. Down syndrome: an insight of the disease. *J Biomed Sci*. 2015;22(1):41.
15. Roizen NJ, Patterson D. Down's syndrome. *Lancet*. 2003;361(9365):1281–1289.
16. Shete P, Tupkari JV, Benjamin T, et al. Treacher Collins syndrome. *J Oral Maxillofac Pathol*. 2011;15(3):348–351.
17. Trainor PA, Dixon J, Dixon MJ. Treacher Collins syndrome: etiology, pathogenesis and prevention. *Eur J Hum Genet*. 2009;17(3):275–283.
18. Pinheiro ALB, Araújo LC, Oliveira SB, et al. Goldenhar's syndrome: Case report. *Braz Dent J*. 2003;14(1):67–70.
19. Desai V, Pratik P. Mandibulofacial dysostosis. a case report. *International Journal of Pharmaceutical and Chemical Sciences*. 2014;3:431–432.
20. Gurbuz M, Birdane L, Incesulu A, et al. A Case of Ramsay Hunt Syndrome after inactive influenza vaccine. *Int Adv Otol*. 2010;6(3):419–422.
21. Basić-Kes V, Dobrota VD, Cesarik M, et al. Peripheral facial weakness (Bell's palsy). *Acta Clin Croat*. 2013;52(2):195–202.
22. Wiseman FK, Alford KA, Tybulewicz VLJ, et al. Down syndrome-recent progress and future prospects. *Hum Mol Genet*. 2009;18(R1):R75–R83.
23. Piagkou M, Anagnostopoulou S, Kouladouros K, et al. Eagle's syndrome: A review of the literature. *Clin Anat*. 2009;22(5):545–558.
24. Santos RC, Chagas JF, Bezerra TF, et al. Frey's Syndrome prevalence after partial parotidectomy. *Braz J Otorhinolaryngol*. 2006;72(1):112–115.
25. Matin RN, Esdaile B, de Sica Chapman A, et al. Unilateral Gustatory Flushing: A Variant of Frey's Syndrome? *J Clin Exp Dermatol Res*. 2013;S6:007.