MedCrave
Step into the World of Research

Journal of Analytical & Pharmaceutical Research

Case Report

Open Access

CrossMark

A rare congenital silver russell syndrome-case report

Abstract

Silver-Russell Syndrome (SRS) is a very rare genetic disorder present at birth that involves poor growth, low birth weight, short stature and differences in the size of the two sides of the body. We present 8years male boy came to Mahatma Gandhi Memorial Hospital, Warangal, Telangana, with complaints of cryptorchidism, triangular face, maxillary hypoplasia, and is height and weight are less than 3rd percentiles. No history of consanguineous marriage of their parents. Growth hormone therapy is often considered for the child with SRS.

Keywords: silver-russell syndrome, short stature,cryptorchidism, maxillary hypoplasia

Volume 5 Issue 2 - 2017

Rakesh Kumar Chakinala,[1] Dileep Reddy Gottimukkula,[1] Nagesh Adla,[1] Surender Kagithapu,[2] Yogi Morishetty,[2] Goverdhan Puchchakayala[1]

[1]Department of Pharmacy Practice,Vaagdevi College of Pharmacy, India

[2]Kakathiya Medical College, Mahatma Gandhi Memorial Hospital, India

Correspondence: Goverdhan Puchchakayala, Department of Clinical Pharmacy,Vaagdevi College of Pharmacy,Warangal, Telangana, India, Email gov_ku@yahoo.com

Received: October 25, 2016 | **Published:** June 22, 2017

Introduction

Silver-Russell Syndrome (SRS) is a clinically and genitically a heterogeneous disorder of growth with a wide range of additional dysmorphic features. SRS may compromise different disorders with clinically related to phenotypes or may result from disturbance ofdifferent components of a single biochemical or endocrinological pathways are involved.[1,2] SRS is also called as asymmetry dwarf-dysgenesis syndrome.[3] The estimated incidence of SRS is approximately 1/50,000 to 1/100,000 births.[4] Male and female children are equally affected.The disease in children was characterized by congenital hemi hypertrophy, low birth weight, short stature, facial abnormalities, growth retardation.[5,6]

Case report

We report a case of an 8-years-old boy came to Mahatma Gandhi Memorial Hospital, Warangal, Telangana on physical examination the boy was appeared to be cryptorchidism, triangular facies, maxillary hypoplasia, and his height and weight are less than 3rd percentiles. His parents did not have a consanguineous marriage. Electroencephalography and head Magnetic resonance Imaging showed normal results. Kidney, liver and thyroid lab reports were normal. Growth hormone stimulation test shows low levels of growth hormone. Based on these symptoms and lab reports it was diagnosed as SRS. Treatment includes Recombinant human growth hormone is given subcutaneous injection at a dose of 0.48mg/kg per week, physiotherapy and nutritional support was advised and counseled for regular follow up and discharged (Figure 1).

Discussion

SRS was first described Silver and his colleagues in 1953 and later by Russell in 1954. In 1953, Silver et al reported two unrelated children with congenital hemihypertrophy, low birth weight, and short stature[7] and in 1954 Russell described five unrelated children with extreme intrauterine growth retardation and characteristic facial features.[4] Clinically and genetically SRS is a heterogeneous disorder, and the reason is unknown.

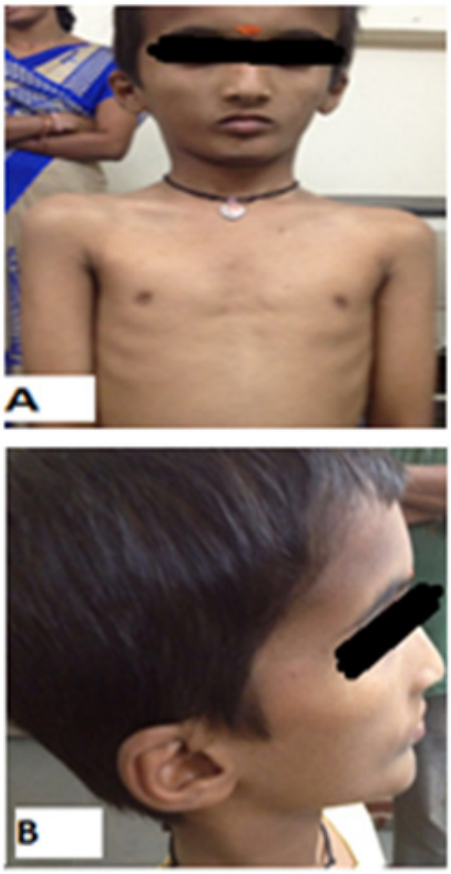

Figure 1 The boy was appeared to be cryptorchidism, triangular facies, maxillary hypoplasia, and his height and weight are less than 3rd percentiles.

Chromosome abnormalities are involved in these disease among them chromosomes 7 and 17 are frequently involved. In 7% of sporadic cases, maternal uniparentaldisomy of chromosome 7 has been identified. Recent findings suggested that imprinting

©2017 Chakinala et al. This is an open access article distributed under the terms of the Creative Commons Attribution License, which permits unrestricted use, distribution, and build upon your work non-commercially.

defects in the region of 11p15 is also pays in SRS.[8–11] According to pathophysiologically, growth failure is a primary abnormality. Patients typically present with intrauterine growth retardation, difficulty in feeding, failure to thrive, or postnatal growth retardation and also growth hormone insufficiency may be present. Abnormalities of natural growth hormone secretion and subnormal responses to stimulating growth hormone stimulation have been reported in a significant number of children with SRS.[12,13] Diagnostic criteria recently proposed that SRS should have at least 4 criteria they are dysmorphic facies characterized by small triangular facies, a high forehead with small jaws, prominent nasal bridge, small chin,together with a wide, thin, "shark like mouth". Growth and skeletal asymmetry of the limbs manifested as hemihypertophy, clinodactyly of the fifth finger, syndactyly of second and third toes were also impartant criteria of SRS.[7,14]

Conclusion

SRS is a growth and skeletal disorder associated with a lot of morbidity. Early diagnosis and treatment is important to avoid joint deformities. Identification of the underlying molecular subtype can guide treatment with regard to specific risk factors. Management should involve a multi-disciplinary approach and close parental guidance. Growth hormone, and in more severe cases surgery is needed to lengthen limbs. Nutritional support and physiotherapy are also advised in SRS.

Acknowledgments

None.

Conflicts of interest

The authors declare no conflicts of interest related to this article.

Funding

None.

References

1. http://www.accessmylibrary.com/article–IGI–81762589/silver–russell–syndrome–dissection.html
2. Sunil K, AP Jain, SachinA, et al. Silver–Russell Syndrome:A case report. *Cases J*. 2008;1(1):304.
3. Li YX, Yan C. Endocrinology of pediatrics. Beijing, China:People's Health Publishing House; 1991. p. 49–50.
4. http://en.wikipedia.org/wiki/Silver%E2%80%93Russell_syndrome.
5. Silver HK, Kiyasu W, George J, et al. Syndrome of congenitalhemihypertrophy, shortness of stature, and elevated urinary gonodotropins. *Pediatrics*. 1953;12(4):368–375.
6. Russell A. A syndrome of "intra–uterine" dwarfism recognizable at birth with cranio–facial dysostosis, disproportionately short arms, and other anomalies (5examples). *Proc R Soc Med*. 1954;47(12):1040–1044.
7. Patton M. Russell–Silver Syndrome. *Journal of Medical Genetics*. 1988;25:557–560.
8. Rossignol S. Silver– Russell syndrome and its genetic origins. *J Endocrinol Invest*. 2006;29(1suppl):9–10.
9. van Haelst MM, Eussen HJ, Visscher F, et al. Silver– Russell phenotype in a patient with pure trisomy 1q32.1–q42.1:further delineation of the pure 1q trisomy syndrome. *J Med Genet*. 2002;39(8):582–585.
10. Monk D, Bentley L, Hitchins M, et al. Chromosome 7p disruptions in Silver– Russell syndrome: delineatimg an imprinted candidate gene region. *Hum Genet*. 2012;111(4–5):376–387.
11. Langlois S, Yong SL, Wilson RD, et al. Prenatal and postnatal growth failure associated with maternal heterodisomy for chromosome 7. *J Med Genet*. 1995;32(11):871–875.
12. Eggermann T, Wollmann HA, Kuner R, et al. Molecular studies in 37 Russell syndrome patients: frequency andetiology of uniparentaldisomy. *Hum Genet*. 1997;100(3–4):415–419.
13. Moore GE, Abu–Amero S, Wakeling E, et al. The search for the gene for Silver–Russell syndrome. *Acta Paediatr Suppl*. 1998;88(433):42–48.
14. http://emedicine.medscape.com/article/948786–overview