

# Surgical decannulation of veno-arterial extracorporeal cardiopulmonary resuscitation (VA-ECPR): a technical note

**Keywords:** post-procedure, interventionist, VA-ECPR, ECPR, ECMO, SFA

**Abbreviations:** VA-ECPR, veno-arterial extracorporeal cardiopulmonary resuscitation; ECMO, extracorporeal membrane oxygenation; CFA, common femoral artery; PFA, profunda femoral artery; SFA, superficial femoral artery

## Introduction

In this endovascular era, the popularity of seldinger technique or percutaneous approach coupled with advancing device technology has not only led to increase used of femoral vessels as access site but also insertion of larger bore vessel sheath (18Fr-24Fr).<sup>1</sup> This concept is no longer confined to the use of surgeons or interventionist. Rather, it is now increasingly commonplace for critical care physicians to be performing procedures such as an emergent veno-arterial Extracorporeal Cardiopulmonary Resuscitation (VA-ECPR) or Extracorporeal Membrane Oxygenation (ECMO) by the bedside.<sup>2,3</sup> This result in a unique surgical conundrum as the femoral vessels are cannulated under time pressure, in suboptimal environment with no immediate fluoroscopic facilities and physicians who may not have skills to deal with access site complications.<sup>1</sup>

Therefore, one of the challenges faced by vascular surgeon today in addition to dealing with access site complication is in providing expertise in decannulation of these large bore access sheath in ECPR or ECMO on successful weaning. Although multiple studies exist regarding the different cannulation techniques for ECPR or ECMO.<sup>4-8</sup> Little is available in a way of decannulation techniques.<sup>9</sup> We describe a technical note on surgical decannulation of a percutaneously inserted ECPR in a patient with congenital variation of femoral artery and share tips for consideration in future practice.

## Surgical technique

Percutaneous cannulation of 17Fr venous sheath and 24Fr arterial sheath performed by critical care physicians (Figure 1). First, bilateral groin incision is made. The venous sheath was exposed in the common femoral vein (CFV) with sloops for proximal and distal control (Figure 2). Next, the arterial sheath was exposed in the superficial femoral artery (SFA). Congenital variation of retroinguinal common femoral artery (CFA) bifurcation was subsequently confirmed with profunda femoral artery (PFA) noted alongside SFA (Figure 3). The venous sheath was removed, CFV clamped and venotomy oversewn with 5/0 prolene double breasted (Figure 4). After clamping SFA, the arterial sheath was removed and decision made to use ipsilateral long saphenous vein as patch repair. Embolectomy performed prior to patch angioplasty with 5/0 prolene (Figure 5). The distal reperfusion cannula is then retrieved from distal SFA and primarily repaired. Bilateral lower limb perfusion was acceptable post-procedure.

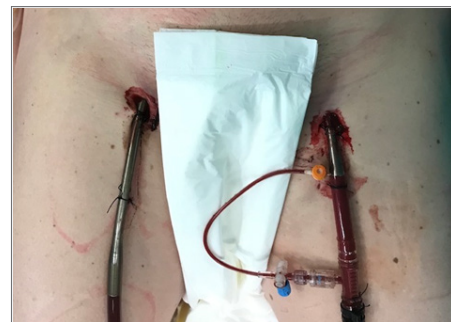Volume 10 Issue 3 - 2018

Yen Ming Chan, Gabija Lazaraviciute, Bryce Renwick

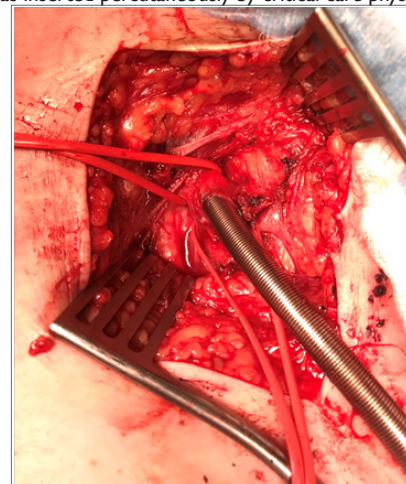Vascular Surgery, Aberdeen Royal Infirmary, United Kingdom

**Correspondence:** Yen Ming Chan, Aberdeen Royal Infirmary, Scotland, United Kingdom, Tel +44 345 456 6000, Fax +44 122 455 2553, Email sharonyenming.chan@nhs.net

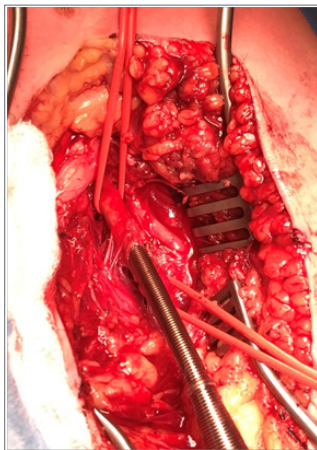
Received: January 22, 2018 | Published: June 6, 2018



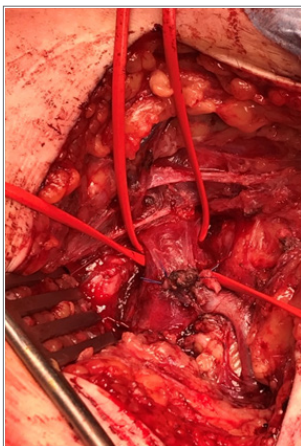
**Figure 1** 17Fr venous sheath (black arrow) and 24Fr arterial sheath (black pointer) with distal perfusion cannula in patient's right and left groin respectively. This was inserted percutaneously by critical care physicians.



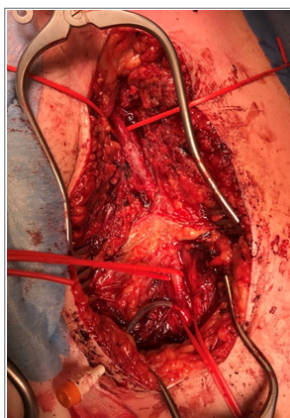**Figure 2** Venous sheath in-situ common femoral vein (black arrow) with sloops for proximal and distal control.



**Figure 3** Congenital variation of retroinguinal common femoral artery with arterial sheath in superficial femoral artery (black arrow) with sloops proximal and distal for control. Profunda femoral artery (black pointer) noted alongside.



**Figure 4** Venous sheath removed. Venotomy oversewn with 5/0 prolene double breasted.



**Figure 5** Arterial sheath removed. Long saphenous vein path angioplasty to superficial femoral artery (black arrow). Distal reperfusion cannula in-situ distal superficial femoral artery (black pointer).

## Discussion

Since it was first discovered in 1950s, the indication and technology of ECMO has revolutionised from used only in cardiac surgery to the

bedside as in the case of ECPR.<sup>10</sup> Although more refined guidance is required and ethical issues such as public's acceptability of ECPR has yet to be established, the use of ECPR is currently viewed as appropriate and is increasing.<sup>11</sup> This is reflected upon the ten-fold rise in ECPR in all adult ECMO used according to the Extracorporeal Life Support Organisation (ELSO) registry.<sup>12</sup> Richardson et al reported that survival to discharge for ECPR is 29% compared to conventional CPR (CCPR) with rates varying from 15–17%.<sup>13</sup> ECPR is also associated with improve neurological outcome particularly during the first 3-6 months when compared to CCPR.<sup>14</sup> Meanwhile, improvement in the design of cannulae and sheath has led to an increase used of percutaneous peripheral cannulation in ECMO in place of open approach.<sup>15</sup> The benefit of this is faster cannulation with less bleeding on insertion but it does not come without risk.<sup>4</sup> Vessel complications from percutaneous cannulae placement ranges from 5–10%.<sup>9</sup> These include limb ischemia, vessel perforation and significant bleeding after cannulae removal, all of which require surgical revision that has significant morbidity.

Methods of decannulation described are manual compression, open approach and more recently percutaneously.<sup>8</sup> Manual compression can only be safely performed if the sheath is less than 16Fr. Percutaneous approach is a new and promising technique but lacks robust randomised controlled studies at present.<sup>16,17</sup> In addition, these studies show that the success of percutaneous approach to decannulation relies heavily on skilled personnel in the usage of suture-mediated closure device which are either cardiac, vascular surgeons or interventionists in both cannulation and decannulation. Banfi et al.<sup>8</sup> suggested that if percutaneous cannulation was performed, surgical approach should be used in decannulation.<sup>8</sup> Not only would open approach lead to less haemorrhage, it allows assessment and repair of vessels as necessary.

Our experience in surgical decannulation has highlighted a few tips for consideration in future practice. Firstly, it is crucial to consider the higher risk of bleeding in this group of patients as they are usually anticoagulated. Technically, a high index of suspicion is necessary for possibility of SFA instead of CFA cannulation as in our case. Furthermore, being mindful of anatomical variant in the groin such as high bifurcation (retroinguinal or retroperitoneal) of femoral vessels and the need for incision such as Rutherford Morrison in those setting or presence of saphena varix which require extra care during dissection. Finally, should patch angioplasty be required in the native vessels, it is prudent to avoid artificial patch such as bovine patch as indwelling sheath may be placed for duration longer than 24 hours with risk of colonisation and having an infected field. Instead, we suggest only using vein patch if reconstruction is considered with copious antibiotics.

## Conclusion

The use of percutaneously placed large bore vessel sheath as incases like ECPR and ECMO will only be on the rising trend as technology advance medicine further. Although new approach like percutaneous closure is promising, having the skills, knowledge and experience in surgical approach to decannulation of these devices would be an invaluable art to all generations of vascular surgeons.

## Acknowledgements

None.

## Conflict of interest

The author declares no conflict of interest.

## References

1. Kolluri R, Fowler B, Nandish S. Vascular access complications: diagnosis and management. *Curr Treat Options Cardiovasc Med.* 2013;15(2):173–87.
2. Yam N, McMullan DM. Extracorporeal cardiopulmonary resuscitation. *Ann Transl Med.* 2017;5(4):72.
3. Conrad SA, Rycus PT. Extracorporeal membrane oxygenation for refractory cardiac arrest. *Ann Card Anaesth.* 2017;20(Supplement):S4–10.
4. Rupperecht L, Lunz D, Philipp A, et al. Pitfalls in percutaneous ECMO cannulation. *Hear lung Vessel.* 2015;7(4):320–326.
5. Napp LC, Kühn C, Hoepfer MM, et al. Cannulation strategies for percutaneous extracorporeal membrane oxygenation in adults. *Clini Res Cardiol.* 2016;105(4):283–296.
6. Mosier JM, Kelsey M, Raz Y, et al. Extracorporeal membrane oxygenation (ECMO) for critically ill adults in the emergency department: History, current applications, and future directions. *Critical Care.* 2015;19:431.
7. Reeb J, Olland A, Renaud S, et al. Vascular access for extracorporeal life support: Tips and tricks. *J Thorac Dis.* 2016;8(Suppl 4):S353–363.
8. Banfi C, Pozzi M, Brunner ME, et al. Venous-arterial extracorporeal membrane oxygenation: An overview of different cannulation techniques. *J Thorac Dis.* 2016;8(9):E875–885.
9. Lamb KM, Hirose H, Cavarocchi NC. Preparation and technical considerations for percutaneous cannulation for venous-arterial extracorporeal membrane oxygenation. *J Card Surg.* 2013;28(2):190–192.
10. Makdisi G, Wang IW. Extra corporeal membrane oxygenation (ECMO) review of a lifesaving technology. *J Thorac Dis.* 2015;7:E166–176.
11. Riggs KR, Becker LB, Sugarman J. Ethics in the use of extracorporeal cardiopulmonary resuscitation in adults. *Resuscitation.* 2015;91:73–75.
12. Organization ELS. *ECLS Registry Report.* 2017.
13. Richardson AS, Schmidt M, Bailey M, et al. ECMO cardio-pulmonary resuscitation (ECPR), trends in survival from an international multicentre cohort study over 12-years. *Resuscitation.* 2017;112:34–40.
14. Kim SJ, Kim HJ, Lee HY, et al. Comparing extracorporeal cardiopulmonary resuscitation with conventional cardiopulmonary resuscitation: A meta-analysis. *Resuscitation.* 2016;103:106–116.
15. Conrad SA, Grier LR, Scott LK, et al. Percutaneous cannulation for extracorporeal membrane oxygenation by intensivists: A retrospective single-institution case series. *Crit Care Med.* 2015;43(5):1010–1015.
16. Hwang JW, Yang JH, Sung K, et al. Percutaneous removal using Perclose ProGlide closure devices versus surgical removal for weaning after percutaneous cannulation for venous-arterial extracorporeal membrane oxygenation. *J Vasc Surg.* 2016;63(4):998–103e1.
17. Majunke N, Mangner N, Linke A, et al. Comparison of percutaneous closure versus surgical femoral cutdown for decannulation of large-sized arterial and venous access sites in adults after successful weaning of venous-arterial extracorporeal membrane oxygenation. *J Invasive Cardiol.* 2016;28(10):415–419.