

Efficacy of Nd: yag laser biostimulation in the treatment of inferior alveolar nerve injury after implant surgery

Abstract

Purpose:Dental implantology has become one of the most used treatment modalities in dentistry. The inferior alveolar nerve can be damaged during implant surgery. There are several treatment methods can be used for alveolar nerve injury and one of them is Low-Level Laser Treatment (LLLT). In present study, the effectiveness of Nd:YAG LLLT was evaluated following implant surgery.

Methods:Four patients who have long-term sensory loss following implant placement in mandible were planned to treat with LLLT. Patients had numbness in their lip, chin and gingival areas and they had undergone implant surgery at least 8 months ago. The patients underwent LLLT with a Nd:YAG laser. Neurosensory tests (2-point discrimination test, visual analog scale) were applied to the patients before and after the laser treatment.

Results:There was no statistical differences in 2 point discrimination test although there were some increased values. The VAS analysis indicated improvement in the quality of life.

Conclusion:LLLT seemed to have positive effects on the reduction of long-term sensory nerve deficit following dental implant applications. Further studies are needed including LLLT to evaluate the postoperative neurosensorial complications of dental implant applications.

Keywords: Nd, YAG laser, biostimulation, low-level laser treatment, implant surgery, VAS

Volume 10 Issue 1 - 2018

Ayrancı F,¹ Sivrikaya EC,¹ Omezli MM,¹ Polat ME,¹ Cezayirli B,¹ Eroglu A²¹Department of Oral Maxillofacial Surgery, Faculty of Dentistry, Ordu University, Turkey²Karadeniz Technical University, Department of Anesthesiology and Intensive Care Medicine, Turkey**Correspondence:** Ahmet Eroglu, Karadeniz Technical University, Department of Anesthesiology and Intensive Care Medicine, Trabzon, Turkey, Email erogluah@hotmail.com**Received:** January 30, 2018 | **Published:** February 14, 2018

Introduction

The inferior alveolar nerve (IAN) is a branch of the trigeminal nerve and this nerve supplies sensation to the ipsilateral lower lip, teeth, and buccal mandibular gingivae. The anatomical position of IAN places this nerve at increased injury risk. During oral surgery, the nerve tissue may be damaged so paresthesia which is characterized by the sensorineural loss that may occur.^{1,2} Neurosensory damage of peripheral innervation still remains a problem which is not treated easily. A solution of this situation may consist of systemic administration of medication, local electrical stimulation, physiotherapy, nerve repair surgery or LLLT.³ The LLLT in dentistry is used before, and LLLT techniques have been in widespread use in all over the world.^{4,5} When applied to oral tissues, it has potential to wound healing, bone healing, restoring neural function after damage and regulation of hormonal functions.⁶⁻⁸ LLLT has a non-thermal and biomodulatory effect on membranes of mitochondria and increases ATP production in cells.⁹ This explains why LLLT have been shown to benefit soft tissue healing.

In dentistry, IAN damage is the most common injury among the other nerves that could result from dental treatment generally just as implant surgery.¹⁰ Over the past 15 years, clinical studies about the effects of LLLT on the treatment of nerve damage after dental operations have been reported.¹⁰ While using of soft tissue has been done with helium-Neon (He-Ne) gas lasers, the laser wavelength for soft tissue can now be produced by a diode laser or Nd:YAG laser devices.¹¹ Nd: YAG 1,064 nm lasers have been successfully used for multiple procedures up to now.¹² Nevertheless, there is a lack of clinical evidence on low-level laser therapy (LLLT) on the recovery of sensitivity after implant surgeries.¹³

In this study, patients feeling numbness at the lower lip were treated with Nd:YAG laser after implant operations. The purpose of this study is to evaluate the effectiveness of LLLT on the recovery of sensitivity after implant surgeries.

Material method

The subjects of this study consisted of 4 (2 male, 2 female) patients with an age range of 50-61 years with a mean of 55.25 years. In these 4 patients, the complaint was post-surgical numbness in the lip and mucosal areas after implant operation between 8 and 12 months. The implants were seen to be related to the alveolar inferior nerve in post-operative x-rays (Figure 1). Patients participating in the present study do not have any previous neurological disorders.

In addition, the panoramic radiographs of Patient I showed the implant material and mandibular canal are close and there has seen bifid mental nerve (Figure 2). Ridge-Split osteotomy was performed on alveolar bone and the implant was placed in the lower right 5th and 7th tooth regions to Patient I. In the Patient II two implants placed in mandibular molar region and numbness on the lip corner occurred in Patient I and II. At patient III and IV, there was numbness in the right lower jaw area and the mucosal area of canine teeth.

In our study, 10 sessions of therapy were given to 4 patients. Nd:YAG laser therapy applied to the numbness side received 8 J/cm² of energy density, a wavelength of 1064 nm for 180 sec each side, and 0.5W at long laser mode with extraoral and intraoral distance of 1cm to take advantage of the biostimulatory effect (Figure 3). Laser therapy was applied every 2 days. A total of 10 sessions were administered. The Nd:YAG laser therapy was applied to multiple areas on both sides of the mandible and lower lip complaints

disappeared. After informing the patient of all possible complications that can occur during and after this therapy, a signed consent form was obtained from the patients. In addition, the patients were described that there may continue temporary numbness in the lower right zone. The study was approved by the Research Ethics Committee at the Faculty of Medicine Blacksea Technical University and the written informed consent was taken from the patients. All of the patients were prescribed B vitamins during laser therapy.

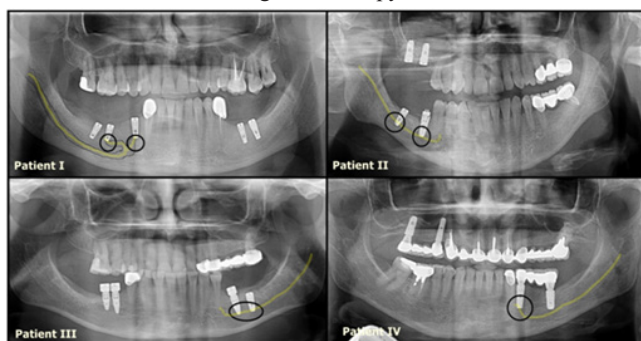


Figure 1 Implants and Nervous Position in Orthopantomogram.

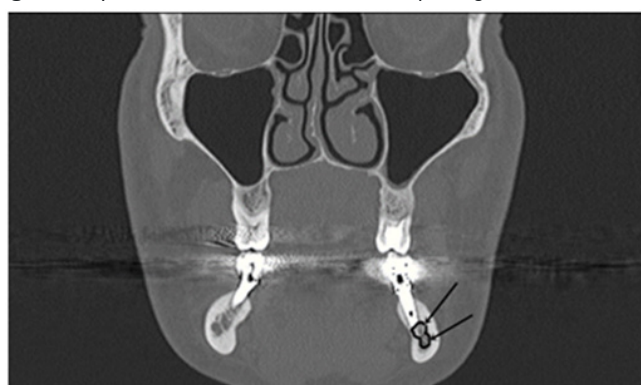


Figure 2 Bifid Mental Nerve (Patient I).

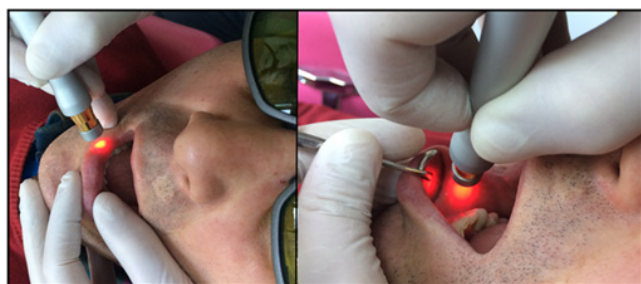


Figure 3 Extra-Oral and Intra-oral Operation Technique.

Assessment

To determine the recovery of nerve damage, both objective and subjective measurements which are 2-point discrimination test, and visual analog scale (VAS) were made in the present study. The 2-point discrimination test was performed with a blunt-ended boley gauge. The region where the numbness is divided into 3 areas. The oral commissure, the tuberculum labii are regarded as the borderline horizontally and junction line of upper and lower lip, menton vertically (Figure 4). The separation values at which the patient felt 2 points were recorded for 3 areas. This process is repeated every session. The arithmetic mean of the values obtained from 3 regions was used when statistical analysis was performed and the table was constructed. Thus, homogeneous data was obtained from the area. VAS was used in the evaluation of subjective data. VAS scale was as follows; '1- Complete

absence of sensation 2- Almost no sensation 3- Reduced sensation 4- Almost normal sensation 5- Fully normal sensation' described previously by Miloro et al.,¹² The patients marked one at each session. After ten sessions, VAS scale completed. The Wilcoxon signed-rank test was used to analyze associations between the variables, comparing preoperative and postoperative. No statistically significant difference was found between values of 2 point discrimination test preoperative and postoperative at the end of the 10 sessions.

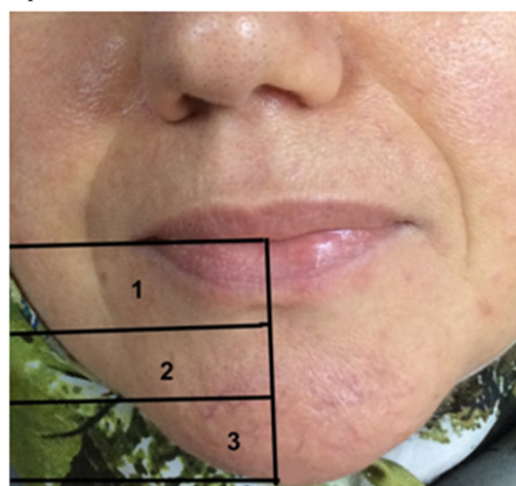


Figure 4 The Region Where the Numbness is Divided into 3 Area.

Results

The data obtained from the patients was presented Table 1.

There was no statistical difference found in values of 2 point discrimination test between pre-operative and post-operative ($P = 0.71$). Although there was no statistical difference in 2-point discrimination analysis, it was seen that the feeling of the patient in two point touch increased. The arithmetic mean of the values obtained from 3 regions was used in Table 2. It is also seen that the first session and the 8th session recovery are more according to the table of mean results for the 2-point discrimination test (Table 2).

Each column represents a different session. The discrimination section is calculated in millimeters.

In addition, patients are reported to have less discomfort at end of the treatment. The VAS scale is the important analysis method at this issue. The patients participating in the study described that their quality of life is increasing (Table 3). Recovery of nerve with Nd:YAG laser therapy was more in patients 3 than others according to 2-point discrimination test. However, she described that is the quality of life lower than the others in the VAS score. Before the treatment started, patient 3 had described that he could not hold his spit on the edge of the lip. Perhaps, because of the numbness in areas lip of corner, the VAS scales were low.

Discussion

The mental nerve, the largest branch of the alveolar inferior nerve, emerges from the mental foramen and divides into 3 branches. These branches innervate the skin of the mental area, mucous membranes, the skin of the lower lip, and the gingiva as far posteriorly as the second premolar.^{15,16} If there is damage to the alveolar inferior nerve, the senses in these regions will suffer.

The inferior alveolar nerve (IAN) damage usually occurs after third molar surgery.^{17,18} Further causes include the enucleation of

pathological lesions, orthognathic surgery, root canal treatment, implant surgery.¹⁹ Incidence in the literature of iatrogenic inferior alveolar nerve injury directly resulting from implant treatment ranges from 0–33.2%.^{20,21} These injuries can cause from mild paresthesia to

complete anesthesia and/or pain. Hereby, many important functions such as speech, eating, and drinking was affected.¹⁶ These influences change patient’s quality of life and psychology negatively.²² Therefore planning treatment is important.

Table 1 The Data Obtained From the Patients

Patient	Age	Gender	Implant Number in Mandibula	Implant Placed Side in Mandibula	Neurosensorial symptom(s)	Neurosensorially Effected Side of Mandibula
Patient 1	54	Male	4	Right–Left	Right Lip Corner Numbness	Right
Patient 2	52	Female	2	Right	Right Lip Corner Numbness	Right
Patient 3	61	Male	4	Right–Left	Numbness in Left Canine Mucosal Area and Lower Jaw Skin	Left
Patient 4	54	Female	2	Left	Numbness in Left Canine Mucosal Area and Lower Jaw Skin	Left

Table 2 Mean Results for The 2–point Discrimination Test

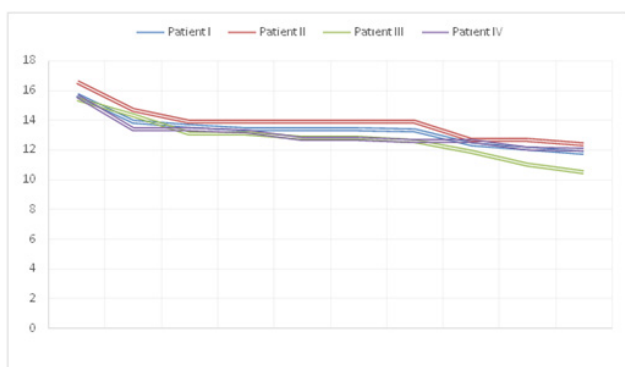
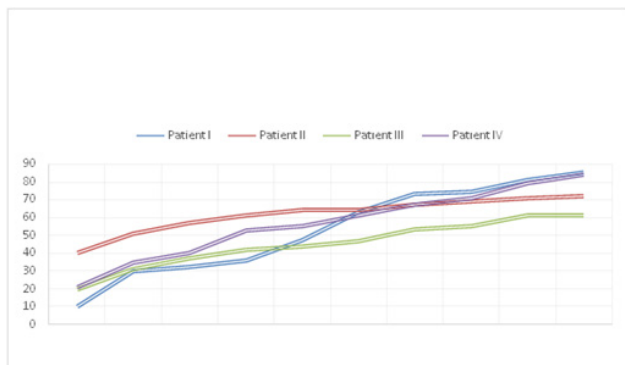


Table 3 VAS Scores in 10 Session



IAN and other nerve injuries are usually iatrogenic and there is no regeneration within 8weeks after injury.²³ To reduce this time, during surgery, if traction or compression of the nerve trunk trauma has occurred, the topical application of intravenous form steroids, one to two milliliters of dexamethasone (4 mg/ml), was applied for 1–2 min.²³ If only a compression injury is suspected, immediate surgical removal of the implant may be necessary for the best prognosis. The literature reports that early implant removal leads to partial and complete resolution, though late intervention may lead to further injury and leave the neuropathy unresolved.^{24,25} If the nerve is thought to be damaged, needs to be repaired and there are various methods for nerve treatment. Nerve microsurgery,^{26,27} electrical stimulation²⁸ stem cell therapy²⁹ and low laser therapy^{5,8,10,19} are currently being investigated. In the present study, the implants traumatized to the IAN by pressure and treated with Nd:YAG low laser therapy. We did not receive CT from each patient. If the IAN was ruptured, laser treatment would be ineffective.

Laser therapy shows the biostimulation effect in the red visible wavelength used in LLLT is specifically absorbed by proteins.³⁰ In addition, LLLT has been reported to support axonal growth in injured nerves model systems in animal experiments.¹¹ However, the photoreceptors responsible for the biological effects of LLLT have not yet been identified.³⁰ Many studies have reported that chromophores in the mitochondrial cytochrome system or in endogenous porphyrins absorb laser energy.^{30,31} We aimed to achieve nerve regeneration by utilizing the effect of laser biostimulation in our study and we see that the paresthesia in the lip area is decreased. In some studies, following implant surgery,^{13,32} endodontic overfilling,³³ third molar surgery,^{10,19,34} mandibular sagittal split osteotomy,³ bisphosphonate–associated osteonecrosis,³⁵ LLLT seemed to be conducive to the reduction of long–standing sensory nerve impairment.

There is no consensus that CBCT scanning or CT effectively reduces IAN damage. Orthopantomography can be useful in implant planning.³⁶ However, strict guidelines do exist enforcing the use of cross–sectional imaging if required to better assess the IAN when routine radiography is inadequate.²² OPGs and other two–dimensional radiographs have disadvantages to show the buccolingual aspect and cross–sectional slices and patient positioning, magnification distortion and superposition of the anatomical structures.^{37,38} In our study, CT was taken after the procedure and there was a correlation between implant and nerve (Figure 1). In order to facilitate drilling efficiency, many implant drills are slightly longer than their corresponding implants and it is possible that the rate of nerve damage^{39,40} In this regard, it is important for the surgeon to be aware of the variations that exist in implant drill length. However, in patient III, the size of the implant used and the drill is same. It is estimated that the compression of the implant results in numbness at the lower right lip. Instead of surgical removal of the implant, not to lose implants, the patient was treated with LLLT therapy. It is advisable to take an operation preliminary CT or prepare implant guide plates.

Conclusion

One of the serious complication of implant operations is alveolar nerve injury. Appropriate surgical management will reduce the incidence of such an unpleasant complication. The results of the present study support previous findings that LLLT therapy has improved the long–lasting sensory disturbances. LLLT treatment appears to reduce long–term sensory nerve impairment after dental implant surgery. Further studies are needed including LLLT to evaluate the postoperative neurosensorial complications of dental implant applications.

Acknowledgments

None.

Conflicts of interest

Gregori Margolin and Jonas Karling are inventors of SafeTrach and shareholders in company SafeTrach AB.

Funding source

None.

References

1. Coulthard P, Kushnerev E, Yates JM, et al. Interventions for iatrogenic inferior alveolar and lingual nerve injury. *Cochrane Database Syst Rev*. 2014;CD005293.
2. Hillerup S, Jensen R. Nerve injury caused by mandibular block analgesia. *Int J Oral Maxillofac Surg*. 2006;35(5):437–443.
3. Gasperini G, de Siqueira IC, Costa LR. Lower-level laser therapy improves neurosensory disorders resulting from bilateral mandibular sagittal split osteotomy: a randomized crossover clinical trial. *J Craniomaxillofac Surg*. 2014;42(5):e130–133.
4. Amorim JC, de Sousa GR, de Barros Silveira L, et al. Clinical study of the gingiva healing after gingivectomy and low-level laser therapy. *Photomed Laser Surg*. 2006;24(5):588–594.
5. Gal P, Mokry M, Vidinsky B, et al. Effect of equal daily doses achieved by different power densities of low-level laser therapy at 635 nm on open skin wound healing in normal and corticosteroid-treated rats. *Lasers Med Sci*. 2009;24(4):539–547.
6. Folwaczny M, Mehl A, Jordan C, et al. Antibacterial effects of pulsed Nd: YAG laser radiation at different energy settings in root canals. *J Endod*. 2002;28(1):24–29.
7. Gronqvist A, Wistrom J, Axner O, et al. Bactericidal effect of pulsed 1,064 nm Nd: YAG laser light on *Staphylococcus epidermidis* is of photothermal origin: an in vitro study. *Lasers Surg Med*. 2000;27(4):336–340.
8. Rochkind S, Drory V, Alon M, et al. Laser phototherapy (780 nm), a new modality in treatment of long-term incomplete peripheral nerve injury: a randomized double-blind placebo-controlled study. *Photomed Laser Surg*. 2007;25(5):436–442.
9. Passarella S, Casamassima E, Molinari S, et al. Increase of proton electrochemical potential and ATP synthesis in rat liver mitochondria irradiated in vitro by helium-neon laser. *FEBS Lett*. 1984;175(1):95–99.
10. de Oliveira Martins D, Martinez dos Santos F, Evany de Oliveira M, et al. Laser therapy and pain-related behavior after injury of the inferior alveolar nerve: possible involvement of neurotrophins. *J Neurotrauma*. 2013;30(6):480–486.
11. Walsh LJ. The current status of low level laser therapy in dentistry. Part 1. Soft tissue applications. *Aust Dent J*. 1997;42(4):247–254.
12. Akinturk S, Eroglu A. A clinical comparison of topical piroxicam and EMLA cream for pain relief and inflammation in laser hair removal. *Lasers Med Sci*. 2009;24(4):535–538.
13. Prados-Frutos JC, Rodríguez-Molinero J, Prados-Privado M, et al. Lack of clinical evidence on low-level laser therapy (LLL) on dental titanium implant: a systematic review. *Lasers Med Sci*. 2016;31(2):383–392.
14. Miloro M, Repasky M. Low-level laser effect on neurosensory recovery after sagittal ramus osteotomy. *Oral Surg Oral Med Oral Pathol Oral Radiol Endod*. 2000;89(1):12–18.
15. Juodzbalys G, Wang HL, Sabalys G. Injury of the Inferior Alveolar Nerve during Implant Placement: a Literature Review. *J Oral Maxillofac Res*. 2011;2(1):e1.
16. Ziccardi VB, Assael LA. Mechanisms of trigeminal nerve injuries. *Atlas Oral Maxillofac Surg Clin North Am*. 2001;9(2):1–11.
17. Kjolle GK, Bjornland T. Low risk of neurosensory dysfunction after mandibular third molar surgery in patients less than 30 years of age. A prospective study following removal of 1220 mandibular third molars. *Oral Surg Oral Med Oral Pathol Oral Radiol*. 2013;116(4):411–417.
18. Tay AB, Zuniga JR. Clinical characteristics of trigeminal nerve injury referrals to a university centre. *Int J Oral Maxillofac Surg*. 2007;36(10):922–927.
19. Ozen T, Orhan K, Gorur I, et al. Efficacy of low level laser therapy on neurosensory recovery after injury to the inferior alveolar nerve. *Head Face Med*. 2006;2:3.
20. Bartling R, Freeman K, Kraut RA. The incidence of altered sensation of the mental nerve after mandibular implant placement. *J Oral Maxillofac Surg*. 1999;57(12):1408–1412.
21. Wismeijer D, van Waas MA, Vermeeren JI, et al. Patients' perception of sensory disturbances of the mental nerve before and after implant surgery: a prospective study of 110 patients. *Br J Oral Maxillofac Surg*. 1997;35(4):254–259.
22. Du Toit J, Gluckman H, Gamil R, et al. Implant Injury Case Series and Review of the Literature Part 1: Inferior Alveolar Nerve Injury. *J Oral Implantol*. 2015;41(4):e144–151.
23. Juodzbalys G, Wang HL, Sabalys G, et al. Inferior alveolar nerve injury associated with implant surgery. *Clin Oral Implants Res*. 2013;24(2):183–190.
24. Renton T, Yilmaz Z. Profiling of patients presenting with posttraumatic neuropathy of the trigeminal nerve. *J Orofac Pain*. 2011;5(4):333–344.
25. Ziccardi VB, Zuniga JR. Nerve injuries after third molar removal. *Oral Maxillofac Surg Clin North Am*. 2007;19(1):105–115.
26. Robinson PP, Loescher AR, Yates JM, et al. Current management of damage to the inferior alveolar and lingual nerves as a result of removal of third molars. *Br J Oral Maxillofac Surg*. 2004;42(4):285–292.
27. Ziccardi VB. Microsurgical techniques for repair of the inferior alveolar and lingual nerves. *Atlas Oral Maxillofac Surg Clin North Am*. 2011;19(1):79–90.
28. Khuong HT, Midha R. Advances in nerve repair. *Curr Neurol Neurosci Rep*. 2013;13(1):322.
29. Levi AD, Guenard V, Aebischer P, et al. The functional characteristics of Schwann cells cultured from human peripheral nerve after transplantation into a gap within the rat sciatic nerve. *J Neurosci*. 1994;14(3 Pt 1):1309–1319.
30. Labbe RF, Skogerboe KJ, Davis HA, et al. Laser photobioactivation mechanisms: in vitro studies using ascorbic acid uptake and hydroxyproline formation as biochemical markers of irradiation response. *Lasers Surg Med*. 1990;10(2):201–207.
31. Lubart R, Wollman Y, Friedmann H, et al. Effects of visible and near-infrared lasers on cell cultures. *J Photochem Photobiol B*. 1992;12(3):305–310.
32. Bagheri SC, Meyer RA. Management of mandibular nerve injuries from dental implants. *Atlas Oral Maxillofac Surg Clin North Am*. 2011;19(1):47–61.
33. Byun SH, Kim SS, Chung HJ, et al. Surgical management of damaged inferior alveolar nerve caused by endodontic overfilling of calcium hydroxide paste. *Int Endod J*. 2016;49(11):1020–1029.
34. Deppe H, Mucke T, Wagenpfeil S, et al. Trigeminal nerve injuries after mandibular oral surgery in a university outpatient setting—a retrospective analysis of 1,559 cases. *Clin Oral Invest*. 2015;19(1):149–157.

35. Vescovi P, Merigo E, Manfredi M, et al. Nd: YAG laser biostimulation in the treatment of bisphosphonate-associated osteonecrosis of the jaw: clinical experience in 28 cases. *Photomed Laser Surg.* 2008;26(1):37–46.
36. Pires CA, Bissada NF, Becker JJ, et al. Mandibular incisive canal: cone beam computed tomography. *Clin Implant Dent Relat Res.* 2012;14(1):67–73.
37. Watson RM, Davis DM, Forman GH, et al. Considerations in design and fabrication of maxillary implant-supported prostheses. *Int J Prosthodont.* 1991;4(3):232–239.
38. Makris N, Stamatakis H, Syriopoulos K, et al. Evaluation of the visibility and the course of the mandibular incisive canal and the lingual foramen using cone-beam computed tomography. *Clin Oral Implants Res.* 2010;21(7):766–771.
39. Alhassani AA, AlGhamdi AS (2010) Inferior alveolar nerve injury in implant dentistry: diagnosis, causes, prevention, and management. *J Oral Implantol.* 2010;36(5):401–407.
40. Murat S, Kamburoglu K, Kilic C, et al. Nerve damage assessment following implant placement in human cadaver jaws: an ex vivo comparative study. *J Oral Implantol.* 2014;40(1):76–83.