

VA-ECMO in Landouzy Sepsis or Tubercular Septic Shock

Abstract

Landouzy-Sepsis (Sepsis tuberculosa acutissima) is a rare presentation of disseminated tuberculosis as shock and multi-organ failure. The condition if not treated promptly causes rapid death in an immunocompromised patient. We report one such case with refractory shock, ARDS, renal failure and liver dysfunction treated with peri-arrest VA-ECMO at our centre. The use of VA-ECMO have been explained in several scenarios for maintaining oxygenation and perfusion in cases of irreversible cardio-respiratory failure. In a developing country like ours, cost of initiating ECMO support has to be contemplated. We were successful in convincing the family to consent for the procedure and we initiated VA-ECMO on this patient after proper counseling of the family regarding possible outcome.

Case Report

Volume 8 Issue 1 - 2017

Chandrashish Chakravarty* and Sourav Burman

Consultant in Critical Care, India

***Corresponding author:** Chandrashish Chakravarty, Consultant in Critical Care, Apollo Gleneagles Hospitals, 58 Canal Circular Road, Kolkata-54, India, Tel: 9830644665; Email: chandrashish.c@gmail.com

Received: February 10, 2017 | **Published:** May 16, 2017

Case Report

A twenty-four year old male (body weight 45 kgs) with no prior medical comorbidities was admitted with a history of fever and respiratory distress for the past three days. He was further diagnosed as disseminated tuberculosis and started on first line anti-tubercular drugs (rifampin 225mg, isoniazid 150mg, pyrazinamide 750mg and ethambutol 400mg) but unfortunately he was intubated and ventilated in view of worsening respiratory distress in an outside hospital. He was haemodynamically unstable and cultures were sent and broad spectrum antibiotics started. He was shifted to our hospital in a critical condition. The sputum for AFB stain and gene Xpert for mycobacterium tuberculosis both came out to be positive. He started to deteriorate and developed severe acute respiratory distress (ARDS) (pH- 7.19, PaCO₂- 43, PaO₂-45, FiO₂-90, lactate- 15 mmol/L). He was started on protective lung ventilation strategy (Vt-240 ml, Pplat-30 cmH₂O, PEEP-10, FiO₂-90). He was on multiple inotropic and vasopressor support. He was diagnosed as Landouzy's sepsis (disseminated tuberculosis with multi-organ failure), when all other cultures came out to be negative.

On day two, his chest x-ray was showing bilateral non-homogenous opacities (more on the left). Ventilation was becoming difficult as his lungs were stiff (compliance 10 ml/cm of water) and oxygenation worsened with optimal PEEP. His haemodynamics decompensated further and transthoracic Echo showed poor contractility (LVEF= 22%) with regional wall motion abnormalities. A diagnosis of septic cardiomyopathy was made secondary to disseminated tuberculosis. On day three, in view of worsening oxygenation (pH-7.24, PaCO₂- 55, PaO₂-44, FiO₂-95, lactate-7 mmol/L) it was decided to put the patient in prone ventilation. Soon after making him prone his oxygenation improved transiently but he became haemodynamically unstable (MAP- 48 mmHg) and an array of inotropic support was continued (Noradrenaline, vasopressin, adrenaline and levosimendan). In the early next morning (day 4), he suffered two episodes of cardiac arrest, immediate cardio-pulmonary resuscitation (CPR) given in supine position, he revived after two cycles of CPR. Blood gas analysis showed gross metabolic acidosis and a lactate of 17.

In view of poor cardiac reserve and worsening lung condition (low compliance 12 ml/cmH₂O) it was decided to put the patient on veno-arterial extracorporeal membrane oxygenator (VA-ECMO) support. Family was counseled regarding cost issues and probable outcome and a multi-disciplinary approach including primary physician, intensivist, cardiac anaesthesiologist and cardiac surgeon was facilitated.

After written consent, VA-ECMO was initiated by the femoro-femoral route. Pump flow was kept at 2.5L/min, oxygen sweep @ 2 L/min. The patient developed shock liver (deranged liver function tests with transaminitis) and he became coagulopathic. Hematologist opinion was taken and dose of all anti-tubercular drugs modified according to liver function. He was stable on ECMO support and his oxygenation improved gradually and lactate started to clear. Over the next two days we were able to taper down our vasopressor support (only Noradrenaline infusion remained) and ventilation became easier as his compliance and oxygenation improved. Dyselectrolytemia was corrected and targets of ECMO was meticulously maintained (Haemoglobin >10g/dl, platelets > 50,000/ mm³, INR < 1.5, fibrinogen >100). Daily blood cultures were sent and every third day sputum cultures were taken. However, we noticed that his pupils were unequal and sluggish reacting (right 2.5mm, left 3mm), urgent neurologist referral was given who opined for EEG and CT or MRI scan when stable. Measures to reduce intracerebral pressure like maintaining hypocarbia and mannitol were instituted. We did not have a bedside CT scanner to quickly diagnose the neurological condition.

On day four of ECMO support, we noticed mild mottling of bilateral lower limbs (right > left). Urgent lower limb arterial Doppler was requested which showed no perfusion in the bilateral dorsalis pedis and very sluggish flow in the right anterior tibial and post tibial arteries. Cardiothoracic surgeon opinion was taken who performed a distal augmentation of arterial flow over the right limb by repositioning the distal perfusion cannulae. After the procedure, a repeat ultrasound failed to show any improvement and the possibility of below knee amputation on the right side was discussed with family. Antibiotics were escalated

and adequate gram positive cover was started (tigecycline) and adequate care of the limbs taken. On day five of ECMO support, repeat transthoracic echo showed that better contractility with LVEF- 40% and his haemodynamics improved, he was off all inotropic support, his lung condition was better and oxygenation requirements were climbing down. We reduced the FiO₂ to 0.4 and oxygen sweep was reduced to 1litre/min. EEG was done which showed epileptiform discharges and he was put on combined anti-epileptic drugs (fosphenytoin and levetiracetam).

On day nine it was decided to discontinue ECMO support. All cultures were sterile so far. His legs improved and a repeat Doppler study showed normal flows on the left side and near

normal flows on the right side, hence amputation was best avoided. We did MRI of the brain which showed gross cerebral edema with focal haemorrhagic spots and supratentorial ventriculomegaly with hypoxic changes in the midbrain and basal ganglia. Neurologist said that he had a very poor prognosis and opined for a tracheostomy and neurosurgery consult in view of raised intracranial tension. Neurosurgeon opined for conservative management as he had a tight brain and there was no space in the ventricles to put in an endo-ventricular drain (EVD). He remained neurologically poor (withdraws and opens eyes to painful stimulus E2M4, pupils unequal and sluggish reacting) was discharged to a smaller facility for neuro-rehabilitation.

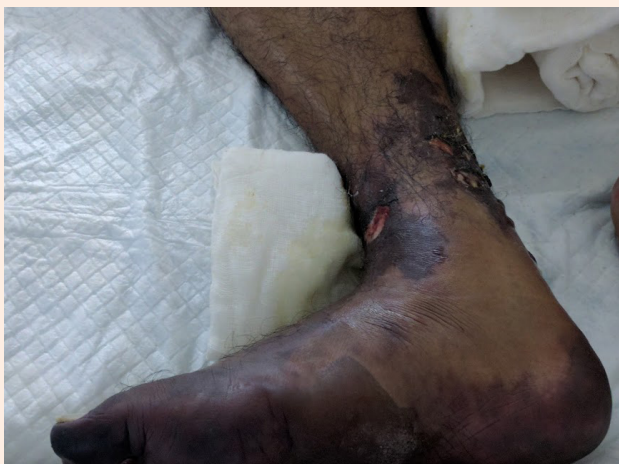

Figure 1: Ischemic Right Foot.

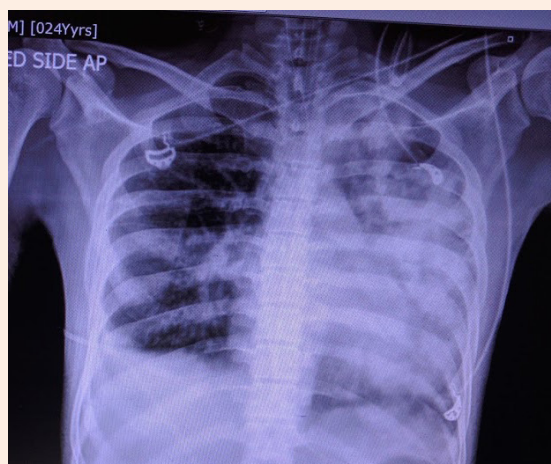


Figure 2: Chest X Ray.

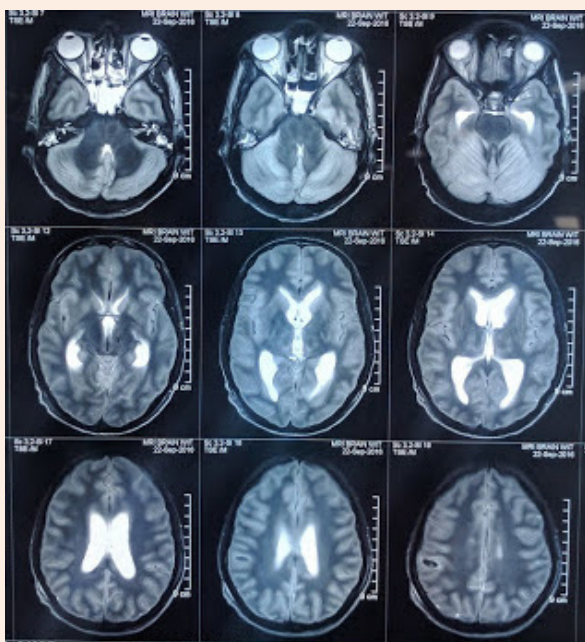


Figure 3: MRI Brain showing micro bleeds and midbrain hypoxic change.




Figure 4: ECMO circuit.

Discussion

ECMO (Extra corporeal membrane oxygenation) is a new and established modality of oxygenation and maintaining circulation when conventional ventilation or hemodynamic support is exhausted. It is also important for providing valuable time in bridging the gap between definitive management like ventricular assist devices and heart lung transplantation. Two major types of ECMO are used. The veno-arterial (VA) ECMO is chiefly designed to serve both purposes of cardio-pulmonary assistance in severe cardiogenic shock and veno-venous (VV) ECMO provides primary lung support. Landouzy's sepsis [1] in disseminated tuberculosis is a rapidly progressive entity, and it leads to multi-organ failure and death in an immunocompromised person if not treated aggressively. This entity was first described by Parisian neurologist Louis Theophile Joseph Landouzy (1845-1917). Most of such cases have been reported from South-East Asia. Our patient was a young boy, not immunosuppressed but developed rapid progressive disease with severe ARDS and cardiogenic shock. Our patient was not adequately managed with multiple inotropes, we added levosimendan as a drug effective in acute cardiac failure cases. Levosimendan is an inodilator and it has cardioprotective action by acting on the potassium channels at the sarcolemma of cardiomyocytes [2]. Despite all such efforts our patient was sinking and we ECMO support was the call of the hour.

Studies with VA-ECMO in children has a survival rate of 88% but in critically ill adults the favourable outcome widely varies [3]. There have been recent advances in ECMO technology, which has incorporated improvement in biocompatibility, monitoring and membrane lung oxygenation, but the role of VA-ECMO in septic shock is largely debated. The growing evidence and role of ECMO in peri-arrest situation has been reviewed recently [4] and we used it in our patient as a final attempt, considering his young age and treatable disease condition. Over the period 2003–2014 in the ELSO registry, survival to hospital discharge was 29% for patients who require ECPR [5]. In our case we used the femoral route and we faced some complications like limb ischaemia, which was appropriately managed, and we were able to salvage the limbs of our patient. The liver function per se deteriorated as he was on antitubercular drugs (pyrazinamide and rifampicin) and eventually shock contributed to low hepatic perfusion. We do not have the facility to perform thromboelastography (TEG) in our institute. The institution of VA-ECMO in our patient did improve the cardiac function in our patient dramatically within a span of one week (LVEF improved to 40%) and his lung compliance gradually improved and we were able to decrease oxygen requirements and ventilatory parameters steadily. The neurological status was

a cause of concern especially in the backdrop of a hypoxic brain damage after cardiac arrest. The multiple punctate hemorrhages are typical of ECMO related CNS injury [6,7]. There are several trials reporting the incidence of nosocomial infection as high as 64% while on ECMO support [8], but fortunately we had sent every alternate day blood cultures, which were sterile.

VA-ECMO may thus be life saving in specific patient population especially with severe cardiac dysfunction [9]. The economic burden and complications of ECMO especially related to bleeding in vital organs or ischemic damage to limbs should be explained and taken care of.

References

1. Geiss HK, Feldhues R, Niemann S, Nolte O, Rieker R (2005) Landouzy septicemia (sepsis tuberculosa acutissima) due to *Mycobacterium microti* in an immunocompetent man. *Infection* 33(5-6): 393-396.
2. Nieminen MS, Fruhwald S, Heunks LMA, Suominen PK, Gordon AC, et al. (2013) Levosimendan: current data, clinical use and future development. *Heart Lung Vessel* 5(4): 227-245.
3. Tramm R, Ilic D, Davies AR, Pellegrino VA, Romero L, et al. (2015) Extracorporeal membrane oxygenation for critically ill adults. *Cochrane Database Syst Rev* 22: 1.
4. Kehrl T, Kaczorowski DJ (2016) Extracorporeal life support for cardiopulmonary resuscitation for adults: evolving evidence. *ASAIO J* 62(4): 364-369.
5. Richardson (2016) ECMO Cardio-Pulmonary Resuscitation (ECPR), trends in survival from an international multicentre cohort study over 12-years. *Resuscitation* 112, 34-40.
6. Barrett CS, Bratton SL, Salvin JW, Laussen PC, Rycus PT, et al. (2009) Neurological injury after extracorporeal membrane oxygenation use to aid paediatric cardiopulmonary resuscitation. *Pediatr Crit Care Med* 10(4): 445-451.
7. Rollins MD, Hubbard A, Zabrocki L, Barnhart DC, Bratton SL (2012) Extracorporeal membrane oxygenation cannulation trends for pediatric respiratory failure and central nervous system injury. *J Pediatr Surg* 47(1): 68-75.
8. Schmidt M, Bréchet N, Hariri S, Guiguet M, Luyt CE, et al. (2012) Nosocomial Infections in Adult Cardiogenic Shock Patients Supported by Venoarterial Extracorporeal Membrane Oxygenation. *Clin Infect Dis* 55(12): 1633-1641.
9. Schmidt M, Burrell A, Roberts L, Bailey M, Sheldrake J, et al. (2015) Predicting survival after ECMO for refractory cardiogenic shock: the survival after veno-arterial-ECMO (SAVE)-score. *Eur Heart J* 36(33): 2246-2256.