

Anterior Quadratus Lumborum Block Versus Transversus Abdominis Plane Block with Liposomal Bupivacaine: A Case Report

Abstract

A more posterior approach for abdominal wall blocks was described by Dr. Blanco as Quadratus Lumborum (QL) block. We performed the first reported transmuscular QL block using liposomal bupivacaine. We are describing the technique we used as well as other approaches used for QL block. This case report showed that QL block using a single dose of Liposomal Bupivacaine provided a sensory level and analgesia for 2 days. Our limited experience shows that this new type of block can prolong the analgesia along mid and lower thoracic dermatomes.

Introduction

Conventional approaches to transversus abdominis plane block (TAP) is one of the options that creates satisfactory somatic analgesia with minimal or no visceral blockade [1]. Therefore, a more posterior approach that injects the local anesthetic adjacent to quadratus lumborum (QL) muscle has been sought for to potentially provide the patients with more visceral blockade and thus better analgesia [2,3]. Moreover, the effective period of this block can be prolonged by using liposomal bupivacaine [4]. This is the first report demonstrating injection of liposomal bupivacaine for a QL block.

Description of the Case

Institutional Review board of Cleveland Clinic waived written consent since there was no patient identifying information. The patient was a 32-year-old male with body mass index of 21.07 kg/m² who was scheduled for a subtotal colectomy in the setting of ulcerative colitis. The surgery was scheduled to be performed through a midline incision extending from above the umbilicus to pubic symphysis. Preoperatively, our acute pain management service was consulted. The patient was initially offered an epidural catheter, which he refused due to previous ineffective analgesia. Thereafter, TAP and QL blocks were offered to the patient and the risks and benefits were explained. It was also explained to the patient that QL blocks and Liposomal bupivacaine use are not investigated thoroughly yet. The patient expressed understanding and agreed to proceed with the proposed set of blocks. The patient subsequently received a left QL (trans-muscular approach, type 3) and a right TAP single shot block for postoperative pain control to allow the right side to serve as a "control". The blocks were performed in the induction room, with routine monitoring and midazolam (2 mg IV) sedation.

The patient was initially placed in right lateral decubitus position. After sterile prepping and draping, a low frequency (2-5 MHz) curved array ultrasound transducer (Mindray, Nanshan, Shenzhen, China) covered in sterile plastic sheath was placed in the anterior axillary line between the subcostal margin and the

iliac crest to identify the typical triple abdominal muscle layers. As the probe was moved posteriorly to the posterior axillary line the appearance of fascia transversalis (anterior thoraco lumbar fascia) and QL was noticed (Figure 1). A 22-gauge 6-inch non-stimulating, echogenic needle (Ultraplex by B Braun, Bethlehem, PA, USA) was inserted in an anterior to posterior direction using an in-plane view with the ultrasound beam. The needle directed toward the fascial plan between the QL and the Psoas muscle; the correct position of the needle tip was then confirmed by injecting 3 mL of saline to separate the fascial layers at the lateral aspect of the QL muscle. Thereafter, the needle was advanced more posteriorly between the quadratus muscle and psoas major muscle; (anterior to the QL muscle, between the epimysium of the QL muscle and the ATLF) another 3 mL of saline was injected. After negative aspiration, 25 mL of the local anesthetic (1.3% liposomal bupivacaine (133 mg) mixed in 25 ml of normal saline) were injected in aliquots of 5 mL over a period of two minutes while the patient was being closely monitored (Figure 1). The dose is extrapolated from the recommendations of the manufacturing company (Pacira Pharmaceutical Inc., Parsippany, NJ, USA). The patient was then positioned on the contra lateral side to perform the block on the other side. The same local anesthetic mixture (as described above) was injected for the TAP block.

Assessment 30 minutes after the block revealed decreased sensation to cold below and above the umbilicus on the left side (T7-L1) while decreased sensation was present only below the umbilicus on the right side (T10-T12). The sensation was checked daily using alcohol swab twice daily (during morning pain rounds and evenings performed by members of our institution's acute pain management service; none of the authors of the manuscript were involved in daily assessment of the patient). Decreased sensation on the left side was observed between T8-L1 for about

Case Report

Volume 6 Issue 1 - 2016

Hesham Elsharkawy^{1*}, Vafi Salmasi², Loran Mounir Soliman², Wael Ali Sakr Esa² and Rafael Blanco³

¹Anesthesiology Institute and Department of Outcomes Research, Cleveland Clinic, USA

²Anesthesiology Institute, Cleveland Clinic, USA

³Consultant Anesthetist, Corniche Hospital, UAE

***Corresponding author:** Hesham Elsharkawy, Department of Anesthesiology, Anesthesiology Institute and Department of Outcomes Research, CCLCM of Case Western Reserve University, USA, Tel: +1-(216)-445-3783; Fax: +1 (216)-444-2294; Email: elsharh@ccf.org

Received: July 11, 2016 | **Published:** November 01, 2016

48 hours while on the right side was from T10 to L1 and was resolved completely within 24 hours after the block. Since the surgical team decided to extend the incision to xiphoid process during the surgery, pain at the upper part of the incision (above T8 dermatome) was not well controlled postoperatively. An intravenous hydromorphone 0.2-0.4 mg every 2 hours was started to allow better pain control at the upper part of the incision. The patient reported his pain scores ranging from two to four in the first 72 hours after operation in the Verbal Response Score (VRS) system mainly because of muscle spasm and pressure sensation, not the incisional pain. Patient reported more pain on the right

side of his abdomen than the left as well as the upper part of the incision under the xiphoid process.

He received a total of 190 mg of equivalent intravenous morphine dose in the form of hydromorphone, oxycodone and fentanyl combined during this time. The patient was started on clear liquid diet on postoperative day one; first stoma output was observed on postoperative day two; urinary catheter was removed on postoperative day three without urinary retention. The patient was discharged from hospital without any complications on postoperative day five.

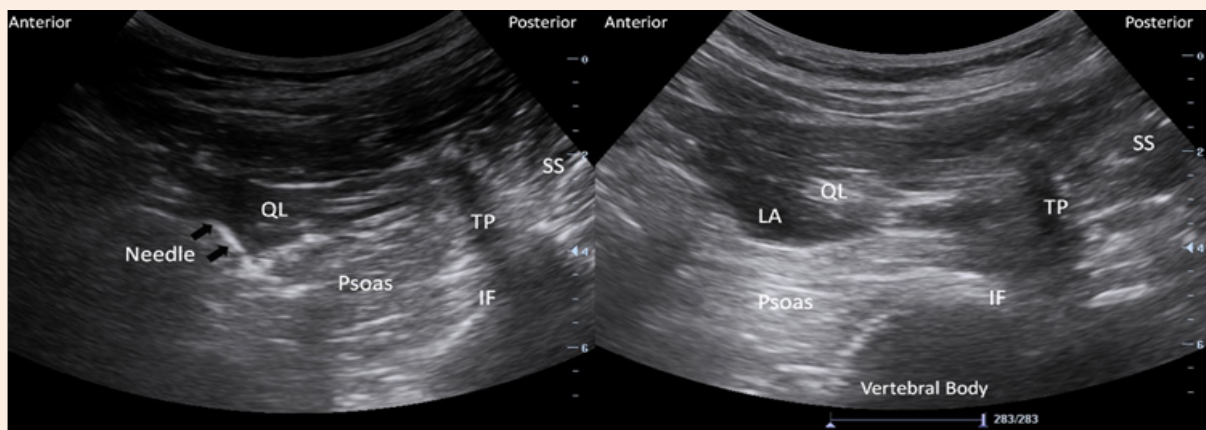


Figure 1: Illustrates the insertion of needle on the left side followed by deposition of local anesthetic on the right side posterior to QL muscle between QL and psoas muscles in type 3 QL block, IF: Inter-Vertebral Foramen; LA: Local Anesthetic; QL: Quadrates Lumborum; SS: Sacro Spinalis; TP: Transverse Process.

Discussion

This patient experienced consistent sensory blockade in the distribution of the corresponding dermatomes for about 48 hours. For comparison of the spread of local anaesthetic and the sensory level, the patient received a TAP block on the contra lateral side, which did not cover the whole length of the incision; therefore, additional opioids were used to achieve satisfactory pain control. Even though Carney described that local anaesthetic can spread to levels as high as T5 [5], the highest level of sensory blockade we achieved postoperatively in our patient was T7 which is more consistent with the result observed by Kadam [2].

Several reports have shown that local anesthetic injection or infusion about the quadratus lumborum is effective in providing pain relief after various abdominal operations and in patients with chronic pain [2,3,6-10]. Moreover, QL block has the potential to provide some visceral analgesia considering its spread to paravertebral and potentially epidural spaces [5]. Quadratus Lumborum block (QLB) results in a wider sensory blockade compared to TAP block (T7-L1 for QL block vs. T10-T12 for the TAP block). Ultrasound-guided TAP blocks might not be able to produce a sensory level above the umbilicus consistently unless a subcostal injection is added [5,11]. The localized effects of the TAP block have a minor contribution to the pain control in comparison with analgesia achieved by extension of local anesthetic into paravertebral space.

In contrast, more posterior approaches, using landmark or US resulted in a predominantly posterior spread of contrast around the QL to the paravertebral spaces from T5 to L1 [3,5]. It is notable that, despite using the same local anesthetic mixture, the apparent duration of effect on the QLB side was four times as long as on the TAP side (48 vs. 24 hours). Possible explanation is that QL block does not result in lateral spread of the local anesthetic and potentially results in more spread to the thoracic paravertebral space.

This block can be performed many different ways. After observing the tapering of the abdominal muscle layers under ultrasound, the needle can be directed from anterior to posterior towards the junction of tapered abdominal muscle layers and QL muscle; local anesthetic will then be deposited lateral to QL muscle and superficial to the fascia transversalis (Lateral QL block or type 1). By advancing the needle posteriorly local anaesthetic can be deposited posterior to the QL muscle: between the QL muscle and the erector spinae, latissimus dorsi, and Serratus posterior inferior (Posterior or QL block type 2). Alternatively, the needle can be advanced from posterior to anterior through erector spinae muscle or through QL (Anterior, trans-muscular approach, or QL type 3) to deposit the local anaesthetic at the space between the epimysium of the QL and psoas major muscles (Figures 2 & 3). The same deposition of local anaesthetic can also be achieved by directing the needle from anterior to posterior

through the QL muscle. There are no studies comparing the safety and efficacy of these three types of QL block. The optimal positioning of the needle tip and spread of the local anesthetic is still to be investigated in studies.

The anterior layer of thoraco-lumbar fascia (fascia transversalis) and QL muscle usually appears as a hyperechoic thick layer which forms a safe land mark to separate the muscle layers from the peri-nephric fat and the abdominal contents. Alternatively, ultrasound transducer can be positioned 4-5 cm lateral to the lumbar spinous process at the L3-4 level. At this level, the transverse process of the 3rd. or 4th lumbar vertebrae, erector spinae muscle, psoas major muscle and the QL can be identified as described by Børghlum et al. [12] as Shamrock's sign.

We noticed that QL muscle usually looks like a small boat hooked to a stick (transverse process of lumbar vertebrae) and the psoas muscle looks like water under the QL muscle and is usually hyperechoic at this level because of its intramuscular fibrous tendons structure and also being surrounded by thick fibrous thoracolumbar fascia. We verified the QL location in two views; the oblique transverse view at the level of transverse process and also at inter-transverse process view where the psoas muscle can be clearly imaged by avoiding the acoustic shadow of the transverse process. The transducer needs to be slightly tilted medially to produce an oblique transverse view and then the ultrasound beam can be insonated either at the level of the transverse process or through the space between the two transverse processes where the articular process of the facet joint can be seen. The procedure can be done using either of these two views; however, we suggest doing the procedure with the transverse process in view as an easy identifiable landmark.

Here are some helpful tips for the performance of the block:

- A. If you start the ultrasound scan close to the transverse process, the muscle appears to be thin as it is visualized at its tendinous section, 2-3 cm lateral from the transverse process

the muscle. Also, the thoraco-lumbar fascia appears thicker and easier to be identified.

- B. When hip is abducted and laterally flexed towards the same side of the muscle, QL will appear tense and contracted. This leads to muscle movement and thickening which can be more easily detected by ultrasound and help its identification.
- C. While performing the block, it is common to visualize the lower pole of the kidneys and lower lobe of the liver and spleen.
- D. We recommend scanning the area applying colour Doppler before insertion of the needle to detect the abdominal branches of the lumbar arteries on the posterior aspect of the quadratus lumborum muscle.

Liposomal bupivacaine has been mostly used for infiltration of the surgical wound to benefit its ultra long-acting effect. It can also be used for TAP blocks according to FDA approved labelling. But there are no guidelines on the volume of drug to be injected or single level injection versus multiple level injections in the same fascial plan. Furthermore, Viscusi et al. [13] described the properties of liposomal bupivacaine when injected in epidural space in a small series of 30 healthy volunteers; liposomal bupivacaine does not increase the incidence of complications [13]. We proceeded with using this medication in our patient to benefit from its long term opioid sparing properties without a potential for complication even if spread into lumbar paravertebral or epidural spaces occurred.

This case report showed that a single dose of Liposomal Bupivacaine of 133 mg injected in QL block in one side provides a sensory level and analgesia for 2 days postoperatively. Our limited experience shows that this new type of block can create sensory blockade and analgesia along mid and lower thoracic dermatomes and can prolong the analgesia for appropriately selected abdominal surgeries. However, efficacy and safety of this block is subject to further studies.

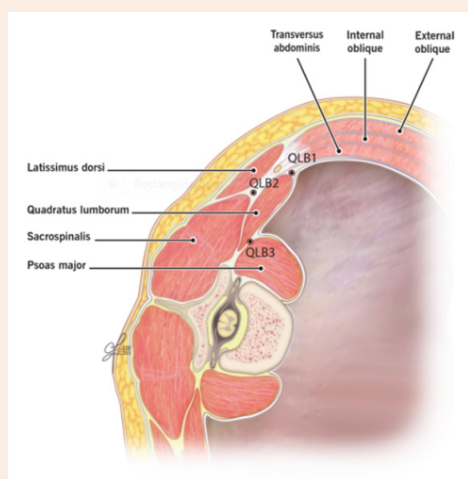


Figure 2: Illustrates injection points of QLB1, QLB2 and QLB3 (transmuscular).

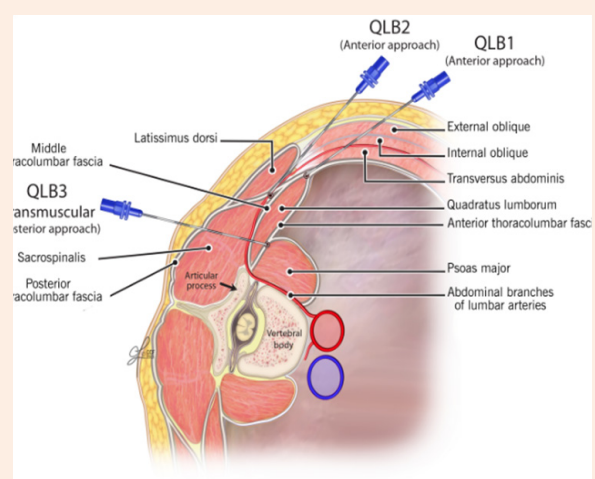


Figure 3: Illustrates trajectory of needle for different types of QL block.

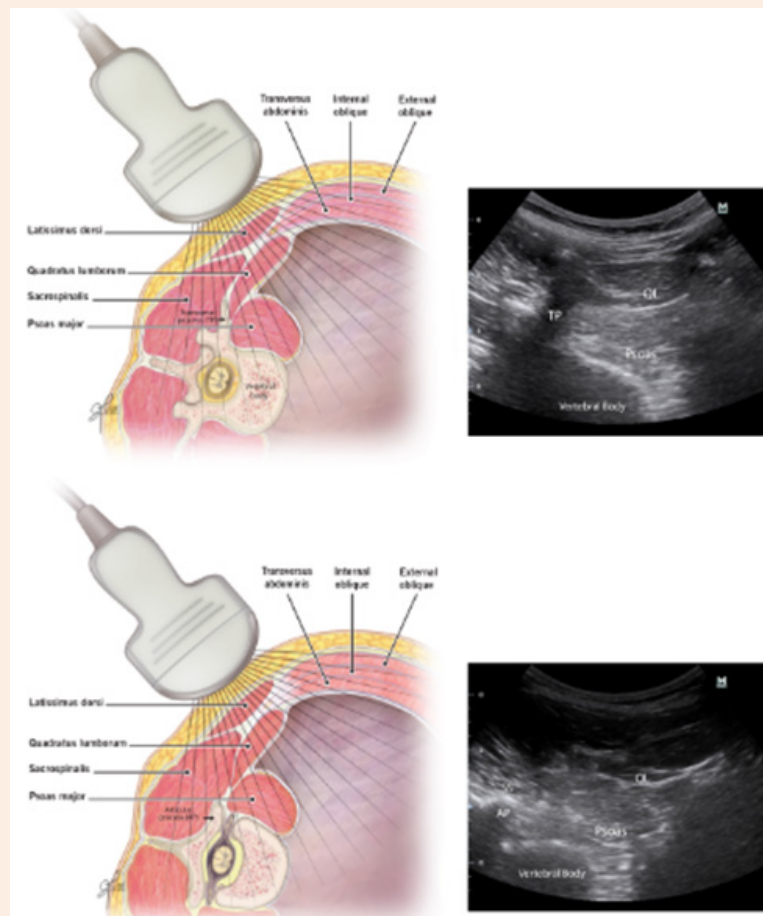


Figure 4: Illustrates the scanning technique to identify QL, psoas and ES muscles at the level of transverse process (top left) and between two transverse processes with correlating ultrasound images on the right.

AP: Articular Process; IF: Inter-Vertebral Foramen; Q: Quadrates Lumborum; SS: Sacro Spinalis; TP: Transverse Process

References

1. Abrahams MS, Horn JL, Noles LM, Aziz MF (2010) Evidence-based medicine: ultrasound guidance for truncal blocks. *Reg Anesth Pain Med* 35(2 Suppl): S36-S42.
2. Kadam VR (2013) Ultrasound-guided quadratus lumborum block as a postoperative analgesic technique for laparotomy. *J Anaesthesiol Clin Pharmacol* 29(4): 550-552.
3. Visoiu M, Yakovleva N (2013) Continuous postoperative analgesia via quadratus lumborum block-an alternative to transversus abdominis plane block. *Paediatr Anaesth* 23(10): 959-961.
4. Chahar P, Cummings KC 3rd (2012) Liposomal bupivacaine: a review of a new bupivacaine formulation. *J Pain Res* 5: 257-264.
5. Carney J, Finnerty O, Rauf J, Bergin D, Laffey JG, et al. (2011) Studies on the spread of local anaesthetic solution in transversus abdominis plane blocks. *Anaesthesia* 66(11): 1023-1030.
6. Chakraborty A, Goswami J, Patro V (2015) Ultrasound-guided continuous quadratus lumborum block for postoperative analgesia in a pediatric patient. *A A Case Rep* 4(3): 34-36.
7. Murouchi T, Iwasaki S, Yamakage M (2016) Quadratus Lumborum Block: Analgesic Effects and Chronological Ropivacaine Concentrations After Laparoscopic Surgery. *Reg Anesth Pain Med* 2016 41(2): 146-150.
8. Kadam VR (2015) Ultrasound guided quadratus lumborum block or posterior transversus abdominis plane block catheter infusion as a postoperative analgesic technique for abdominal surgery. *J Anaesthesiol Clin Pharmacol* 31(1): 130-131.
9. Shaaban M, Esa WA, Maheshwari K, Elsharkawy H, Soliman LM (2015) Bilateral Continuous Quadratus Lumborum Block for Acute Postoperative Abdominal Pain as a Rescue After Opioid-Induced Respiratory Depression. *A A Case Rep* 5(7): 107-111.
10. Blanco R, Ansari T, Girgis E (2015) Quadratus lumborum block for postoperative pain after caesarean section: A randomised controlled trial. *Eur J Anaesthesiol* 32(11): 812-818.
11. Hebbard PD (2009) Transversalis fascia plane block, a novel ultrasound-guided abdominal wall nerve block. *Can J Anaesth* 56(8): 618-620.

12. Børglum J, Jensen K, Moriggl B, Lönnqvist P, Christensen A, et al. (2013) Ultrasound-Guided Transmuscular Quadratus Lumborum Blockade British Journal of Anesthesia (BJA).
13. Viscusi ER, Candiotti KA, Onel E, Morren M, Ludbrook GL (2012) The pharmacokinetics and pharmacodynamics of liposome bupivacaine administered via a single epidural injection to healthy volunteers. Reg Anesth Pain Med 37(6): 616-622.