

# Advanced 11 weeks CS scar ectopic pregnancy. A case report

## Abstract

Cesarean scar pregnancy (CSP) is a rare form of ectopic pregnancy where implantation occurs into the scar of previous uterine incision. However, the rates are escalating rapidly with associated risks of hemorrhage, uterine rupture and hysterectomy. Thus, early diagnosis and proper individualized management are of utmost importance to avoid the serious morbidities. We present a case of an 11-week - gestation scar pregnancy. Laparotomy with excision and re-suturing was the chosen method of management, with no complications.

**Keywords:** cesarean section, scar pregnancy, hemorrhage, ultrasound diagnosis, CSP, CRL

Volume 4 Issue 3 - 2018

Rania H M Ahmed,<sup>1</sup> Ihab S Allam,<sup>2</sup> Adel Elkady<sup>3</sup>

<sup>1</sup>Lecturer Obstetrics & Gynecology, Ain Shams University, Egypt

<sup>2</sup>Professor Obstetrics & Gynecology, Ain Shams University, Egypt

<sup>3</sup>Honorary Consultant, Boulak ElDakror Hospital, Cairo Egypt

**Correspondence:** Adel Elkady, DGO- FRCOG – FICS, Honorary Consultant, Department of Obstetrics and Gynaecology, Boulak ElDakror Hospital, Giza, Egypt, Tel 00 2010 0660 2960, Email dr@thewomenhealth.com

Received: March 28, 2018 | Published: May 14, 2018

## Introduction

The rates of cesarean section (CS) are increasing worldwide. The highest rate countries are: Dominion Republic 56.4%, Brazil 55.6%, Egypt 51.8%, Turkey 50.4%, Iran 47.9%, and China 47%.<sup>1</sup> As a consequence, there's an increasingly rising rate of subsequent serious complications as uterine rupture, morbidly-adherent placenta, and cesarean scar pregnancy (CSP). Diagnosis of CSP is challenging and needs a high index of suspicion together with good imaging modalities. Management is even more challenging, owing to lack of randomized controlled trials in the face of variable treatment modalities for the different case presentations.

## The case report

A 27-year-old female patient, G4P3, all delivered by cesarean section, last 3 years ago, presented with a history of 11 weeks amenorrhea and a positive urine pregnancy test. She started to complain of infrequent mild lower abdominal pain, associated with mild vaginal bleeding; for which she sought medical advice.

On examination: she was vitally stable, with lax abdomen but with mild suprapubic tenderness. Per vaginal examination showed that the cervix was closed, and there was no fullness in Douglas pouch. Ultrasound (both abdominal and transvaginal) (Figure 1) showed: an empty uterine cavity with endometrial thickness 17mm, and a gestational sac seen outside the uterine cavity in the uterovesical pouch, connected to the endometrium at the site of CS scar. The gestational sac showed a single non-viable fetus with crown rump length (CRL) 42mm, corresponding to 11 weeks. Both adnexae were free, and there was no fluid collection; neither in Douglas Pouch nor in the uterovesical pouch.

Laboratory tests showed hemoglobin level 10.4g/dl and her blood group "O+ve". There was no need to carry out a BhCG titre as it was clear this is a non-viable 11 weeks. Owing to the gestational age

(11 weeks), the size, the site of the sac with suspicion of uterine scar dehiscence; and an unviable pregnancy, and after the patient has been counseled and the facts explained; she consented to laparotomy and removal of the gestation sac.

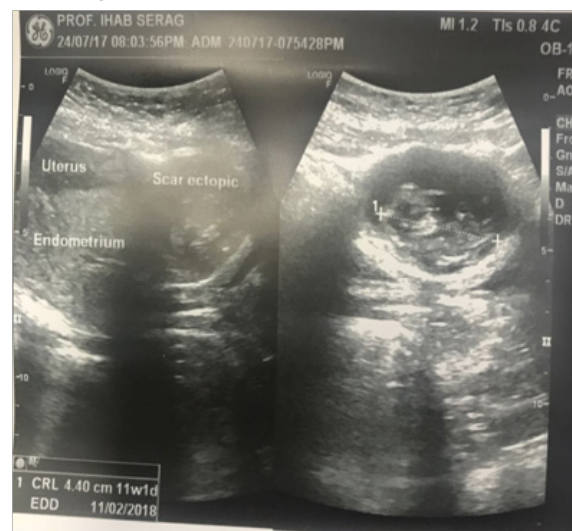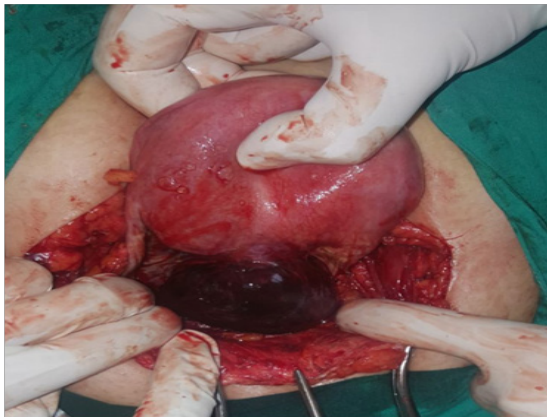


Figure 1 Ultrasound findings

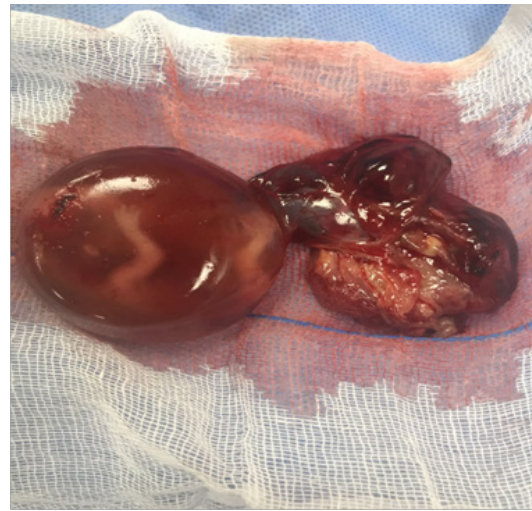
At laparotomy, an intact gestational sac was found bulging out of the uterus through a dehiscence CS scar (Figure 2). The sac was gently dissected off the bladder (Figure 3) (Figure 4) and then removed.

The chorionic tissue was found adherent to the scar, so was excised with trimming of the scar (Figures 5–7). Closure of the uterus was done in 2 layers (Figure 8).

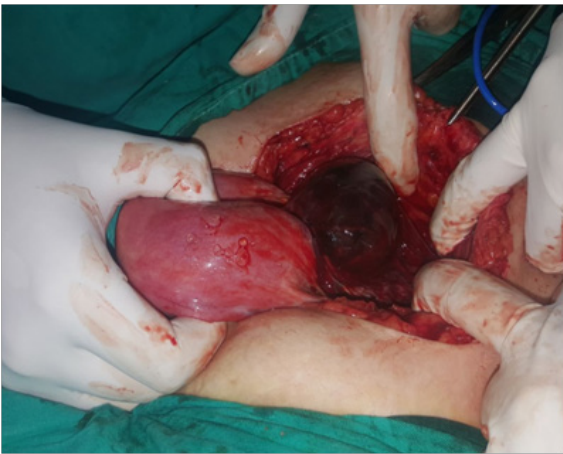
There was little intraoperative bleeding with an estimated blood loss of 400cc. Postoperative period passed smoothly, and the patient didn't receive blood transfusion.



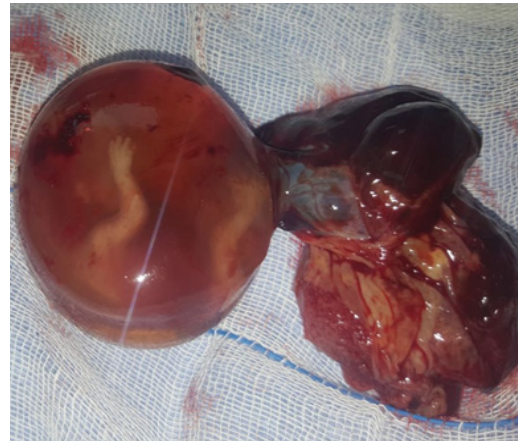
**Figure 2** An intact gestational sac bulging out of the uterus through a dehiscence CS scar



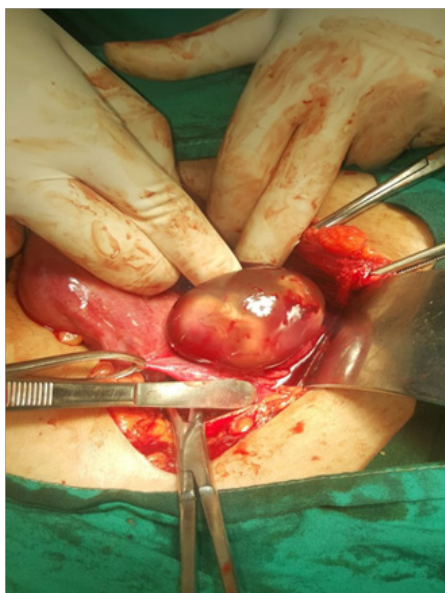**Figure 5** The gestational sac and the chorionic tissue



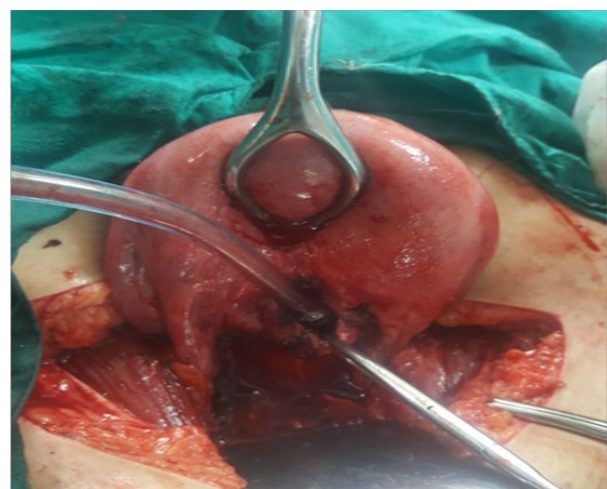
**Figure 3** Dissection of the sac off the bladder in the uterovesical space



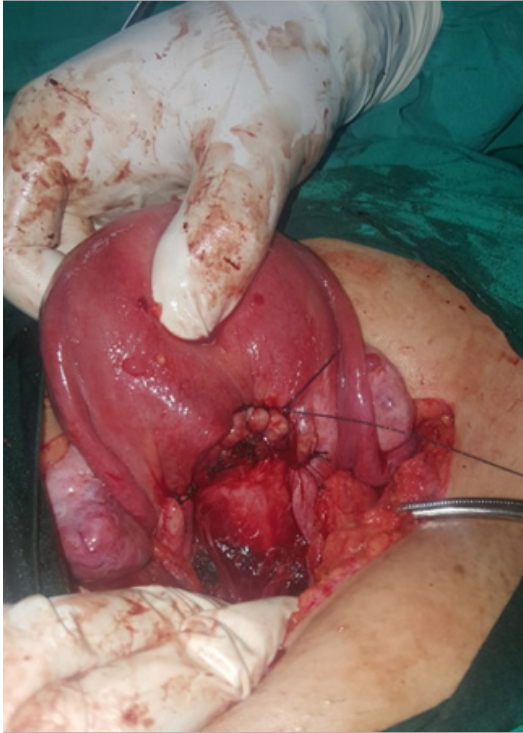
**Figure 6** The removed gestational sac and chorionic tissue



**Figure 4** Completion of dissection and removal of the sac



**Figure 7** The dehiscence gap after removal of the sac and trimming the scar site



**Figure 8** Closure of the uterus

## Discussion

Cesarean scar pregnancy occurs due to implantation of the gestational sac into a myometrial defect at the site of previous uterine incision.<sup>2,3</sup> It's a very rare form of ectopic pregnancy, with an estimated incidence ranging from 1/1800 to 1/2500 of all pregnancies.<sup>4</sup> The first case of CSP was described in 1978, and until 2001 only 19 cases were reported.<sup>1</sup> Recently, the frequency of reported cases has dramatically increased with a recent estimate that 4.2% of ectopic pregnancies are CSP.<sup>1</sup>

In a study published in 2017, in a tertiary hospital in the School of Medicine, Zhejiang University, People's Republic of China, a total of 1348 women were diagnosed during the study period (between March 2011 and September 2014).<sup>3</sup>

This dramatic increase in prevalence of CSP is in part due to higher rates of CS, but it's also attributable to better ultrasound diagnosis on basis of high index of suspicion and clinical awareness. Some cases may be asymptomatic, while others may present with abdominal pain and vaginal bleeding or hemodynamic instability.<sup>4</sup> Ultrasound is the diagnostic modality of choice, using transvaginal approach supplemented by abdominal approach as required.<sup>2</sup> Ultrasound criteria for diagnosis of CSP<sup>4</sup> are:

- I. Empty uterine cavity and closed and empty cervical canal
- II. Placenta and/or a gestational sac embedded in the scar of a previous caesarean section
- III. A triangular/round or oval-shaped gestational sac that fills the niche of the scar

- IV. A thin or absent myometrial layer between the gestational sac and the bladder
- V. Yolk sac, embryo and cardiac activity may or may not be present
- VI. Evidence of functional trophoblastic/placental circulation on colour flow Doppler examination, characterised by high velocity and low impedance blood flow
- VII. Negative 'sliding organs' sign. (A positive sliding organ sign occurs when gentle pressure at the level of the internal cervical os displaces the gestational sac).<sup>4</sup>

Different theories explained the mechanism of CSP; the most accepted is that the blastocyst invades into the myometrium through a microscopic dehiscent tract, from previous uterine incision like CS, or uterine injury during manual removal of placenta etc. or trauma done in assisted reproduction techniques.<sup>5</sup>

Two types of CSP are identified. In the first type; sometimes called "endogenic"; the gestational sac implants on the uterine scar, then progresses away from the serosal lining, either towards the cervicoisthmic space or towards the uterine cavity. This may proceed to term pregnancy and a viable birth; however it carries a high risk of life-threatening massive bleeding from a morbidly-adherent placenta with associated perinatal risks of prematurity. The second type - exogenic type - is a deep implantation into a uterine scar which progresses towards the serosal surface. This results in first trimester rupture and bleeding.<sup>4,6</sup>

There are different modalities for management of CSP; however there's no definite consensus on the preferred mode of treatment.<sup>7</sup> Management options include: expectant management, medical treatment with systemic methotrexate, local injection of methotrexate or other embryocides (such as potassium chloride, etoposide and hyperosmolar glucose) with sac aspiration, uterine artery embolization (UAE), and surgical management.<sup>4</sup> Surgical management encompasses different options: dilatation & surgical evacuation, hysteroscopic resection, excision & re-suturing either transvaginally, laparoscopically, or through laparotomy, and finally some cases may opt for hysterectomy. All these procedures may also be done in combination or sequentially.<sup>4</sup>

The choice of treatment modality depends on many variables, and should be individualized for each patient according to a complete pre-treatment assessment. Her wishes for future fertility, the gestational age,  $\beta$ -hCG value, type & size of CSP, and its viability, all affect the decision; putting in mind the patient's symptoms, hemodynamic status, surgical or other risk factors, response to initial treatment and acceptability for prolonged follow-up. Furthermore, available facilities (interventional radiology, surgical expertise/facilities, and monitoring facilities) are important determinants of the treatment options.<sup>4</sup>

Expectant management may be suitable only for few selected cases with small, nonviable, endogenic CSP; provided that the woman is properly counselled about the potential risks, haemorrhage & morbidly adherent placentation, and she declines termination of the pregnancy.<sup>2</sup>

Methotrexate is the drug of choice for medical treatment, more efficiently by local injection.<sup>2,4</sup> This option is suitable for hemodynamically stable cases in pregnancies less than 8 weeks of

gestation with  $\beta$ -hCG level less than 5000 IU/L.<sup>4</sup> The disadvantage of medical treatment is that the trophoblast remains in situ; with risk of haemorrhage as the retained placental tissue degenerates. Also, it requires prolonged follow-up with  $\beta$ -hCG level till complete resolution with its cost implications.<sup>2</sup>

Surgical treatment should be considered for women with significant symptoms or hemodynamic instability, and for those who decline medical management.<sup>4</sup> For endogenous CSP, surgical evacuation or hysteroscopic resection is a suitable option often combined with additional hemostatic measures (cervical cerclage, Foley's catheter insertion, or UAE); whereas surgical resection with re-suturing (with or without uterine artery ligation) should be considered for exogenous CSP with thin myometrium.<sup>2,4</sup> Surgical resection allows for removal of the old scar with the possible benefit of preventing recurrence of CSP. Also, it has shorter follow-up with the rapid resolution of  $\beta$ -hCG levels.<sup>7</sup> In our case, the gestational age (11 weeks), the size and type of the CSP "exogenic", all were in favour for choosing the surgical management as the treatment modality, to minimize the risk of complications.

## Conclusion

Cesarean scar pregnancy is a rare, yet serious, emerging complication of the increasingly rising rates of CS. Diagnosis is facilitated with better imaging facilities, but it needs a high index of suspicion and clinical awareness. Although there's no consensus on the preferred treatment modality for CSP; proper assessment and individualization of treatment is the key for best results with the least risk of complications.

## Authors Contributions

Rania H M Ahmed was the on call doctor who performed the surgery, IHAB.S.ALLAM is the senior surgeon.

Adel Elkady, the corresponding author, helped with literature review and writing the manuscript.

## Conflict of interest

The authors have no conflicts of interest to declare.

## References

1. Petersen KB, Hoffmann E, Ribbjerg Larsen C, et al. Cesarean scar pregnancy: a systematic review of treatment studies. *Fertil Steril*. 2016;105(4):958–967.
2. Elson CJ, Salim R, Potdar N, et al. Diagnosis and management of ectopic pregnancy. *BJOG*. 2016;123:e15–e55.
3. Qian ZD, Weng Y, Du YJ, et al. Management of persistent caesarean scar pregnancy after curettage treatment failure. *BMC Pregnancy Childbirth*. 2017;17(1):208.
4. Jayaram PM, Okunoye GO, Konje J, et al. Cesarean scar ectopic pregnancy: diagnostic challenges and management options. *The Obstetrician & Gynaecologist*. 2017;19:13–20.
5. Deepika, Gupta T, Wahi S. A Rare case report of caesarean scar ectopic pregnancy. *J Clin Diagn Res*. 2017;11(8):QD10–QD11.
6. Aich R, Solanki N, Kakadiya K, et al. Ectopic Pregnancy in caesarean section scar: A case report. *Radiol Case Rep*. 2015;10(4):68–71.
7. Sieczko D, Edwards H, Heggs K, et al. Cesarean scar ectopic pregnancy: a case report. *Ultrasound*. 2014;22(2):126–128.