MedCrave
Step into the World of Research
International Journal of Radiology & Radiation Therapy

Case Report

Mondor's disease: a case report

Abstract

This paper aims to approach an inflammatory pathology of rare presenting and self-limited, but of great relevance in its diagnosis for the following and easing of the patients.

Volume 6 Issue 2 - 2019

Luis Eduardo Almeida de Souza, João Paulo da Silva Machado, Mauro Carvalho Vieira
University UEPA, Brazil

Correspondence: Luis Eduardo Almeida de Souza, University UEPA, Santo Antonio, 25. Belém, Tel 91 9 82897598, Email luisd_souza@hotmail.com

Received: March 06, 2019 | **Published:** March 21, 2019

Introduction

Female 46 years, attends the radiology service referring progressive pain at the left breast, located at the axillar zone and irradiating to the nipple. At the physical examination of this region it was observed the presence of a hard elongated structure with skin retraction. The patient was submitted to a breast ultrasound which demonstrated the findings: image of a tubular aspect in the right breast, dilated, elongated, anechoic, and compatible with venous structure, without Doppler ultrasound flow. Presented in its interior nodular formation, hipoechogenic, without Doppler ultrasound flow, related to mural thrombus. Such findings orientated the diagnosis to Mondor's disease. It was suggested the following of the investigation with magnetic resonance imaging (MRI). The MRI showed the presence of tubular aspect image, dilated, that extended itself from the axillar zone to the nipple of the left breast, observing in its interior filling defect characterized by signal hipodensity in all sequences, compatible with mural thrombus. When contrast was dispensed, it was observed parietal enhance of the vascular structure (Figures 1 & Figure 2). Findings compatible with Mondor's disease.

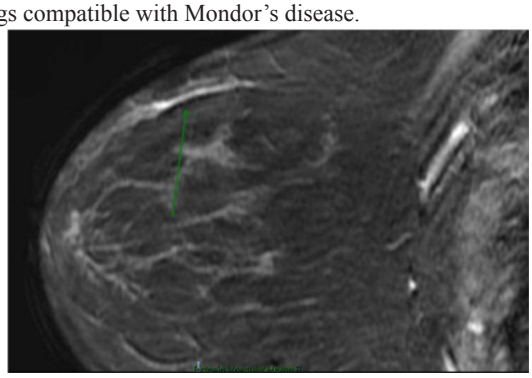

Figure 1 Vascular ectasia.

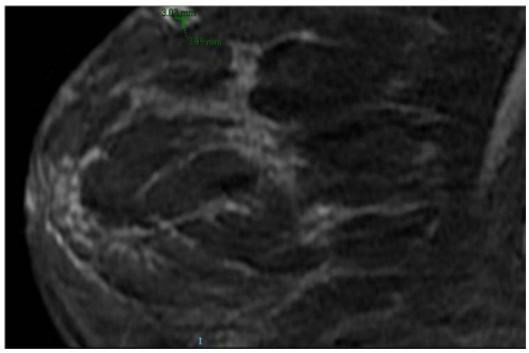

Figure 2 Mural thrombus.

Case report

The description of superficial thorax and abdominal vessels thrombophlebitis was made by Henry Mondor in 1939. Its physiopathology is not yet defined. However, it is known that It has inflammatory and self-limited characteristics and usually affects thoracic-epigastric, lateral-thoracic and superior epigastric veins. It has diverse causes, being related with vessel lesions, blood stasis or hypercoagulability. The main clinical findings are pain and superficial and palpable fibrous cords. Ultrasound and MRI present higher specificity than mammography, even though it is useful to discard occurrence of breast cancer, which can be one of this pathology causes. Mondor's disease symptoms may be treated with anti-inflammatories.[1,2]

Conclusion

Mondor's disease diagnosis is important and necessary to avoid any invasive procedure that may lead to iatrogeny, thus enabling a better patient following.

Acknowledgments

None.

Conflicts of interest

The author declares that there is no conflicts of interest.

References

1. S Lambat Emery, A Kalovidouri, E David-Montefiore. Recurrent Mondor's breast disease–hormonal contraceptive involvement. *Breast Dis*. 2018;30:1–3.
2. Mahesh K Shetty, Alfred B Watson. Mondor's Disease of the Breast. *American Journal of Roentgenology*. 2001;177(4):893–896.