

Therapeutic management of diarrhoea in Indian star tortoises

Abstract

Two Indian star tortoises (*Geochelone elegans*) were referred with a complaint of the passing of watery faeces, reduced feed intake and dullness for the last six days. Another tortoise in the same captive area was reported to be died a few days back showing the similar signs. Microscopic examination of the faecal samples revealed the presence of *Ascarid* type of parasitic ova. They were successfully treated with oral fenbendazole @ 50mg/kg body weight, enrofloxacin @ 5mg/kg body weight along with the multivitamin supplementation. Uneventful recovery was noticed after the third day of therapy.

Keywords: *Geochelone elegans*, Ascarid, diarrhoea, fenbendazole

Volume 3 Issue 3 - 2018

Sivajothi S, Naveen J, Satish Reddy P, Sai Srinivas S, Sudhakara Reddy B

Department of Veterinary Parasitology, Sri Venkateswara Veterinary University, India

Correspondence: Sudhakara Reddy B, Assistant Professor, Faculty of Veterinary Medicine, Department of Veterinary Clinical Complex, College of Veterinary Science, Proddatur - 516360, YSR Kadapa District, Sri Venkateswara Veterinary University, Andhra Pradesh, India, Email bhavanamvet@gmail.com

Received: May 30, 2018 | Published: June 13, 2018

Introduction

Parasites are the organisms which live on or in another organism (host) and utilize the resources of the host for their development and propagation. Most of the gastrointestinal parasites cause severe health issues which result in apathy, diarrhoea, malaise, weight loss and death. Due to unplanned urbanization and excessive deforestation, there is contact between wild animals and humans are increasing. Recent studies finding different parasites in the pet birds and providing the information about the ecology and biodiversity of different parasites.¹ The Indian star tortoise (*Geochelone elegans*) is one of the beautiful land tortoises which originates its name from the radiating star pattern on its shell (Figure 1). It is found in many zoos and is one of the most favorite pet throughout the world. In tortoises, many internal and external parasites are recorded previously and which causes mortality in tortoises.² In the present communication, therapeutic management of diarrhoea due to parasitic infection was reported in Indian star tortoises.

Materials and methods

Approximately two years old two Indian star tortoises (*Geochelone elegans*) were referred with the complaint of the passing of watery faeces, reduced feed intake and dullness for the last six days. Another tortoise in the same captive area was died with the similar complaints. Clinical examination of the tortoises revealed, dullness and passing of watery faeces. Fresh faecal samples were collected from the tortoises (Figure 2) and collected samples were promptly analyzed within 1 hour. Samples were analyzed macroscopically for macro parasites and then microscopically by flotation test. Direct microscopic examination of the faecal samples revealed the presence of *Ascarid* type of parasitic ova (Figure 3). The tortoises were administered with fenbendazole @ 50mg/kg body weight orally for three days, oral enrofloxacin @ 5mg/kg body weight once in a day and daily twice multivitamin drops for seven days.



Figure 1 Indian star tortoise.



Figure 2 Collection of the faecal samples.

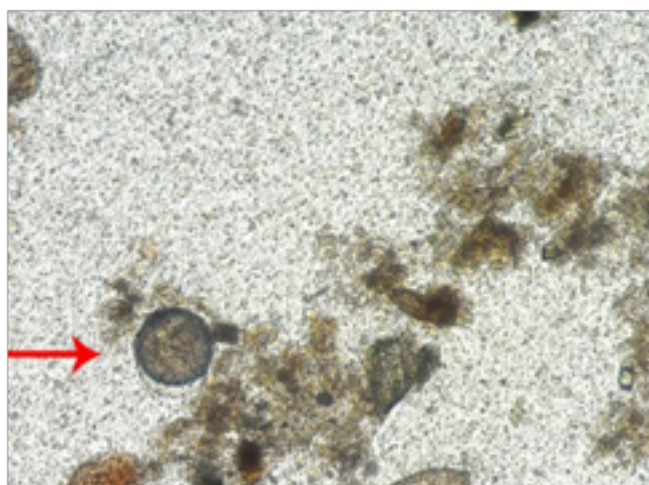


Figure 3 Microscopic examination of the *Ascarid* type of parasitic ova (400x).

Results and discussion

Direct microscopic examination of the faecal sample revealed the presence of *Ascarid* type of ova. Based upon the history and faecal sample examination, it was diagnosed as diarrhoea due to parasitic infection. After the therapy, tortoises were responded well and marked improvement was noticed by the third day of therapy. One more dose of fenbendazole was advised after two weeks of first dose.

Most of the parasites in reptiles found in the blood, body cavities, membranes, lungs and a very vast majority are found in the digestive tract. Nematodes in the Rhabditiidae, Strongylidae, Capillariidae, Heterakidae, Oxyuridae, Spiruridae, Filariidae, Cosmocercidae and Kathlaniidae are found in reptiles.³ Nematodes are one of the most common parasites found in turtles and tortoises. The infection occurs when a healthy turtle ingests the tiny roundworm eggs that have been deposited in the environment through infected turtle's faeces. Turtles and tortoises with a heavy worm load will often have symptoms of weight loss, diarrhoea, and possibly vomiting of a worm. The life cycle of the most of the parasites is direct and the parasite can be transmitted by ingestion of eggs and larvae. Due to close captivity with other turtles or tortoises and unsanitary housing conditions leads to the transmission of the infection to other animals.⁴

In the present study, diagnosis of the parasitic ova according to the morphology of the parasitic ova in the other species of the animals.⁵ Fenbendazole is a member of the benzimidazole group

of anthelmintics. This group of anthelmintics has been widely used in veterinary medicine because of their effect not only on mature worms but also on larval and even on encysted stages. In addition to killing mature worms, the benzimidazoles exert an ovicidal effect, immediately decreasing egg production by effectively sterilizing the worm. Fenbendazole functions by inhibiting the uptake of glucose in the nematode parasite. This block of glucose uptake is slow, so fenbendazole works better when given over a course of several days than in single or multiple doses that are given at spaced time intervals.⁶ Concurrent administration of vitamin supplementation may be essential for clinical recovery. In the present case, a multivitamin preparation was also prescribed for nutritional support.

Conclusion

Therapeutic management of diarrhoea due to *Ascarid* type of parasites in two captive Indian star tortoises were reported.

Acknowledgements

The authors are thankful to the authorities of Sri Venkateswara Veterinary University for providing the facilities to carry out the research work.

Conflict of interest

Author declares that there is no conflict of interest.

References

1. Sivajothi S, Reddy BS. A Study on the Gastro Intestinal Parasites of Domestic Pigeons in YSR Kadapa District in Andhra Pradesh, India. *JDVAR*. 2007;2(6):00057.
2. Vyas R. The Indian star tortoise *Geochelone elegans* status in the protected areas of Gujarat and in Indian zoos. *Zoos Pr J*. 2006;(21):2220–2222.
3. Nathanael S, Samarakoon SMM, Warusamanna ND, et al. Preliminary observations on parasites of captive star tortoises (*Geochelone elegans*) in Sri Lanka. *Testudo*. 2004;(6):24–28.
4. Rataj AV, Knific RL, Vlahovic K, et al. Parasites in pet reptiles. *Acta Vet Scand*. 2011;53(33):1–21.
5. Sivajothi S, Reddy BS. Recurrent gastritis in dogs due to *Toxocara canis* infection in a kennel. *International Journal of Pure and Applied Zoology*. 2018;6(1):7–8.
6. Giannetto S, Brianti E, Poglayen G, et al. Efficacy of oxfendazole and fenbendazole against tortoise (*Testudo hermanni*) oxyurids. *Parasitol Res*. 2007;100(5):1069–1073.