

# Sudden cardiac death: coronary artery spontaneous dissection

## Abstract

Spontaneous coronary artery dissection (SCAD) is a rare pathology that can result in acute coronary syndrome and sudden cardiac death. The actual incidence is thought to be higher as majority of cases is diagnosed at autopsy. In this study, it is aimed to present a case of spontaneous coronary artery dissection that result in sudden death. A 53year old man complaining of headache was brought to emergency department but he was dead on arrival to hospital. Coronary dissection was noticed at right coronary artery and also a hematoma with a false channel lumen at his autopsy. Spontaneous coronary artery dissection, described as the dissection between the layers of media and adventitia in the coronary artery wall, has histopathological characteristics of subadventitial dissection, hematoma formation in the cross-section of the coronary artery. SCAD cases commonly appear as sudden death and 70-75% of these cases are diagnosed in postmortem examinations.

**Keywords:** coronary artery, spontaneous, dissection, sudden death, dead

Volume 6 Issue 1 - 2018

Kenan Kaya,<sup>1</sup> Ziya Eroğlu,<sup>2</sup> Eren Akgündüz,<sup>3</sup>  
Ziyaettin Erdem,<sup>1</sup> Mete Korkut Gülmen<sup>2</sup>

<sup>1</sup>Ministry of Justice, Council of Forensic Medicine, Turkey

<sup>2</sup>Department of Forensic Medicine, Cukurova University School of Medicine, Turkey

<sup>3</sup>Ministry of Justice, Council of Forensic Medicine, Turkey

**Correspondence:** Kenan Kaya, Ministry of Justice, Council of Forensic Medicine, Adana, Turkey,  
Email: k\_kaya\_71@hotmail.com

**Received:** December 19, 2017 | **Published:** February 12, 2018

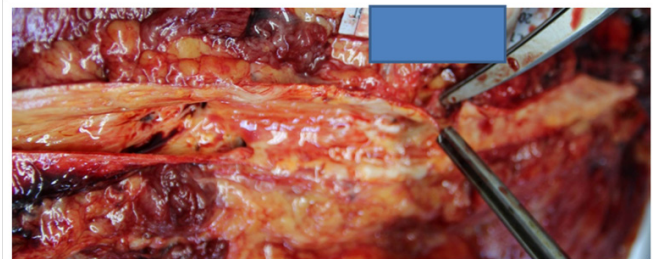
## Introduction

Spontaneous coronary artery dissection (SCAD) is a rare pathology that can result in acute coronary syndrome and sudden cardiac death.<sup>1,2</sup> Many cases have been reported since Pretty described SCAD for the first time in 1931 at the autopsy of a 42year old women who had suffered chest pain.<sup>3</sup> The actual incidence is thought to be higher as majority of cases is diagnosed at autopsy. The causes of SCAD are classified into 3 main subgroups: atherosclerotic disease, peripartum period, and idiopathic. It has been suggested that oral contraceptive use, cocaine use, blunt chest trauma, Marfan syndrome, cystic medial necrosis, hypersensitivity vasculitis and heavy exercise may be associated with SCAD.<sup>4,5</sup> There was no underlying cause in our case and it was evaluated as idiopathic. Patients with SCAD can present with heart attacks, cardiac arrest, or sudden cardiac death. Symptoms of heart attacks in these cases can include chest, shoulder, arm, or epigastric pain, with or without shortness of breath and nausea/vomiting. The heart attack severity can range from mild to severe, which may compromise heart function, causing heart failure, low blood pressure, and other organ dysfunction. During hospitalization, heart enzymes and electrocardiograms often show changes consistent with heart attacks. Some may even have abnormal heart rhythms, causing cardiac arrest that can be lethal. In this study, it is aimed to present a case of spontaneous coronary artery dissection that result in sudden death.

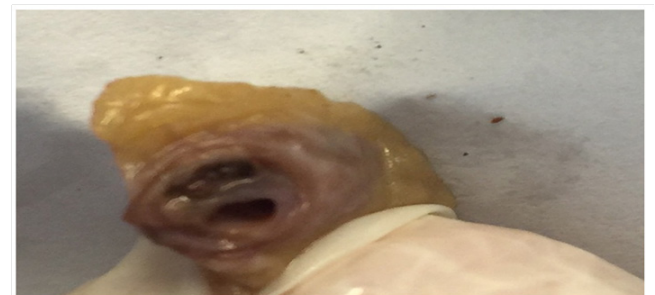
## Case presentation

A 53year old man complaining of headache was brought to emergency department but he was dead on arrival to hospital. The medical history gathered from family members was unremarkable except for a cerebrovascular accident four years ago. The autopsy had held in the Forensic Medicine Council of Adana Branch Morgue Department by two fellow forensic medicine specialists with the evaluation of a forensic pathologist and toxicologist. There were injection marks on left inguinal area and right antecubital fossa. Diffuse atheromatous plaques were seen in the aorta. There were numerous scar areas around the septum of the myocardium. There

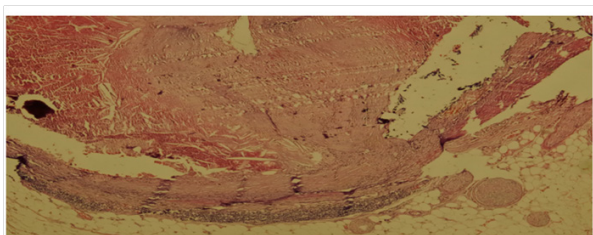
also was 1000 cc blood in the abdominal cavity escaped from the incomplete abdominal aortic rupture in the distal part with a false channel lumen between the intima and the media layer (Figure 1). Coronary dissection was noticed at right coronary artery and also a hematoma with a false channel lumen (Figure 2). Histopathologically, there were subadventitial dissection together with hematoma formation and luminal narrowing on the right coronary artery. The cause of death was given as co-effect of coronary artery dissection and aortic dissection (Figure 3).



**Figure 1** Abdominal aortic rupture in the distal part.



**Figure 2** Coronary dissection was noticed at right coronary artery and also a hematoma with a false channel lumen.



**Figure 3** Subadventitial dissection together with hematoma formation and luminal narrowing on the right coronary artery (HEX100).

## Discussion

SCAD cases commonly appear as sudden death and 70-75% of these cases are diagnosed in postmortem examinations.<sup>6</sup> 75-80% of the cases are females and 1/3 of them develop SCAD within the third trimester and within the first 3 months after delivery.<sup>7</sup> Left anterior descending coronary artery is commonly affected in female patients and right coronary artery is commonly affected in male patients whereas left main coronary artery is the least affected artery in both genders.<sup>8,9</sup> Male gender and the presence of right coronary artery dissection in our case seems to be compatible with previous studies. Spontaneous coronary artery dissection, described as the dissection between the layers of media and adventitia in the coronary artery wall, has histopathological characteristics of subadventitial dissection, hematoma formation in the cross-section of the coronary artery.<sup>10,11</sup> It is of importance to make a diagnosis at the early stage of SCAD to prolong survival. Macroscopic findings of acute coronary artery dissection may be very difficult to detect and it may be easily mistaken with a postmortem clot or thrombi that is overlying on an atheromatous plaque.<sup>12</sup> Detailed evaluation is important for definitive diagnosis in both clinical and postmortem assessment to avoid forensic malpractice allegations. In the future, postmortem diagnosis will be more important within the scope of insurance companies.<sup>13</sup>

## Conclusion

SCAD is uncommon and is an important cause of heart attack. Most coronary dissections will heal spontaneously. Spontaneous coronary artery dissection (SCAD) can slow or block blood flow to the heart, causing a heart attack, abnormalities in heart rhythm or sudden death. At the autopsy of a sudden death case, SCAD should be between the cases keep in mind.

## Acknowledgements

None.

## Conflict of interest

The author declares no conflict of interest.

## References

1. Waller BF. Nonatherosclerotic coronary heart disease. In: Fuster V, et al. editors. 10th ed. *Hurst's the heart*. USA: McGraw Hill; 2001. p. 1162–1168.
2. Vale PR, Baron DW. Coronary artery stenting for spontaneous coronary artery dissection: a case report and review of the literature. *Cathet Cardiovasc Diagn*. 1998;45(3):280–286.
3. Pretty HC. Dissecting aneurysm of coronary artery in a woman aged 42. *Br Med J*. 1931;1:667.
4. DeMaio J, Samuel J, Kinsella SH, et al. Clinical course and long-term prognosis of spontaneous coronary artery dissection. *Am J Cardiol*. 1989;64(8):471–474.
5. Aqel RA, Zoghbi GJ, Iskandrian A. Spontaneous coronary artery dissection, aneurysms, and pseudoaneurysms: a review. *Echocardiography*. 2004;21(2):175–182.
6. Kamran M, Guptan A, Bogal M. Spontaneous coronary artery dissection: case series and review. *J Invasive Cardiol*. 2008;20(10):553–559.
7. Kay IP, Wilkins GT, Williams MJ. Spontaneous coronary artery dissection presenting as unstable angina. *J Invasive Cardiol*. 1998;10(5):274–276.
8. Jorgensen MB, Aharonian V, Mansukhani P, et al. Spontaneous coronary dissection: a cluster of cases with this rare finding. *Am Heart J*. 1994;127(5):1382–1387.
9. Thompson EA, Ferraris S, Gress T, et al. Gender differences and predictors of mortality in spontaneous coronary artery dissection: a review of reported cases. *J Invasive Cardiol*. 2005;17(1):59–61.
10. Corrado D, Thiene G, Cocco P. Non-atherosclerotic coronary artery disease and sudden death in the young. *Br Heart J*. 1992;68:601–607.
11. Robinowitz M, Virmani R, McAllister HA. Spontaneous coronary artery dissection and eosinophilic inflammation: a cause and effect relationship. *Am J Med*. 1982;72:923–928.
12. Yip A, Saw J. Spontaneous coronary artery dissection-A review. *Cardiovasc Diagn Ther*. 2015;5(1):37–48.
13. Ipek Esen Melez, Murat Nihat Arslan, Deniz Og, et al. Spontaneous coronary artery dissection report of 3 cases and literature review hormonal, autoimmune, morphological factors. *Am J Forensic Med Pathol*. 2015;36(3):1–5.