

Post neoadjuvant residual breast tumor size; clinical, radiological and pathological correlation

Abstract

Purpose: The purpose of the current study was to determine the relative accuracies of, sonography, and clinical examination in predicting residual tumour size and pathological response after neoadjuvant chemotherapy breast cancer. Each method was compared with the gold standard of surgical pathology.

Methods: 25 patients (age range, 25-62 years; mean age, 42.7 years) with breast cancer who had been treated by neoadjuvant chemotherapy were taken retrospectively. We compared the predicted residual tumour size and the predicted response on imaging and clinical examination with residual tumour size and response on surgical pathology. Statistical analysis was performed using Spearman Analysis and weighted Kappa values.

Results: The weighted kappa values between pathological assessment and physical examination is 0.457, and 0.384 for sonography. Agreement between the response predictions at mid-treatment and the responses measured by pathology had kappa values of 0.28 for clinical examination, 0.32 for mammography, 0.46 for sonography and 0.68 for MRI. Agreement between the final response predictions and the responses measured by pathology had kappa values of 0.43 for clinical examination, 0.44 for mammography, 0.50 for sonography and 0.82 for MRI.

Conclusion: Post neoadjuvant tumor size estimation of breast tumor by Clinical examination and Radiological modalities correlated on a moderate level with the gold standard pathological tumor size. Compared to radiological, Clinical tumor size estimation correlate better.

Volume 4 Issue 1 - 2017

Madiha Ehsan

Department of histopathology, Fatima memorial Hospital, Pakistan

Correspondence: Madiha Ehsan, Department of histopathology, Fatimah memorial hospital college of medicine and dentistry, Pakistan, Email Madiha_e@hotmail.com

Received: December 05, 2016 | **Published:** January 09, 2017

Introduction

Advantages of neoadjuvant chemotherapy are many and it has been used widely during the past few years.¹ Its primary role is to induce tumour shrinkage and permit breast-conserving surgery, primarily in patients with advanced breast cancer.^{2,3} Neoadjuvant chemotherapy allows earlier treatment of micrometastatic disease and the study of biological markers that might predict tumour response.⁴ The effectiveness of chemotherapeutic agents in treating both primary breast cancer and potential metastatic disease may be enhanced by the presence of tumour neovascularity.

Neoadjuvant chemotherapy has been shown to improve the resectability, offering better disease-free and overall survival rates.^{5,6} Pathological complete response (pCR) has a significance because it is associated with long-term prognosis and decreased risk of recurrences.^{5,7} Decisions regarding the current regimens and the appropriate type and timing of surgical therapy depends on the clinical and radiological assessment of residual tumour size during neoadjuvant chemotherapy.^{8,9} Till date, many studies have shown that physical examination, mammography and sonography are suboptimal for evaluation of lesion extent that do not allow accurate assessments of pathological response or residual tumour size.^{4,10-11} Physical examination, mammography or sonography may be suitable for detecting the larger tumors of non-responders, but they have limited value for responders with smaller residual tumors.^{12,13} We compared clinical examination and ultrasonography prediction methods with the gold standard of surgical pathology.

Material and Method; 25 patients (age range, 25-62 years; mean age, 42.7 years) with breast cancer who had already been treated by neoadjuvant chemotherapy were taken from hospital records. All patients were evaluated by clinical examination, sonography prior to the first course of chemotherapy (baseline assessment), after the fourth course (mid-treatment assessment) and after the last course of chemotherapy (final assessment). After the last course of chemotherapy, study patients underwent mastectomy or breast-conserving surgery according to the standard protocols. All patients underwent ipsilateral axillary node dissection.

All patients underwent clinical examination by one breast surgeon. Clinical response assessment was based on change in the longest diameter of the tumor. The tumour size on sonography was measured in three dimensions by breast radiologist. The pathological response to therapy and the pathological residual tumour size were assessed by gross examination of the excised specimens by the pathologist. Pathological CR (pCR) was defined as the absence of invasive cancer microscopically. We compared predicted residual tumour size and the predicted response on ultrasonography and clinical examination with residual tumour size and response on pathology.

It is a retrospective study, conducted at Fatima memorial Hospital and Ittefaq hospital. The study was completed in 4 months. Data collection and analysis was done. Residual tumor size was measured by Clinical examination (PE) and radiology (US) were recorded from the file. Size correlation was done using Spearman rho analysis (to measure level of association) and Weighted Kappa values were deducted (for reliability) (Figure 1-2).

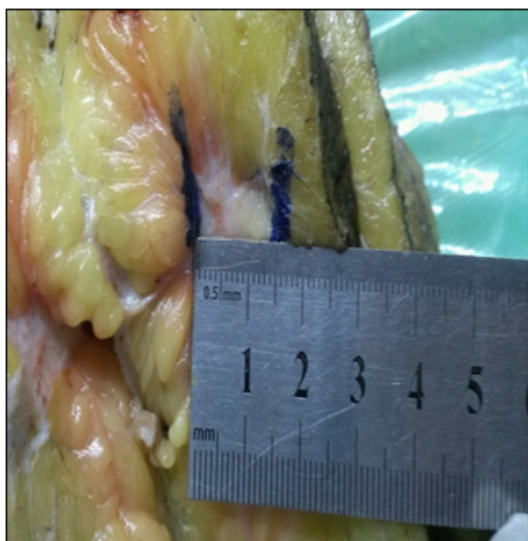


Figure 1 Largest dimension of tumour bed was measured on gross examination.

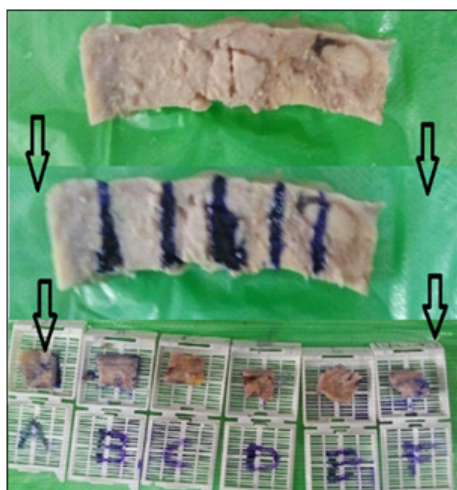


Figure 2 Largest Unidimensional strip section selected sample: labelled and submitted in blocks skip lesions /scattered foci.

Results (Table 1 & Table 2)

Table 1 Correlation of postneoadjuvant residual tumor size

Comparison	Postneoadjuvant chemotherapy
PE vs US	0.633
PE vs Pathology	0.722
US vs Pathology	0.394

Table 2 weighted kappa values

Measurements	Weighted KAPPA
Physical Examination vs pathological measurements	0.457
Ultrasonography measurement vs pathological measurements	0.384

Discussion

These days Neoadjuvant chemotherapy is increasingly used to treat advanced breast cancer, thus allowing more breast-conserving surgery.^{5,14} To identify tumour responses to neoadjuvant chemotherapy a sensitive and specific method is needed in order to recognize non-responders which help an earlier change to a more effective regime. In addition, in cases where there is lack of response to a particular regime. It may guide additional chemotherapy after surgery.

Clinical examination had been found to have a limited value in predicting residual tumour size after neoadjuvant chemotherapy.^{12,15,17,18} Dense breast tissue and the infiltrating nature of the tumor are the factors that make it difficult to evaluate exact tumour size and response after neoadjuvant chemotherapy. Dense breast tissue also obscures the tumour margin thus making size determination difficult. In cases where the whole breast parenchyma is involved on it is difficult to evaluate the exact extent of the residual tumour after neoadjuvant chemotherapy. In our study, the predicted response made at mid-treatment agreed with the pathologically determined response when predictions were based on clinical examination and sonography, respectively. The kappa values for response evaluations based on sonography were lower than that for clinical examination.

In the study of 162patients, Peintinger et al.⁸ showed that a combination of mammography and sonography provided a high accuracy for predicting pCR and a moderate agreement in predicting pathological residual tumour size after neoadjuvant chemotherapy. In our study, pCR and near pCR were accurately predicted by clinical examination in??% of our study patients, by sonography in??%. As regards ability to predict pCR and near pCR, the sensitivity was??% for clinical examination??% for sonography, whereas the specificity was 77% for clinical examination, 100% for sonography. (Can we put percentages?) Or there is no need

Our study says that predictions made on the basis of clinical examination better correlation of pathological residual size after neoadjuvant chemotherapy than estimations made on the basis of sonography. Bonadonna et al.¹ in his study suggested that it is very difficult to interpret the published studies on neoadjuvant chemotherapy because of differences in the assessment of tumour response. Several studies have shown that radiological studies more frequently underestimated than overestimated residual disease.¹⁴

Recent improvements have been achieved by the introduction of newer MRI techniques and more standardized criteria. For example, Wasser et al.¹⁹ and Martincich et al.²⁰ used high temporal resolution dynamic contrast-enhanced MRI. More recently, Kwong et al.⁹ reported that MRI frequently overestimated residual disease in responders to treatment.

There are several limitations to our study. Our study included relatively small numbers of patients and the number of pCR was also small. As a result, our assessments of sensitivity for estimating pCR or near pCR, in particular, are likely to be imprecise. To our knowledge, there have been only a few studies on neoadjuvant chemotherapy. MRI reliability is mentioned in few studies for assessing the size of tumor for post neoadjuvant assessment. May be more studies in this aspect will help in finding more reliable methods.

Conclusion

In patients undergoing neoadjuvant chemotherapy, predictions of treatment response evaluated on the basis of MRI either at mid-treatment or just before surgery and estimates of residual tumour size made on the basis of MRI just before surgery appear to better correlate with pathological results than estimates or predictions based on mammography, sonography or clinical examination. MRI is not, however, perfect. It may overestimate or underestimate residual disease in some patients. Further studies are needed to assess the value of MRI for evaluating the response and thus the efficacy of chemotherapy earlier in a course of neoadjuvant chemotherapy.

Acknowledgements

None.

Conflict of interest

The author declares no conflict of interest.

References

1. Bonadonna G, Valagussa P. Primary chemotherapy in operable breast cancer. *Semin Oncol*. 1996;23:464–474.
2. Newman L, Buzdar A, Singletary S, et al. A prospective trial of preoperative chemotherapy in resectable breast cancer: predictors of breast-conservation therapy feasibility. *Ann Surg Oncol*. 2002;9(3):228–234.
3. Iastos G, Mirza N, Lenert J, et al. The feasibility of minimally invasive surgery for stage IIA, IIB, and IIIA breast carcinoma patients after tumour downstaging with induction chemotherapy. *Cancer*. 2000;88(6):1417–1424.
4. Booser D, Hortobagyi G. Treatment of locally advanced breast cancer. *Semin Oncol*. 1992;19(3):278–285.
5. Fisher B, Bryant J, Wolmark N, et al. Effect of preoperative chemotherapy on the outcome of women with operable breast cancer. *J Clin Oncol*. 1998;16(8):2672–2685.
6. Kaufmann M, von Minckwitz G, Smith R, et al. International expert panel on the use of primary (preoperative) systemic treatment of operable breast cancer: review and recommendations. *J Clin Oncol*. 2003;21(13):2600–2608.
7. Kuerer H, Newman L, Buzdar A, et al. Residual metastatic axillary lymph nodes following neoadjuvant chemotherapy predict disease-free survival in patients with locally advanced breast cancer. *Am J Surg*. 1998;176(6):502–509.
8. Peintinger F, Kuerer H, Anderson K, et al. Accuracy of the combination of mammography and sonography in predicting tumour response in breast cancer patients after neoadjuvant chemotherapy. *Ann Surg Oncol*. 2006;13(11):1443–1449.
9. Kwong M, Chung G, Horvath L, et al. Postchemotherapy MRI overestimates residual disease compared with histopathology in responders to neoadjuvant therapy for locally advanced breast cancer. *Cancer J*. 2006;12(3):212–221.
10. Singletary S, McNeese M, Hortobagyi G. Feasibility of breast-conservation surgery after induction chemotherapy for locally advanced breast carcinoma. *Cancer*. 1992;69(11):2849–2452.
11. Swain S, Sorace R, Bagley C, et al. Neoadjuvant chemotherapy in the combined modality approach of locally advanced nonmetastatic breast cancer. *Cancer Res*. 1987;47(14):3889–3894.
12. Herrada J, Iyer R, Atkinson E, et al. Relative value of physical examination, mammography, and breast sonography in evaluating the size of the primary tumour and regional lymph node metastases in women receiving neoadjuvant chemotherapy for locally advanced breast carcinoma. *Clin Cancer Res*. 1994;3(9):1565–1569.
13. Weatherall P, Evans G, Metzger G, et al. MRI vs. histologic measurement of breast cancer following chemotherapy: comparison with X-ray mammography and palpation. *J Magn Reson Imaging*. 2001;13(6):868–875.
14. Mumtaz H, Davidson T, Hall-Craggs M, et al. Comparison of magnetic resonance imaging and conventional triple assessment in locally recurrent breast cancer. *Br J Surg*. 1997;84(4):1147–1151.
15. Rieber A, Zeitler H, Rosenthal H, et al. MRI of breast cancer: influence of chemotherapy on sensitivity. *Br J Radiol*. 1997;70(833):452–458.
16. Yeh E, Slanetz P, Kopans D, Rafferty E, et al. Prospective comparison of mammography, sonography, and MRI in patients undergoing neoadjuvant chemotherapy for palpable breast cancer. *AJR Am J Roentgenol*. 2005;184(3):868–877.
17. Helvie M, Joynt L, Cody R, et al. Locally advanced breast carcinoma: accuracy of mammography versus clinical examination in the prediction of residual disease after chemotherapy. *Radiology*. 1996;198(2):327–332.
18. Chagpar A, Middleton L, Sahin A, et al. Accuracy of physical examination, ultrasonography, and mammography in predicting residual pathologic tumor size in patients treated with neoadjuvant chemotherapy. *Ann Surg*. 2006;243(2):257–264.
19. Wasser K, Klein S, Fink C, et al. Evaluation of neoadjuvant chemotherapeutic response of breast cancer using dynamic MRI with high temporal resolution. *Eur Radiol*. 2003;13(1):80–87.
20. Martincich L, Montemurro F, De Rosa G, et al. Monitoring response to primary chemotherapy in breast cancer using dynamic contrast-enhanced magnetic resonance imaging. *Breast Cancer Res Treat*. 2004;83(1):67–76.