

Efficacy of platelet rich plasma in treatment of androgenic alopecia

Abstract

Background: Platelet-rich plasma (PRP) has shown remarkable beneficial effects without any major adverse reactions in the treatment of androgenic alopecia. The growth factors in activated autologous PRP induces the proliferation of dermal papilla cells.

Objectives: To investigate the clinical efficacy of Platelet Rich Plasma in treatment of androgenic alopecia.

Methods: Ten patients were given autologous PRP injections on the affected area of alopecia over a period of three months at interval of two - three weeks and results were assessed.

Results: Three months after the treatment, the patients presented clinical improvement in the hair counts, hair thickness, hair root strength and overall alopecia.

Conclusion: PRP appears to be a cheap, effective and promising therapy for androgenic alopecia with no major adverse effects.

Keywords: androgenic alopecia, platelet rich plasma.

Volume 2 Issue 1 - 2016

Dhot PS, Singhal P, Sachin K, Sayal SK, Sehgal R

Lifecell International Pvt Ltd, Manesar, Gurgaon, India

Correspondence: Dhot PS, Singhal P, Lifecell International Pvt Ltd, Manesar, Gurgaon, India, Tel 91-88260 07337/+91-99710 30440, Email drparamjit.p@lifecell.in

Received: April 04, 2015 | **Published:** January 28, 2016

Abbreviations: PRP, platelet-rich plasma; AGA, androgenic alopecia

Introduction

Androgenic alopecia (AGA) is a hereditary, androgen-dependent dermatological disorder more common in men. It is occasionally seen in women. It commonly begins by 20 years of age and affects nearly 50% of men by the age of 50 years.¹ It is a progressive thinning of the scalp hair in a defined pattern causing significant lowering of the self esteem and psychological well being of the patient. An androgen-dependent disorder modulated via the testosterone metabolite dihydrotestosterone and the hair follicle-related androgen receptor, it is a growing concern for the dermatologists around the world. Some genetic factors also have been implicated in its etiology.² The treatment modalities are limited, mainly minoxidil, 5-alpha reductase inhibitors and hair transplantation. These have numerous side effects ranging from hypertrichosis which is excessive hair growth, possible birth defects if given to women of child bearing age, decreased libido and the possibility of prolonged impotence.³

Few treatment options and those too having side effects prompted the discovery of platelet-rich plasma (PRP) which has shown remarkable beneficial effects without any major adverse reactions. PRP represents an autologous concentration of human platelets in a small volume of plasma having 4-7 times the platelet concentration above the normal blood. It is injected subcutaneously into the area of alopecia.⁴ The basic idea behind PRP injection is to deliver high concentrations of growth factors to the scalp, with the hope of stimulating hair regrowth.

Methods

PRP therapy can be given to the males and females in good general health in the age group of 18 to 70 years having mild to moderate AGA

(Ludwig alopecia score I and II, and the Hamilton-Norwood score 1 to 4).⁵ In our study, 8 young male and 2 female patients suffering with alopecia in the age group of 25-35 years were given PRP therapy over a period of three months and their condition was assessed at regular intervals. The scalps were examined to exclude any inflammation, erythema or scarring.

All patients were advised to avoid washing hair two days prior to the treatment. The 'hair pull test' is performed three times by the same clinician wherein a bundle of approximately 50-60 hair is grasped between the thumb, index and middle finger from the base close to the scalp. The hair is firmly tugged away from the scalp, and the extracted hair is counted in every session. To evaluate overall hair growth, hair volume, hair quality and fullness, global pictures are taken in every session from front, vertex, lateral and back view. All patients were advised to avoid any hair products and medicines.

PRP should not be given to patients who received treatments for AGA within the last 3 months, patients who have history of malignancies, platelets disorders, anemia or bleeding disorders, women who are pregnant or breast-feeding, un-cooperative patients or patients who are unable to understand the protocol or give informed consent, patients who are known to be HIV, hepatitis B or C positive or otherwise immunocompromised, subjects who have active skin disease or skin infection at the intended treatment area, patients on non-steroidal anti-inflammatory medications and patients with a propensity for keloids.^{6,7}

Preparation of PRP

Twenty ml of fresh blood is collected from the median cubital vein into sodium citrate vacutainers under aseptic condition. The tubes are rotated in a centrifuge machine at 1500 revolutions per minute for 6 minutes. The first centrifugation called "soft spin" separates the blood into three layers, lowermost RBC layer (55% of total volume),

top most acellular plasma layer called platelet poor plasma (PPP, 40% of total volume) and an intermediate PRP layer (5% of total volume) called the "buffy coat". Buffy coat with PPP is collected with the help of Finn pipette in another test tube. This tube is again centrifuged at 2500 revolution per minute for 15 minutes called "hard spin". This allows the platelets (PRP) to settle at the bottom of the tube. The upper layer containing PPP is discarded and the lower layer of PRP is collected in another clean tube. The platelet concentrate is loaded in 1 mL insulin syringes containing calcium chloride (9 parts of PRP and 1 part calcium chloride) as an activator and made ready for injections into the regions of interest.

Two days prior to the treatment, the patients are advised to wash hair with their regular shampoo followed by disinfecting with chlorhexidine. Area of the scalp is cleansed with spirit and povidone-iodine. With the help of insulin syringe PRP is injected over affected

area by nappage technique (multiple small injections in a linear pattern one-cm apart) under proper aseptic precaution in minor operation theatre. A total volume of 8-12cc is injected. The treatment is repeated every two weeks for four sessions. All the patients are evaluated at one week intervals.

Observations and results

Hair growth was seen in six patients after seven days and in four patients after fifteen days. By the end of three months all ten patients had good hair growth. Three patients complained of mild headache after the initial procedure which was alleviated after paracetamol 500mg. None of the patients had any inflammation or infection. The results of the hair pull test are illustrated in the table showing that the number of hair pulled out has reduced by an average of 65% (Figure 1) (Table1).

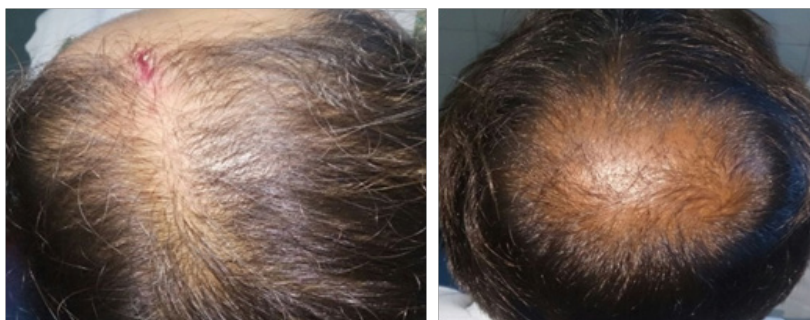


Figure 1 Before.

Table 1 Observations on hair pull test in the ten subjects before and after 12 weeks of PRP therapy

Patient's initials	Age/Sex	Hair pull test (before)	Hair pull test (after 12 weeks)	% reduction in hair pulled	Weeks after which new hair growth was visible
S.K.	26/M	8	1	87.5%	1 week
R.A.	32/F	4	0	100%	1 weeks
PS	35/F	3	0	100%	2 weeks
R.C.	28/M	5	2	60%	2 weeks
A.A.	30/M	7	2	71.4%	1 weeks
R.G.	32/M	2	0	100%	1 weeks
T.K.S	32/M	3	0	100%	1 weeks
R.R.S	31/M	5	0	100%	2 weeks
M.T.	30/M	4	1	75%	1 weeks
K.S.	25/M	3	0	100%	2 weeks

Discussion

While the genetic involvement is pronounced but poorly understood, major advances have been achieved in understanding principal elements of the androgen metabolism involved: androgen-dependent processes are predominantly due to the binding of dihydrotestosterone (DHT) to the androgen receptor (AR).⁸ DHT-dependent cell functions depend on the availability of weak androgens, their conversion to more potent androgens via the action of 5 alpha-reductase, low enzymatic activity of androgen inactivating enzymes, and functionally active AR present in high numbers. The predisposed scalp exhibits high levels of DHT, and increased expression of the AR. Conversion of testosterone to DHT within the dermal papilla plays a central role, while androgen-regulated factors deriving from dermal papilla cells are believed to influence growth of other components of

the hair follicle. Current available treatment modalities with proven efficacy are oral finasteride, a competitive inhibitor of type 2,5 alpha-reductase, and topical minoxidil, an adenosine-triphosphate-sensitive potassium channel opener which has been reported to stimulate the production of vascular endothelial growth factor in cultured dermal papilla cells.⁹ Since the clinical success rate of treatment of AGA with modulators of androgen metabolism or hair growth promoters is limited, sustained microscopic follicular inflammation with connective tissue remodeling, eventually resulting in permanent hair loss, is considered a possible cofactor in the complex etiology of AGA.

Hair follicle has a very complex biologic structure and growth of the hair process is regulated by specific growth cycles. The mature follicle undergoes successive transformation from anagen (active

hair shaft production) to catagen (apoptosis-driven regression) to telogen (resting phase with the involution of hair follicle).^{10,11} Role of apoptosis (by the pathway of caspases cascade) in determining the passage from anagen to catagen is well known. Many growth factors play a fundamental role in the life-long cyclic transformation of the hair follicle functioning as biologic switches that are turned on and off during the different phases, controlling the active phase and promoting apoptosis to induce catagen and telogen.^{4,12} The main growth factors involved in the establishment of hair follicle are vascular endothelial

growth factor (VEGF), epidermal growth factor (EGF), insulin 1-like growth factor, and fibroblast growth factor (FGF). Platelets release large amounts of platelet-derived growth factor (PDGF α , PDGF β , and PDGF γ), transforming growth factor beta (TGF β_1 and β_2), EGF, and VEGF^{8,10} (Figure 2) (Table 2). The beneficial effects of PRP in AGA thus can be attributed to various platelet-derived growth factors causing improvement in the function of hair follicle and promotion of hair growth. It is safe, cheap, and non-allergic and it appears to be a useful adjuvant in the management of AGA.

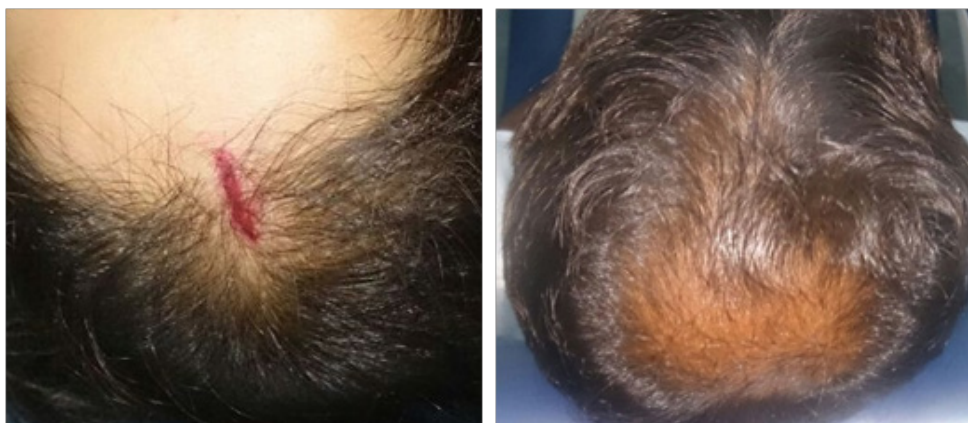

Figure 2 After 3 months.

Table 2 Growth factors in platelets and their functions

Growth factor	Primary functions
Epidermal growth factor	Regulation of cell proliferation, differentiation, and survival.
Insulin-like growth factor	Key regulator of cell metabolism and growth Stimulates proliferation and differentiation functions in osteoblasts.
Platelet-derived growth factor	Major mitogen for connective tissue cells and certain other cell types. Promotes the synthesis of collagen and structural proteins.
Transforming growth factor (i.e., alpha, beta)	Regulation of cell proliferation, differentiation, and apoptosis Induction of intimal thickening.
Vascular endothelial growth factor	Regulation of angiogenesis

Uebel et al.¹³ observed a significant improvement in hair density and stimulation of growth when follicular units were pre-treated with platelet plasma growth factors before their implantation. There was a significant difference in the yield of follicular units on comparing the experimental with the control areas of the scalp. The areas treated with platelet plasma growth factors demonstrated a yield of 18.7 follicular units per cm² whereas the control areas yielded 16.4 follicular units per cm², an increase in follicular density of 15.1 percent.

The ever increasing literature has also seen modifications of PRP to increase its therapeutic results. Takikawa et al.,¹⁴ investigated a low-molecular weight heparin, as a carrier for PRP. Dalteparin/protamine (DP), in water soluble micro particles, acts as a biomaterial to adsorb, stabilize and gradually release the GFs in PRP, as almost all of them are known to be heparin binding. Results showed that DP in PRP could further improve the hair thickness as compared to PRP alone without any side effects, although effect of DP alone was not assessed as control.

Conclusion

PRP injection for androgenic alopecia is a simple, cost-effective and feasible treatment option for hair loss and can be regarded as

a valuable adjuvant treatment modality for androgenic alopecia. Although PRP has sufficient theoretical scientific basis to support its use in hair restoration, hair restoration using PRP is still at its infancy. Clinical evidence is still weak. Considering its excellent safety profile and relatively low cost, PRP hair treatment is a promising treatment option for patients with thinning hair. Although experience and anecdotal clinical data are important, we still need randomized, placebo-controlled, clinical trials to be certain that PRP does in fact induce hair growth.

Acknowledgements

None.

Conflict of interest

The author declares no conflict of interest.

References

1. Trink A, Sorbellini E, Bezzola P, et al. A randomized, double-blind, placebo and active-controlled, half-head study to evaluate the effects of platelet rich plasma on alopecia areata. *Br J Dermatol*. 2013;169(3):690–694.

2. Rallis E, Falidas E, Villias C. Amyopathic dermatomyositis-associated bilateral elbow ulcers successfully treated with autologous platelet-rich plasma. *Int J Dermatol*. 2014;53(1):e50–e52.
3. Kang BK, Lee JH, Shin MK, et al. Infraorbital rejuvenation using PRP (platelet-rich plasma): A prospective, randomized, split-face trial. *J Am Acad Dermatol*. 2013;68:SAB24.
4. Park KY, Kim IS, Kim BJ, et al. Letter: Autologous fat grafting and platelet-rich plasma for treatment of facial contour defects. *Dermatol Surg*. 2012;38(9):1572–1574.
5. Li ZJ, Choi HI, Choi DK, et al. Autologous platelet-rich plasma: A potential therapeutic tool for promoting hair growth. *Dermatol Surg*. 2012;38(7 pt 1):1040–1046.
6. Rinaldi F, Sorbellini E, Coscera T. The role of platelet rich plasma to control anagen phase: Evaluation *in-vitro* and *in-vivo* in hair transplant and hair treatment. *Int J Trichol*. 2011;3:S14–S15.
7. Lopez V, Vaya A, Bautista D, et al. Autologous platelet-rich plasma as a potential therapeutic tool in androgenetic alopecia. *J Am Acad Dermatol*. 2013;68:SAB103.
8. Dohan Ehrenfest DM, Rasmusson L, Albrektsson T. Classification of platelet concentrates: from pure platelet-rich plasma (P-PRP) to leucocyte- and platelet-rich fibrin (L-PRF). *Trends Biotechnol*. 2009;27(3):158–167.
9. Giusti I, Rughetti A, D'Ascenzo S, et al. Identification of an optimal concentration of platelet gel for promoting angiogenesis in human endothelial cells. *Transfusion*. 2009;49(4):771–778.
10. Cho JW, Kim SA, Lee KS. Platelet-rich plasma induces increased expression of G1 cell cycle regulators, type I collagen, and matrix metalloproteinase-1 in human skin fibroblasts. *Int J Mol Med*. 2012;29(1):32–36.
11. Kurita M, Aiba-Kojima E, Shigeura T, et al. Differential effects of three preparations of human serum on expansion of various types of human cells. *Plast Reconstr Surg*. 2008;122(2):438–448.
12. Krasna M, Domanoviae D, Tomsic A, et al. Platelet gel stimulates proliferation of human dermal fibroblasts *in-vitro*. *Acta Dermatovenerol Alp Panon Adriat*. 2007;16(7):105–110.
13. Uebel CO, da Silva JB, Cantarelli D, et al. The role of platelet plasma growth factors in male pattern baldness surgery. *Plast Reconstr Surg*. 2006;118(6):1458–1466.
14. Megumi Takikawa, Shinichiro Nakamura, Shingo Nakamura. Enhanced effect of Platelet-rich plasma containing a new carrier on hair growth. *Dermatol Surg*. 2011;37(12):1721–1729.