

# Endoscopic management of biliary cast syndrome post hepatic trauma

## Abstract

Biliary cast syndrome is a rare disorder that is characterized by the presence of casts in the biliary ducts, causing obstruction leading to infection and hepatic and ductal damage. The syndrome is more commonly reported in liver transplant patients, being very unusual in other situations. We report a case in a patient that suffered a severe hepatic trauma that was successfully managed by endoscopic therapy.

Volume 8 Issue 2 - 2017

López-Rosés L, González-Ramírez A, Lancho A, Santos E, Alvarez B, Dacal A, Martí E, Castro E, González Soler R

Servicio de Aparato Digestivo, Hospital Universitario Lucus Augusti, Spain

**Correspondence:** López-Rosés L, Servicio de Aparato Digestivo, Hospital Universitario Lucus Augusti, Spain, Email lelopezroses@gmail.com

**Received:** July 29, 2017 | **Published:** December 12, 2017

## Introduction

The biliary cast syndrome is a rare phenomenon that develops due to precipitation of amorphous material in the bile ducts, forming casts that lead to obstruction with consequent infection and damage to liver parenchyma and duct. The syndrome has been described almost exclusively in liver transplant patients, more often during the first years of orthotopic liver transplant, when graft preservation techniques were less advanced.<sup>1-3</sup> Nowadays, the prevalence of bile duct filling defects due to sludge or casts is reported to be around 3%.<sup>4</sup> The casts can develop at any level of the biliary tree, either intra, extrahepatic or both. The exact pathogenesis of biliary casts is not well known but many factors have been suggested as playing an aetiological role in their formation. Probably the most important one is ischemia but many others can intervene, such as infection, ductal lesions, fasting, cyclosporine and in general any other factor that promotes increase in biliary viscosity and/ or hinders the flow of bile.<sup>5-8</sup> The treatment of this disorder can be endoscopic, through ERCP, with sphincterotomy and removal of the casts<sup>9</sup> but in many cases it is necessary to proceed to a surgical cleaning of the biliary tree.<sup>10</sup> Here we describe a case in a non-transplant patient that we resolved with endoscopic approach.

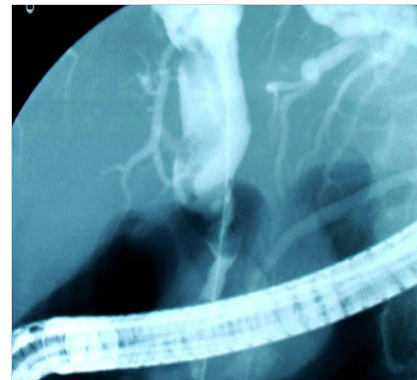## Case report

A previously healthy 76-year-old man suffered a traffic accident. He was in hemorrhagic shock and at laparotomy a hepatic rupture was diagnosed. This was surgically treated by “packing”, ligation of the right hepatic artery and cholecystectomy. The patient’s condition improved and he was discharged after few weeks, in a good condition and with liver function tests in normal range, except gammaglutamyl transpeptidase (GGT), that was 112 UI/l (normal values between 0-73).

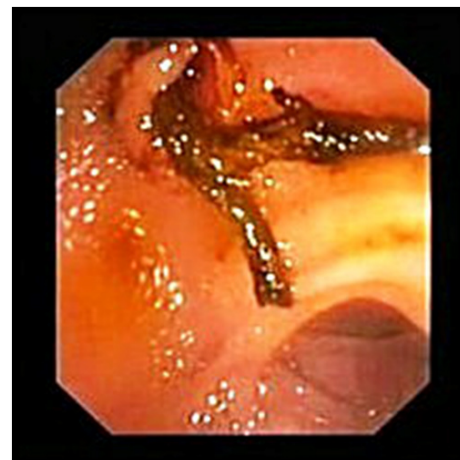
Three months later, he was admitted again due to an episode of acute cholangitis. Serum bilirubin was 5.3mg/dl (Normal range 0.3-1.3), alkaline phosphatase 193 (46-116), GGT 345 UI/l, AST 120 UI/l (0-34), ALT 154 (10-49). A transabdominal ultrasonography showed biliary duct dilation with echogenic material inside. The patient was referred to our department and an ERCP was performed.

The Papilla of Vater was normal. There was dilation of the common hepatic duct and a large filling defect was noted which extended from the right and left hepatic ducts confluence to the common bile duct

(Figure 1). After performing a sphincterotomy and using a Dormia basket, a Y shaped cast, reproducing the hepatic ducts confluence, some secondary ducts and the whole main bile duct, was removed (Figure 2). The final patency of the biliary tree was confirmed by passing a balloon (Figure 3). The microscopic analysis of the cast showed that it was composed of amorphous biliary material, without cellular rests.



**Figure 1** Dilatation of the common hepatic duct.



**Figure 2** Appearance of Y shaped cast.

The outcome was favourable and after ten months of follow up, the patient remained asymptomatic and with liver function test within normal range.

## Discussion

The formation of casts of the bile ducts (biliary cast syndrome) is caused by mechanisms not clearly understood, that involve factors such as ischemia, infection, hemolysis and liver surgery among others. These casts are made up primarily of calcium bilirrubinate, cholesterol crystals and mucus.<sup>5</sup> Recently, by using scanning electron microscopy and hematoxylin and eosin staining, studies showed that cast also contains blood vessels and collagen fibers.<sup>11,12</sup> From a theoretical standpoint, any situation that increases the viscosity of bile or decreases bile flow, may lead to the formation of casts. The vast majority of cases reported occurred in liver transplant patients, especially during the first few years of application of the technique, where graft preservation methods were less sophisticated than today. Some studies have linked the formation of the casts with the existence of faulty reconstructions of the biliary tract, which would cause injury to the biliary epithelium and trigger the precipitation of material in it. This in combination with infection and a cholesterol-saturated bile, play a role in the formation of casts after transplantation.<sup>7</sup> Moreover, the presence of ischemia is believed to be one of the main triggers of this syndrome, because it has been shown that the presence of casts after liver transplantation was accompanied by hepatic artery occlusion in 30% of cases.<sup>4</sup> Also, some drugs used post transplant, such as cyclosporine, may contribute to the emergence of casts, by inhibiting the secretion of bile, causing a functional bile stasis.<sup>8</sup> Furthermore, the presence of foreign bodies such as T tubes or prosthesis may act as a nidus for formation of stones or sludge.<sup>13</sup> Systemic bacterial or fungal infection, which causes intrahepatic cholestasis may also be a predisposing factor to the formation of casts in the bile ducts after liver transplantation.<sup>14</sup> Finally, many others have been associated as risk factors for the formation of biliary casts, such as, hepatic artery stenosis or thrombosis, biliary strictures, renal replacement therapy, ischemia-reperfusion injury, prolonged cold preservation, prolonged warm ischemia, hemolysis, pregnancy or AIDS virus infection.<sup>15–18</sup>

Casts can also occur in non-transplant patients, although that is extremely unusual; only a few cases have been published to date. Table 1 summarizes the different scenarios in which the biliary cast syndrome has been described.<sup>19–26</sup> Initial treatment of the syndrome should be endoscopic biliary sphincterotomy and cast extraction. In cases where it is not possible to completely remove the casts, nasobiliary drainage placement has been proposed to clean up bile ducts.<sup>3</sup> Also, ursodeoxycholic acid has been used as complementary treatment in difficult or recurrent cases.<sup>22,23,26</sup> Surgical treatment should be reserved for those cases in which endoscopic manoeuvres have failed. With regard to outcome, Zhu et al studied 103 biliary cast syndrome patients who underwent liver transplant. They found a total cure rate and total cure rate of 54% and 71% total improve rate (18). Interestingly, the relapsing rate was as high as 55% after endoscopic treatment<sup>27</sup> Mortality was 13.6%.

Our case is the first biliary cast syndrome reported after a traumatic hepatic rupture. It appeared in a non-transplant patient who had suffered severe liver injury that required right hepatic artery ligation due to hypovolemic shock. Both circumstances appear to reinforce the notion that ischemia plays an essential role as an aetiological factor in the development of this syndrome. From a clinical point of view, it is important to note that symptoms were developed three months after the initial event, and that the ERCP clearly diagnosed the cause. The

endoscopic resolution, particularly easy in this case, also reinforces the role of the endoscopic treatment of this syndrome as a first step in its management.

**Table 1** Non-transplant patient situations in which biliary cast syndrome has been described

Prolonged intensive care unit stay
Gangrenous cholecystitis in diabetic patient.
Stasis of bile flow and / or gallbladder hypocontractility.
Antiphospholipid syndrome
Hepatic infarction
Portal hypertensive biliopathy
Allogenic hematopoietic stem cell transplantation
Cholangitis plus pancreatitis
Opium inhalation.

## Disclosure

All authors disclosed no financial relationships relevant to this publication.

## Acknowledgements

None.

## Conflicts of Interest

None.

## Funding

None.

## References

1. Starzl TE, Putnam CW, Hansbrough JF, et al. Biliary complications after liver transplantation: with special reference to the biliary cast syndrome and techniques of secondary duct repair. *Surgery*. 1977;81(2):212–221.
2. Chen CL, Wang KL, Chuang JH, et al. Biliary sludge-cast formation following liver transplantation. *Hepatogastroenterology*. 1988;35(1):22–24.
3. Tung BY, Kimmey MB. Biliary complications of orthotopic liver transplantation. *Dig Dis*. 1999;17(3):133–144.
4. Sheng R, Ramirez CB, Zajko AB, et al. Biliary stones and sludge in liver transplant patients: a 13 years experience. *Radiology*. 1996;198(1):243–247.
5. Lee SP, Maher K, Nicholls JF. Origin and fate of biliary sludge. *Gastroenterology*. 1988;94(1):170–176.
6. Waldram R, Williams R, Calne RY. Bile composition and bile cast formation after transplantation of the liver in man. *Transplantation*. 1975;19(5):382–387.
7. Otto G, Roeren T, Golling M, et al. Ischemic type lesions of the bile ducts after liver transplantation: 2 years results. *Zentralbl Chir*. 1985;120(6):450–454.
8. Le Thai B, Dumont M, Michel A, et al. Cholestatic effect of ciclosporin in the rat. An inhibition of bile acid secretion. *Transplantation*. 1988;46(4):510–512.
9. Pfau PR, Kochman ML, Lewis JD, et al. Endoscopic management of postoperative biliary complications in orthotopic liver transplantation. *Gastrointest Endosc*. 2000;52(1):55–63.

10. Canete JJ, Aidlen JT, Uknis ME, et al. Images of interest. Hepatobiliary and pancreatic: biliary cast syndrome. *J Gastroenterol Hepatol.* 2005;20(5):791.
11. Yang YL, Zhang C, Lin MJ, et al. Biliary casts after liver transplantation: Morphology and biochemical analysis. *World J Gastroenterol.* 2013;19(43):7772–7777.
12. Tian H, Liao QD, Li NF, et al. Biliary cast syndrome: Hepatic artery resistance index, pathological changes, morphology and endoscopic therapy. *Chin Med J.* 2015;128(14):1910–1915.
13. Leung JW, Liu YL, Chan RC, et al. Effects of adherence factors and human bile on bacterial attachment and biliary stent blockage: an in vitro study. *Gastrointest Endosc.* 2002;56(1):72–77.
14. Parry SD, Muiesan P. Cholangiopathy and the biliary cast syndrome. *Eur J Gastroenterol Hepatol.* 2003;15(4):341–343.
15. Maringhini A, Ciambra M, Baccelliere P, et al. Biliary sludge and gallstones in pregnancy: incidence, risks factors and natural history. *Ann Intern Med.* 1993;119(2):116–120.
16. Grumbach K, Coleman BG, Ga AA, et al. Hepatic and biliary tract abnormalities in patients with AIDS. Sonographic-pathologic correlation. *J Ultrasound Med.* 1989;8(5):247–254.
17. Voigtländer T, Negm AA, Strassburg CP, et al. Biliary cast syndrome post-liver transplantation: risk factors and outcome. *Liver Int.* 2013;33(8):1287–1292.
18. Zhu XD, Shen ZY, Chen XG, et al. Pathotyping and clinical manifestations of biliary cast syndrome in patients after an orthotopic liver transplant. *Exp Clin Transplant.* 2013;11(2):142–149.
19. D’Haens GR, Ruchim MA, Goldberg MJ, et al. Massive intra-hepatic and extra-hepatic bile cast formation after cholecystectomy. *Gastrointest Endosc.* 1993;39(4):579–581.
20. Byrne MF, Chong HI, O’Donovan D, et al. Idiopathic cholangiopathy in a biliary cast syndrome necessitating liver transplantation following head trauma. *Eur J Gastroenterol Hepatol.* 2003;15(4):415–417.
21. Gleeson FC, Czaja AJ, Baron TH. Successful endoscopic management of biliary cast syndrome in non-liver transplant patients. *J Clin Gastroenterol.* 2008;42(6):752–755.
22. Katsinelos P, Kountouras J, Chatzimavroudis G, et al. Combined endoscopic and ursodeoxycholic acid treatment of biliary cast syndrome in a non-transplant patient. *World J Gastroenterol.* 2008;14(33):5223–5225.
23. Graur F, Neagos H, Cavasi A, et al. Biliary cast—complication of colangitis and pancreatitis in a pancreas divisum patient. *Chirurgia.* 2014;109(5):685–688.
24. Hosoi M, Nannya Y, Sasaki T, et al. Biliary cast syndrome and benign biliary stricture as complications of allogenic hematopoietic stem cell transplantation. *Ann Hematol.* 2010;89(12):1287–1289.
25. D’Assuncao MA, Velázquez-Aviña J, Council L, et al. Biliary cast syndrome in portal hypertensive biliopathy: direct cholangioscopic findings and endoscopic therapy with metal stent. *Endosc Int Open.* 2015;3(3):E223–E225.
26. Dabiri R, Aghdae HA, Rajabalinia H, et al. Biliary cast syndrome in an opium inhaler. *Case Rep Gastroenterol.* 2013;7(3):376–380.
27. Paik WH, Lee SH, Ryu JK, et al. Long term clinical outcomes of biliary cast syndrome in liver transplant recipients. *Liver Transpl.* 2013;19(3):275–282.