

Broken heart syndrome (takotsubo cardiomyopathy) triggered by orthotopic liver transplantation

Keywords: takotsubo cardiomyopathy, broken heart syndrome, stress cardiomyopathy, left ventricular apical ballooning syndrome, liver transplant, post liver transplant cardiomyopathy, postoperative cardiomyopathy

Introduction

After orthotopic liver transplant OLT, cardiac complications are a common cause of morbidity and mortality. Therefore, patients undergo extensive cardiac workup prior to OLT¹ to reduce the risk for those complications. Takotsubo cardiomyopathy is a special form of cardiomyopathy which is also known as Broken Heart Syndrome, Stress Cardiomyopathy and Transient Apical Ballooning Syndrome. It is described by transient left ventricular dysfunction in the absence of coronary artery disease where the heart will take the shape of a Japanese Octopus fish trap called Tako-tsubo.^{2,3} Wall motion abnormality of the Left ventricle apex is generally transient and resolves within few days to several weeks.⁴ This condition is unique in that it is often triggered by physical or emotional stressors including acute medical illness, sudden death of a loved one and perioperative risk while undergoing noncardiac surgery.^{5,6} This cardiomyopathy is commonly seen in postmenopausal female patients⁷ but it has been reported in male patients as well.⁸ Clinical presentation may vary but typically resemble acute coronary syndrome with chest pain and exertional shortness of breath being the most reported symptoms.² These patients can also present with cardiogenic shock and arrhythmia.

Upon extensive review of literature, Takotsubo cardiomyopathy post orthotopic liver transplant has been reported in only few cases. Herein we present a case of Takotsubo cardiomyopathy post orthotopic liver transplantation. In our case, we aim to illustrate the importance of early recognition of this condition since stress induced cardiomyopathy is an underestimated cause of cardiac complications in liver transplant patients. To optimize patient outcome and decrease overall morbidity and mortality early diagnosis and prompt treatment is required.

Case report

A 52-year-old Asian woman with end-stage liver disease (ESLD) due to Hepatitis B and C complicated by ascites had undergone an orthotopic liver transplant in summer 2016. Her MELD (Model for End-Stage Liver Disease) score was 25 at the time of liver transplant. Pre-transplant Echocardiogram showed normal left ventricular Ejection Fraction EF of 60-65% with evidence of hepato-pulmonary shunt. Nuclear stress test showed an EF of 73% and study was inconclusive, subsequently, she underwent coronary angiography which showed normal coronaries without any evidence of obstruction. On 2nd day post-surgery, she developed shortness of breath, chest pain, and hypoxemia. She had new onset of S3 heart sound and lower extremity edema. She was intubated and central line and Swan-Ganz catheters were placed. She was started on intravenous diuretics and pressors combination with Epinephrine and Dobutamine. Swan-Ganz catheter noted severely elevated right-sided pressures. Echocardiogram showed systolic dysfunction of the left ventricle with

Volume 6 Issue 5 - 2017

Dhuha Alhankawi,¹ Prasun Shah,² Elijah Min,³ William Cole,⁴ Bonnie onze,³ Glyn Morgan,³ Bruce Gelb,³ Nabil Dagher,³ James Park I,³

¹Department of Medicine, NYU Langone Medical Center, USA

²Department of Medicine, Maimonides Medical Center, USA

³Transplantation Institute, NYU Langone Medical Center, USA

⁴Department of Medicine, Division of Cardiology, New York University, USA

Correspondence: Dhuha Alhankawi, Department of Medicine, NYU Langone Medical Center, USA, Email dhuha.alhankawi@nyumc.org

Received: February 06, 2017 | **Published:** April 20, 2017

EF of 10%, severely hypokinetic left ventricle with apical ballooning. The right ventricle was dilated. EKG showed normal sinus rhythm with low voltage unchanged from prior EKG. Lab results were consistent with shocked liver and elevated liver enzymes, lactic acid, and acidic PH. Coronary angiogram was not performed due to renal insufficiency which later improved without dialysis. With clinical improvement, her repeat Echocardiogram showed a remarkable improvement in EF to 50% which was consistent with our diagnosis of stress cardiomyopathy. She remained clinically stable and she was discharged in a stable condition without further complications. On follow up she was found clinically stable with good graft function (Figure 1).

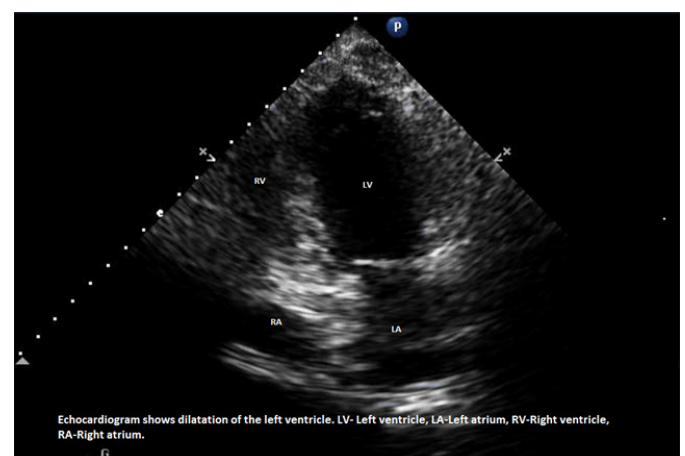


Figure 1 Echocardiogram.

Discussion

Takotsubo cardiomyopathy was first described in 1990's by Sato et al.⁹ Although it has been over 26 years since then but this syndrome remains poorly understood^{9,10} and underlying mechanism for Takotsubo cardiomyopathy remains unclear.¹¹ Many theories have been proposed including impaired myocardial perfusion, injury of cardiac myocyte as well as metabolic dysfunction during physical or emotional stressors but the most widely accepted theory is thought to be due to catecholamine surplus.¹² High risk is related to underlying comorbidities and has been associated with male gender.¹³

Although Takotsubo cardiomyopathy is a rare complication post liver transplant, yet it can be life threatening.¹⁴ Early recognition of this condition is crucial for better outcome and prevention of potential complication.⁵ In our patient, early recognition of takotsubo's cardiomyopathy led to prompt treatment with rapid improvement in her clinical status and eventually normalization of her cardiac function.

As described by Raval et al.¹⁵ cardiovascular response in ESLD is usually compromised. These patients frequently have an increase in cardiac output with a suboptimal ventricular response to stressor like liver transplant. This is named Cirrhotic cardiomyopathy which is mediated by multiple mechanisms, like beta agonist transduction, increase in the circulatory inflammatory mediators with cardio depressant properties and repolarization changes. Hemodynamic stressors associated with liver transplant increase their risk for cardiovascular complication.¹⁵ Strategies for managing this condition post liver transplant are not clear, however most of the reported cases like our patient responded well to Intravenous diuretics and vasopressor support.¹⁶ If these strategies fail, then percutaneous devices for hemodynamic support should be considered.⁸ Intraaortic balloon pumps can be used in an acute setting for hypotensive crises and cardiogenic shock to achieve hemodynamic support.^{2,16,17} In case of refractory heart failure, LVAD implantation has been used successfully in one case report.⁸ Mayo clinic assessed 1460 liver transplant patient. 17 of those patients were found to have non-ischemic cardiomyopathy. 76% of the patients with stress cardiomyopathy were found to have renal insufficiency. Most of the patient developed cardiomyopathy around day 2 post transplant. Median MELD score was 29 upon time of liver transplant. 16 patients out of 17 had a recovery of cardiac function with median of EF of 44%. This study showed over 94% 1 year survival.¹⁸ Most reported cases are on post op Day 0-Day 20 with most common on Post op day.^{2,16,18} In addition to the physical and perioperative risk associated with liver transplantation, we should be attentive to the emotional stress involved in the process of OLT evaluation as patients realize that their own survival is contingent on receiving a donated liver from another person which can be overwhelming. All of these factors may increase the risk to develop Takotsubo cardiomyopathy and therefore it should be considered as one of the differential diagnosis of acute cardiopulmonary failure post liver transplant. Early diagnosis is crucial as it can alleviate the patient's symptoms, decrease overall morbidity and mortality.

Conclusion

Our case represents a rare condition of stress cardiomyopathy post orthotopic liver transplant. It also reiterates the importance of early identification and prompt treatment of condition which if done properly, has a favorable outcome.

References

1. Tachotti Pires LJ, Cardoso Curiali MN, Vissoci Reiche F, et al. Stress-induced cardiomyopathy (takotsubo cardiomyopathy) after liver transplantation: report of two cases. *Transplant Proc.* 2012;44(8):2497–2500.
2. Bedanova H, Orban M, Nemeš P. Postoperative left ventricular apical ballooning: Transient Takotsubo cardiomyopathy following orthotopic liver transplantation. *Am J Case Rep.* 2013;14:494–497.
3. Akashi YJ, Goldstein DS, Barbaro G, et al. Takotsubo cardiomyopathy: a new form of acute, reversible heart failure. *Circulation.* 2008;118(25):2754–2762.
4. Komamura K, Fukui M, Iwasaku T, et al. Takotsubo cardiomyopathy: Pathophysiology, diagnosis and treatment. *World J Cardiol.* 2014;6(7):602–609.
5. Littlejohn FC, Syed O, Ornstein E, et al. Takotsubo cardiomyopathy associated with anesthesia: three case reports. *Cases J.* 2008;1(1):1–227.
6. Sharkey SW, Lesser JR, Zenovich AG, et al. Acute and reversible cardiomyopathy provoked by stress in women from the United States. *Circulation.* 2005;111(4):472–479.
7. Gulsin G, Serna S, Morris C, et al. Takotsubo cardiomyopathy with left ventricular thrombus presenting as critical limb ischaemia. *Oxf Med Case Reports.* 2006;(8):omw051.
8. Vachiat A, McCutcheon K, Mahomed A, et al. Takotsubo cardiomyopathy post liver transplantation. *Cardiovasc J Afr.* 2016;27(5):e1–e3.
9. Sato H, Tateishi H, Uchida T. Tako-tsubo-like left ventricular dysfunction due to multivessel coronary spasm. *Clinical Aspect of Myocardial Injury: From Ischemia to Heart Failure.* Kodama K, et al. (Eds.), Kagakuhyoronsha Publishing Co, Japan, 2006. p. 56–64.
10. Zalewska-Adamiec M, Bachorzewska-Gajewska H, Tomaszuk-Kazberuk A, et al. Takotsubocardiomyopathy: serious early complications and two-year mortality a 101 case study. *Neth Heart J.* 2016;24(9):511–519.
11. Ramaraj R. Stress cardiomyopathy: aetiology and management. *Postgrad Med J.* 2007;83(982):543–546.
12. Wittstein IS, Thiemann DR, Lima JA, et al. Neurohumoral features of myocardial stunning due to sudden emotional stress. *N Engl J Med.* 2005;352(6):539–548.
13. Mejia-Renteraa HD, Nunez-Gil IJ. Takotsubo syndrome: Advances in the understanding and management of an enigmatic stress cardiomyopathy. *World J Cardiol.* 2016;8(7):413–424.
14. Sharkey SW, Windenburg DC, Lesser JR, et al. Natural history and expansive clinical profile of stress (tako-tsubo) cardiomyopathy. *J Am Coll Cardiol.* 2010;55(4):333–341.
15. Raval Z, Harinstein ME, Skaro AI, et al. Cardiovascular risk assessment of the liver transplant candidate. *J Am Coll Cardiol.* 2011;58(3):223–231.
16. Elapavaluru S, Gologorsky A, Thai N, et al. Perioperative Stress Cardiomyopathy in Simultaneous Liver and Kidney Transplantation: A Call for Early Consideration of Mechanical Circulatory Support. *J Cardiothorac Vasc Anesth.* 2017;31(1):248–253.
17. Tiwari AK, Attellis N. Intraoperative left ventricular apical ballooning: transient Takotsubo cardiomyopathy during orthotopic liver transplantation. *J Cardiothorac Vasc Anesth.* 2008;22(3):442–445.
18. Yataco ML, Difato T, Bargehr J, et al. Reversible non-ischaemic cardiomyopathy and left ventricular dysfunction after liver transplantation: a single-centre experience. *Liver Int.* 2014;34(6):e105–e110.