

Colonoscopic Visualisation of Benign Polyps in the Appendiceal Region

Summary

Detection of pre-malignant polyps is an important objective during colonoscopy. Careful attention is crucial to fully evaluate all luminal orifices of the colon. In this case report, we report four cases of pre-malignant polyps in the appendiceal orifice region. Herewith, we give emphasis to the importance of visualising the whole colon, including the appendiceal (orifice) region, during colonoscopy.

Introduction

The most common neoplasia of the appendix vermiformis are carcinoid tumors. The remainder is a mixed group of benign and malignant neoplasia including adenomas, mucinous cystadenomas, adenocarcinomas and metastases. Case reports have also described hyperplastic polyps, neurofibromas, schwannomas and stromal cell tumors [1].

The mode of presentation of these tumors is variable. Mostly a benign tumor of the appendix is asymptomatic and in approximately 10% of patients, the appendiceal neoplasm has been an incidental finding at the time of laparotomy for other procedures. However a presentation with acute appendicitis, lower abdominal pain or intussusceptions is not uncommon. Abdominal ultrasound studies and computed tomography scans can be helpful for larger lesions [2].

Almost all patients are managed surgically either with an appendectomy or with an ileocecal resection depending on the size of the tumor and the presumed pathology. Resection at the time of colonoscopy has rarely been undertaken because of the risks of incomplete removal and bowel perforation [3].

Detection of pre-malignant polyps is an important objective during colonoscopy. Careful attention is crucial to fully evaluate all luminal orifices of the colon. In this case report, we report four cases of pre-malignant polyps in the appendiceal orifice region. Herewith, we give emphasis to the importance of visualising the whole colon, including the appendiceal (orifice) region, during colonoscopy.

Case Presentation

Case 1

A 52 year-old-female was referred for colonoscopy by her family physician because of pain in the right lower abdomen. Colonoscopy showed multiple polyps and a polyp in the appendix region. Histopathological examination of the biopsied appendiceal polyp showed tubulovillous adenoma with low-grade dysplasia. Subsequently, the polyp was fully removed at laparoscopic appendectomy including the base of the cecum.

Case Report

Volume 5 Issue 6 - 2016

A Al-toma*

Department of Internal Medicine and Gastroenterology, St. Antonius hospital, The Netherlands

*Corresponding author: A Al-toma, Department of Internal Medicine and Gastroenterology, St. Antonius hospital, Post office box 2500, 3430 EM Nieuwegein, The Netherlands, Email: a.altoma@antoniuziekenhuis.nl

Received: September 15, 2016 | Published: December 15, 2016

Definitive pathological diagnosis showed a tubulovillous adenoma with low-grade dysplasia within the appendix and a prominent inflammatory change of the appendiceal wall.

Case 2

A 59-year-old male was admitted with rectal blood loss and hemodynamic instability. No abnormality was found at esophago-gastro-duodenoscopy. Colonoscopy was performed and a biopsy was taken from a polyp seen through the appendiceal orifice (Figure 1). Histopathologic examination of the biopsy revealed a low grade tubulovillous adenoma. One month later a laparoscopic appendectomy and resection of the base of the cecum was performed. Definitive pathological examination confirmed the biopsy report. Also, faecal stasis and lymphoid hyperplasia was found in the appendix.

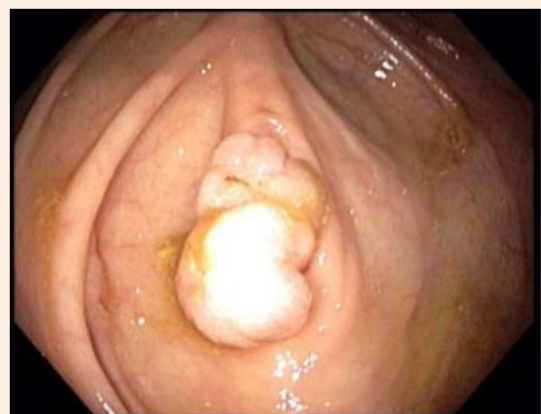


Figure 1: A benign looking polyp seen through the appendiceal orifice.

Case 3

A 57-year-old female with persistent colicky pains in her right upper abdomen after cholecystectomy was referred for colonoscopy to rule out a colonic origin for her complaints. The endoscopist removed several small polyps in the colon and observed a polyp in the appendiceal region, not suitable for endoscopic resection (Figure 2). The polyp was proved to be a tubulovillous adenoma with low-grade dysplasia. Following laparoscopic resection of the base of the cecum histopathological examination showed, in addition to adenomatous polyp, inflammatory changes of the appendix.

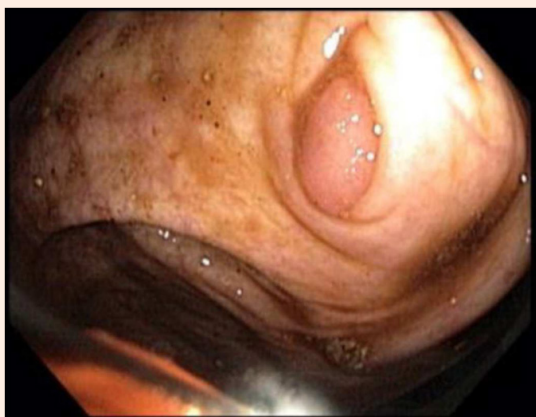

Figure 2: Tubulovillous adenoma within the appendix.

Case 4

A 74 year-old female presented with abdominal pain and persistent changes in bowel habit. Colonoscopy revealed a polyp in the base of the appendiceal orifice; findings in biopsy indicated a tubular adenoma (Figure 3). After that, a laparoscopic appendectomy and resection of the cecal base was performed. Pathological examination showed signs of inflammation of the appendix and a tubular adenoma with low-grade dysplasia of the cecal base.

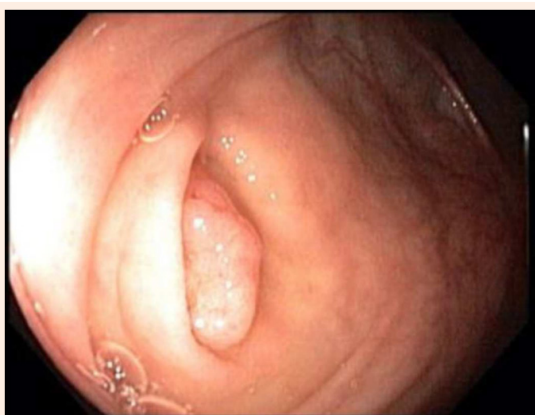


Figure 3: A tubular adenoma with low-grade dysplasia of the cecal base adjacent to the appendix opening.

Discussion

Regardless of the location in the gastrointestinal tract tubulovillous adenomas and serrated adenomas are pre-malignant polyps and should be removed. Because the appendix has a similar mucosal pattern to the colon, it has been hypothesized that appendiceal adenocarcinoma account for 1 percent of all colorectal malignancies. Furthermore, in a recent retrospective review authors report 4 percent synchronous appendiceal neoplastic lesions in patients with colonic cancer who had an appendix available for pathological examination [4].

Retrospective histopathological reviews of appendectomy specimens have shown that the most common malignant neoplasm's of the appendix are carcinoid tumours followed by adenocarcinomas [5]. Also, adenomatous polyps of the appendix are frequently reported in case reports [6-9]. A benign tumor of the appendix is mostly asymptomatic and in approximately 10% of patients, it has been an incidental finding at the time of laparotomy for other procedures. However a presentation with acute appendicitis, lower abdominal pain or intussusceptions is not uncommon. Abdominal ultrasound studies and computed tomography scans can be helpful for larger lesions. Almost all patients are managed surgically either with an appendectomy or with an ileocecal resection depending on the size of the tumor and the presumed pathology.

In three out of four patients with pre-malignant polyps, inflammatory changes were found in histopathological examination of the appendiceal wall after surgical resection [4]. It is possible that polyps in the appendiceal region cause luminal obstruction. The continued secretion of mucus could result in elevated intraluminal pressure and luminal distension. This may eventually lead to the development of chronic appendicitis, and could be the source of these patients' abdominal complaints.

As is illustrated in our four cases; the endoscopist should always consider the possibility of an appendiceal neoplasm. Therefore it is essential to expose the appendiceal region during colonoscopy. In our experience the appendiceal orifice is best inspected when it is visualised for a couple of seconds in succession so that hidden polyps 'vanishing polyps' have the possibility to unfold. Whether to perform polypectomy at the time of endoscopy or to refer all such cases for resection depends on the decision of the endoscopist. Most endoscopists performing colonoscopies are trained to remove the majority of polyps found. However, polyps that involve the appendiceal orifice are technically challenging and classified as difficult polyps because they are situated in a high-risk location and also access to them is very awkward. They may extend into the appendix, and, although this phenomenon is rare, total removal of this type of polyp is problematic and is associated with high risk of recurrence or perforation hence surgery is generally the preferred approach [3,8]. However, for those polyps at the edge of the appendiceal orifice, a similar principle to that used in peridiverticular polyps may be applied. When injecting submucosally, it is helpful to inject into the edge between the polyp and the appendix to create a cushion of fluid between them which allows adequate separation between the two and enables better polyp delineation by pushing the polyp towards the cecum.

For polyps inside the appendix, perforation risk is high. Lastly, in the current follow up guidelines of patients with colorectal polyps there is no clear recommendation concerning the appendiceal polyps [10,11]. We would advocate incorporating them in such protocols.

References

1. Charfi S, Sellami A, Affes A, Yaïch K, Mzali R, et al. (2014) Histopathological findings in appendectomy specimens: a study of 24,697 cases. *Int J Colorectal Dis* 29(8): 1009-1012.
2. Johnson EK, Arcila ME, Steele SR (2009) Appendiceal Inversion: a Diagnostic and Therapeutic Dilemma. *JLS* 3(1): 92-95.
3. Tholoor S, Tsagkournis O, Basford P, Bhandari P (2013) Managing difficult polyps: techniques and pitfalls. *Ann Gastroenterol* 26(2): 114-121.
4. Khan MN, Moran BJ (2007) Four percent of patients undergoing colorectal cancer surgery may have synchronous appendiceal neoplasia. *Dis Colon Rectum* 50(11): 1856-1859.
5. O'Donnell ME, Badger SA, Beattie GC, Carson J, Garstin WI (2007) Malignant neoplasms of the appendix. *Int J Colorectal Dis* 22(10): 1239-1248.
6. Chen YY, Soon MS, Yen SS (2006) Gastrointestinal: Adenomatous polyp of the appendix. *J Gastroenterol Hepatol* 21(3): 617.
7. Ruffolo TA, Daly C (2006) Identifying obscure appendiceal polyps: the "deflated lumen" technique. *Gastrointest Endosc* 63(4): 704-705.
8. Freeman HJ, Webber DL, Meneghetti AT (2009) An appendiceal neoplastic lesion: case report and implications for colonoscopic screening and surveillance. *Can J Gastroenterol* 23(5): 379-381.
9. Yilmaz M, Akbulut S, Kutluturk K, Sahin N, Arabaci E, et al. (2013) Unusual histopathological findings in appendectomy specimens from patients with suspected acute appendicitis. *World J Gastroenterol* 19(25): 4015-4022.
10. US Preventive Services Task Force (2016) Screening for Colorectal Cancer: US Preventive Services Task Force Recommendation Statement. *JAMA* 315(23): 2564-2575.
11. Rex DK, Ahnen DJ, Baron JA, Batts KP, Burke CA, et al. (2012) Serrated lesions of the colorectum: review and recommendations from an expert panel. *Am J Gastroenterol* 107(9): 1315-1329.