

Efficacy of paracetamol versus tramadol plus ketorolac for pain control after hemorrhoidectomy: a prospective randomized trial

Abstract

Objectives: Postoperative pain after hemorrhoidectomy is the most feared complication that may result in severe patient discomfort and in a delayed return to daily activities.

Methods: In a prospective 1:1 randomized controlled clinical trial, 50 consecutive patients (pts) with grades III and IV hemorrhoids were enrolled. All pts who underwent conventional Milligan-Morgan hemorrhoidectomy were randomly assigned to receive either 1000 mg intravenous (iv) paracetamol infusion 3 times daily (group I, 25 pts), or iv constant-infusion pump of tramadol plus ketorolac (group II, 25 patients). Pain was evaluated using a visual analogue scale (VAS) at 2, 12, 24, 36 and 48 h postoperatively. Length of hospital stay and severe complications were recorded.

Results: The two groups were homogeneous with respect to sex, age and degree of hemorrhoidal disease. No pain was recorded after 2 h in both groups due to persistence of the analgesic effect of the spinal anesthesia. Group II had a significant reduction in VAS scores at 12, 24, 36 h compared to group I ($p < 0.001$). At 48 h, 23 pts (92 %) in group II vs. 11 pts (44 %) in group I were discharged ($p = 0.001$). There were two cases of bleeding requiring surgery in group I.

Conclusion: Pain after hemorrhoidectomy is more likely to be controlled by constant-infusion pump of tramadol plus ketorolac than by interspersed infusion of paracetamol. A better pain control is associated with a shorter hospital stay.

Keywords: hemorrhoids, hemorrhoidectomy, pain, postoperative analgesia

Volume 4 Issue 6 - 2016

F Marino,¹ E Novelli,² G Manca¹

¹Department of General Surgery, Di Summa - Perrino Hospital, Italy

²Biostatistics, Italy

Correspondence: Fabio Marino, Department of General Surgery, Di Summa - Perrino Hospital, Appia S.S. 7 - 72100 Brindisi, Italy, Email Fabio.marino@virgilio.it

Received: May 21, 2016 | **Published:** June 20, 2016

Abbreviations: IV, intermittent intravenous; VAS, visual analogue scale; ANOVA, analysis of variance; EMLA, eutectic mixture of local anesthetics; GTN, glyceryl trinitrate; NMDA, N-methyl-D-aspartate; PCA, patient-controlled analgesia

Introduction

Excisional technique according to Milligan-Morgan remains the most effective approach for patients with grade III-IV hemorrhoids.¹ However, it is usually associated with significant postoperative pain that may result in severe patient discomfort and in a delayed return to daily activities. Pain seems to be multifactorial, depending on factors such as individual tolerance, method of anesthesia, surgical technique and postoperative analgesics.² The purpose of our study was to assess the efficacy of intermittent intravenous (iv) administration of paracetamol compared to continuous iv infusion of tramadol plus ketorolac on the control of post-hemorrhoidectomy pain.

Materials and methods

Study design

The present study is a prospective 1:1 randomized controlled clinical trial. Protocol synopsis and CONSORT checklist were used (Figure 1). The study protocol was reviewed and approved by the local Hospital's Institutional Review Board. Informed consent and agreement to participate in regular follow-up assessments were obtained. All patients had preoperative colonoscopy in order to exclude further colorectal diseases. In addition, patients who also had

fissures, abscesses and anal fistulas were excluded from the study. A database was created to collect patients' information pertaining to age, sex, degree of hemorrhoids, type of analgesia used during the postoperative period, postoperative pain intensity measured with a linear visual analogue scale (VAS) ranging from 0 (absence of pain) to 10 (maximum tolerable pain), early postoperative complications and duration of hospitalization.

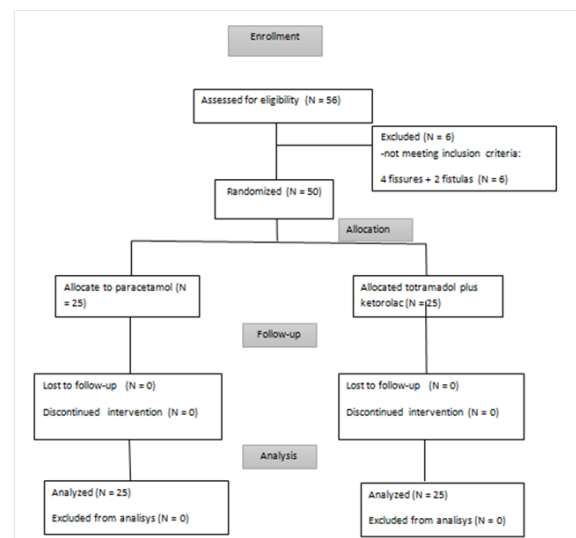


Figure 1 The consort diagram.

A rectal enema was performed to the patients on the day of operation. All patients received subarachnoid anesthesia using hyperbaric 10 mg levobupivacaine (1.5 ml 0.5% Chirocaine) +50 microg Fentanyl (0.5 ml Fentanyl). The spinal puncture was performed at L3-L4 level with a 27G Quincke needle. Furthermore, intravenous sedation was done with 2 mg of midazolam. All patients had 500 mg iv metronidazole and 1 g iv cefotaxime before starting surgical operation. All patients that underwent conventional Milligan-Morgan hemorrhoidectomy were assigned to receive either 1000 mg iv paracetamol infusion 3 times daily (group I), or iv constant-infusion pump of tramadol plus ketorolac (group II). When the intensity of postoperative pain was equal or greater than 8 in the VAS scale, either the administration of paracetamol would have been anticipated or the rate of infusion of tramadol plus ketorolac would have been increased. Patients were randomly assigned to the two groups through a computer generated randomization list. A stool softener was administered from the day after the hemorrhoidectomy and continued for 30 days. Furthermore, patients were instructed to take a warm sitz bath 2 to 3 times daily until the wounds were healed. Patient visits were scheduled at 2, 12, 24, 36 and 48 h after surgery and the VAS scale was filled in by all patients.

Statistical analysis

Continuous data were shown as mean ± SD and categorical data as counts and percentages. Normality was assessed by the Kolmogorov-Smirnov test. The Mann-Whitney U-test was utilized for non-parametric variables whereas all longitudinal outcomes were analyzed using repeated measures analysis of variance (ANOVA). Data were collected and reviewed in Microsoft Excel and statistical analysis was performed with SPSS 16.0 (SPSS Inc., Chicago, IL, USA). All 2-tailed p values <0.05 were considered statistically significant.

Results

Between March and November 2011, 50 consecutive patients with grades III and IV of hemorrhoids were recruited for this study. Twenty-five patients were included in each group. The two groups were homogeneous with respect to sex, age and degree of hemorrhoids (Table 1). Despite the study was not powered at the design stage, we utilised a software designed for sample size calculation (PASS) to estimate the power achieved after study was completed; the observed differences in means regarding 25 patients per-group ensure a power of 0.9998 for the group factor and of 1 for the other two factors. Therefore, we believe that the results of this study cannot be questioned.

There aren't significant differences between the two groups of patients regarding gender, age and degree of the haemorrhoidal disease.

No pain was recorded at 2 hours in both groups because of the persisting analgesic effect of the spinal anesthesia. The results of the repeated-measures ANOVA model suggest that a statistically significant difference exists between patients treated with tramadol plus ketorolac in comparison to patients treated with paracetamol on their overall pain perception (Table 2 & 3), with patients in group II experiencing less pain than patients in group I [F(1,48)=46.03, p<0.001]. In particular, patients in Group II displayed a significant reduction in VAS scores at 12, 24, 36 hours compared with patients in group I (-52.7%, -76.0%, -67.5% respectively, p<0.001).

The differences between the means of the VAS values in the two groups at 12h, 24h and 36h were all statistically significant (p<0.001).

Table 1 Characteristics of the enrolled patients (N=50)

| | Paracetamol (n=25) | Ketorolac e tramadol (n=25) | P |
|-------------------------------|--------------------|-----------------------------|-------|
| Gender | | | |
| Male | 18 (72.0%) | 14 (56.0%) | 0.377 |
| Female | 7 (28.0%) | 11 (44.0%) | |
| Age (years) | 51.6± 14.1 | 52.7±13.3 | 0.774 |
| Degree of haemorrhoids | | | |
| III | 13 (52.0%) | 16 (64.0%) | 0.567 |
| IV | 12 (48.0%) | 9 (36.0%) | |

Table 2 Postoperative pain perception (VAS)

| Type of treatment | | DT1_2h | DT2_12h | DT3_24h | DT4_36h | DT5_48h |
|-------------------------|----------|--------|---------|---------|---------|---------|
| Paracetamol | Mean | 0 | 5.24 | 3.84 | 3.2 | 3 |
| | N | 25 | 25 | 25 | 25 | 14 |
| | Std. Dev | 0 | 2.185 | 2.075 | 2.062 | 2.148 |
| | Median | 0 | 5 | 4 | 3 | 3 |
| Tramadol plus Ketorolac | Mean | 0.2 | 2.48 | 0.92 | 1.04 | 0 |
| | N | 25 | 25 | 25 | 25 | 2 |
| | Std. Dev | 1 | 2.124 | 1.256 | 1.457 | 0 |
| | Median | 0 | 3 | 0 | 0 | 0 |
| Total | Mean | 0.1 | 3.86 | 2.38 | 2.12 | 2.63 |
| | N | 50 | 50 | 50 | 50 | 16 |
| | Std. Dev | 0.707 | 2.548 | 2.249 | 2.076 | 2.247 |
| | Median | 0 | 4 | 2 | 2 | 3 |

Table 3 Results of the repeated-measures ANOVA model

| Variable | Ketorolac + Tramadol | Paracetamol | Group | Time | Group x Time |
|----------------|----------------------|-------------|--------|--------|--------------|
| VAS | | | <0.001 | <0.001 | 0.265 |
| After 12 hours | 2.48±2.12 | 5.24±2.19 | | | |
| After 24 hours | 0.92±1.26 | 3.84±2.08 | | | |
| After 36 hours | 1.04±1.46 | 3.20±2.06 | | | |

Moreover, starting from 12 hours after surgery, pain perception decreased over time in both groups. This significant within-subject effect [F(2,47)=10.89, p<0.001] was certainly widely expected. Finally, there was no group by time interaction [F(2,47)=1.365, p=0.265]. As the patients began to experience less pain, the pain perception of the patients treated with ketorolac-tramadol did not decrease more (or less) than that of the patients treated with paracetamol (Figure 2). The number of patients discharged after 36 hours was equal to 11 (44%) in the paracetamol group and 23 (92.0%) in the ketorolac and tramadol (p=0.001). There were two cases of severe bleeding requiring surgery in the group I. No further complications were recorded in both groups.

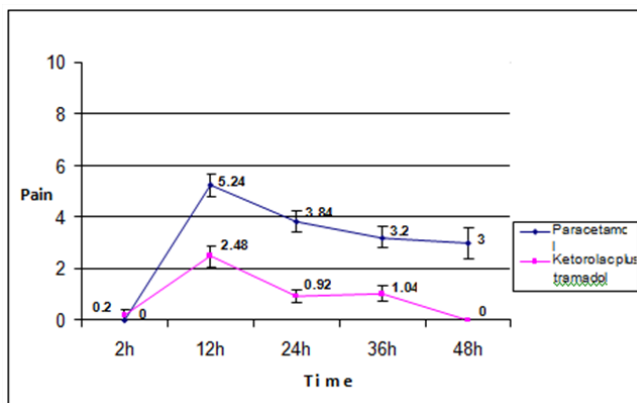


Figure 2 Trend of postoperative pain.

Discussion

Many factors may play a role in determining pain after hemorrhoidectomy: among these, there are certainly strategies of anesthesia, surgical techniques together with the energy source adopted, the modality of post-operative analgesia and the administration of medical therapy to minimize tissue edema and to facilitate wound healing. In order to optimize the result of epidural anesthesia, the addition of Clonidine (4mcg/kg) with ropivacaine 0.75% improves the analgesia within the first four hours after hemorrhoidectomy.³ Furthermore, subarachnoid anesthesia with a 0.5% bupivacaine and clonidine shows a better analgesia compared to the epidural anesthesia with a 0.75% ropivacaine with or without clonidine.⁴ With regard to the surgical techniques, there is evidence that vascular-sealing devices using radiofrequencies such as Liga Sure, (Covidien, U.S.) or ultrasound such as Harmonic scalpel, (Ethicon Endosurgery, U.S.) result in less postoperative pain compared to scissors or diathermy hemorrhoidectomy.⁵⁻⁸ Patients that have undergone stapled hemorrhoidectomy have significantly less postoperative pain with less burning and itching sensation 4 weeks after surgery compared to Milligan-Morgan operation.⁹

Stapled hemorrhoidectomy and Ligasure hemorrhoidectomy appear to be superior to conventional hemorrhoidectomy for early postoperative pain.¹⁰ Two recent meta-analyses of randomized

controlled trials comparing Ligasure hemorrhoidectomy vs. stapled hemorrhoidectomy do not reveal a statistical significant difference between the two groups of patients regarding postoperative pain.^{11,12} Furthermore, in a retrospective comparison between doppler-guided hemorrhoidal artery ligation vs. stapled hemorrhoidectomy for treating grade III hemorrhoids, patients underwent the first operation have less pain and provide earlier functional recovery.¹³ Finally, De Nardi P et al.¹⁴ in a prospective randomized trial compared dearterialization with mucopexy to hemorrhoidectomy do not reveal significant differences in the degree of postoperative pain.¹⁴ Despite Khubchandani IT¹⁵ in a prospective, randomized study did not demonstrate benefits on postoperative pain, another study found that the addition of lateral internal sphincterotomy to open hemorrhoidectomy seems to have a positive effect on reducing postoperative pain in a few patients, without affecting the postoperative complications rate.¹⁶

Regarding drugs influencing post-operative analgesia, local infiltration with liposome bupivacaine compared with placebo or bupivacaine HCl appears to significantly reduce postsurgical pain and postoperative opioid consumption in patients submitted to hemorrhoidectomy surgery.^{17,18} Moreover, in a randomized trial comparing the use of topical eutectic mixture of local anesthetics (EMLA) cream and diclofenac suppository for pain relief after hemorrhoidectomy, EMLA cream appears to be more appropriate (p<0.05) for short-term pain control while diclofenac yields a more sustainable pain control (p<0.05).¹⁹ Furthermore, a recent randomized, prospective, single-blind placebo-controlled trial has shown how intradermal injection of methylene blue during hemorrhoidectomy significantly reduces the initial postoperative pain and the use of paracetamol due to the ablation of the perianal nerve endings.²⁰

Among drugs able to reduce the spasm of the internal anal sphincter, glyceryl trinitrate (GTN) ointment significantly enhances post-operative recovery after excisional hemorrhoidectomy, reducing pain in terms of duration and intensity. This effect might be secondary to a faster wound healing process expressed by reduced secretion, bleeding and itching time.²¹ Moreover, Topical 0.4% glyceryl trinitrate appears to be effective in relieving pain and reducing anal resting pressure in patients with anal hypertonia after stapled hemorrhoidectomy.²² However, in a prospective randomized trial, a single intrasphincter injection of 20 IU of botulinum toxin appears to be more effective and safer than repeated applications of 2% glyceryl trinitrate in reducing early postoperative pain at rest but not during defecation.²³ Furthermore, some authors investigated about the use of calcium channel blocker ointment as a source to relief anal pain after hemorrhoidal disease surgery: a multicenter randomized, double-blind trial to compare the efficacy of 0.3% nifedipine and 1.5% lidocaine ointment vs. 1.5% lidocaine ointment alone reveals that the use of topical nifedipine with lidocaine may provide a slight significant benefit at 6 hours and 7 days after surgery.²⁴ Finally, the topical application of 2% diltiazem ointment in two double-blind, placebo-controlled trials has been demonstrated to significantly reduce postoperative pain without increase morbidity.^{25,26}

There is a potential benefit in using phlebotonics to alleviate post-hemorrhoidectomy symptoms including pain, resulting in lower analgesic consumption.²⁷ However, their positive effects seem to be relevant when hemorrhoidectomy techniques cause an important trauma and edema on the anal tissue like in Milligan-Morgan operation,^{28–30} whereas in less aggressive procedures as the hemorrhoidectomy with radiofrequency scalpel or stapled hemorrhoidopexy, flavonoids did not show any protective influence.^{31,32} Puigdollers A et al.³³ in a prospective study demonstrate as the impaired anal evacuation is predictive of postoperative pain after hemorrhoidectomy. Two prospective randomized trials report as the postoperatively use of the bulk agent *Plantago ovata* is more effective of glycerin oil to reduce pain, tenesmus and shorten postoperative hospital stay in patients submitted to Milligan-Morgan hemorrhoidectomy.^{34,35}

Among local pain-reducing methods, in placebo-controlled trials also the application of sucralfate,^{36–37} cholestyramine,³⁸ 10% metronidazole^{39,40} and aloe vera ointments⁴¹ has been demonstrated to play a role in postoperative discomfort reduction and in improving healing after open hemorrhoidectomy. About pharmacological interventions, dextromethorphan appears to play a potential role in controlling pain after hemorrhoidectomy. This N-methyl-D-aspartate (NMDA) receptor antagonist binds to receptor sites in the spinal cord and central nervous system, thereby blocking the generation of central acute and chronic pain sensations arising from peripheral nociceptive stimuli and enabling reduction for analgesics required for pain control. Many studies have demonstrated that oral administration or intramuscular injection of dextromethorphan could provide good postoperative pain relief and decrease the pethidine requirement after hemorrhoidectomy.^{42–44} Regarding non-steroidal anti-inflammatory drugs in pain management, a study that compared oral nimesulide (1 g three times daily) vs. naproxen (250 mg three times daily) administered the day after hemorrhoidectomy and continued for 10 days, showed that both drugs were effective in relieving pain without significant differences in terms of efficacy.⁴⁵ Furthermore, in another study comparing the use of betamethasone to diclofenac potassium in postoperative pain following closed hemorrhoidectomy, the amount of narcotics required on the postoperative first, second and third day was significantly less in the betamethasone group than in the diclofenac potassium group ($p < 0.001$).⁴⁶

Concerning the use of opioids after hemorrhoidectomy, one study reveals that transdermal fentanyl induces a better pain control vs. placebo with a lower consumption of narcotics and a significantly lower pain scores ($p < 0.05$).⁴⁷ Moreover, a trial evaluating the efficacy of oral non-steroidal analgesics vs. additional patient-controlled analgesia (PCA) with intravenous infusion of piritramid within the first 24 hours following Ferguson hemorrhoidectomy revealed that the pain score and patients' satisfaction were significantly better in additional PCA compared to control patients.⁴⁸

Finally, a pleasant hospital environment appears to influence the postoperative course and the perception of pain. A prospective randomized clinical trial evaluating the health benefits of viewing indoor plants during the recovery period after hemorrhoidectomy shows that patients in hospital rooms with plants and flowers have significantly more positive physiologic responses evidenced by lower ratings of pain, anxiety, and fatigue than patients in the control rooms.⁴⁹

At the moment, in the English literature, there are no procedure-specific studies with paracetamol. Our study is the first trial comparing the use of paracetamol vs. tramadol plus ketorolac for pain

control after hemorrhoidectomy. We demonstrated that iv constant-infusion pump of tramadol plus ketorolac is superior to 1000 mg iv paracetamol infusion 3 times daily with a significant reduction in VAS scores at 12, 24, 36 hours after hemorrhoidectomy. Our study also shows that the use of analgesics is not necessary during the two hours following surgery due to the persistence of the spinal anesthesia. Furthermore, bleeding occurred only in two patients of the group I thus, according to our findings, the use of non-steroidal anti-inflammatory drugs as Ketorolac does not appear to increase the risk of hemorrhagic complications after hemorrhoidectomy. However, due to lacking literature in support of this finding, randomized studies on larger samples are needed to confirm our data. Surgery for hemorrhoidectomy remains a painful procedure, on the other hand, pain control, especially during the first 24 hours after surgery, has been reported to increase patient satisfaction as well as to decrease urinary retention and constipation.⁴⁴

Acknowledgments

None.

Conflicts of interest

The author declares there is no conflict of interest.

Funding

None.

References

1. Jayaraman S, Colquhoun PH, Malthaner RA. Stapled versus conventional surgery for hemorrhoids. *Cochrane Database Syst Rev.* 2006;4:CD005393.
2. Joshi GP, Neugebauer EA PROSPECT Collaboration. Evidence-based management of pain after haemorrhoidectomy surgery. *Br J Surg.* 2010;97(8):1155–1168.
3. Baptista JF, Gomez RS, Paulo DN, et al. Epidural anesthesia with ropivacaine with or without clonidine and postoperative pain in hemorrhoidectomies. *Acta Cir Bras.* 2014;29(3):201–208.
4. Baptista JF, Paulo DN, Paulo IC, et al. Epidural anesthesia using a 0,75% ropivacaine and subarachnoid anesthesia with a 0,5% bupivacaine associated or not with clonidine in hemorrhoidectomies. *Acta Cir Bras.* 2008;23(6):536–542.
5. Lohsiriwat V. Hemorrhoids: from basicpathophysiology to clinicalmanagement. *World J Gastroenterol.* 2012;18(17):2009–2017.
6. Nienhuijs S, De Hingh I. Conventional versus LigaSure hemorrhoidectomy for patients with symptomatic Hemorrhoids. *Cochrane Database Syst Rev.* 2009;1:CD006761.
7. Milito G, Cadeddu F, Muzi MG, et al. Haemorrhoidectomy with Ligasure vs conventional excisional techniques: meta-analysis of randomized controlled trials. *Colorectal Dis.* 2010;12(2):85–93.
8. Bulus H, Tas A, Coskun A, et al. Evaluation of two hemorrhoidectomy techniques: harmonic scalpel and Ferguson's with electrocautery. *Asian J Surg.* 2014;37(1):20–23.
9. Kim JS, Vashist YK, Thielges S, et al. Stapled hemorrhoidopexy versus Milligan-Morgan hemorrhoidectomy in circumferential third-degree hemorrhoids: long-term results of a randomized controlled trial. *J Gastrointest Surg.* 2013;17(7):1292–1298.
10. Chen JS, You JF. Current status of surgical treatment for hemorrhoids-systematic review and meta-analysis. *Chang Gung Med J.* 2010;33(5):488–500.

11. Chen HL, Woo XB, Cui J, et al. Ligasure versus stapled hemorrhoidectomy in the treatment of hemorrhoids: a meta-analysis of randomized control trials. *Surg Laparosc Endosc Percutan Tech.* 2014;24(4):285–289.
12. Yang J, Cui PJ, Han HZ, et al. Meta-analysis of stapled hemorrhoidopexy vs LigaSure hemorrhoidectomy. *World J Gastroenterol.* 2013;19(29):4799–4807.
13. Avital S, Itah R, Skornick Y, et al. Outcome of stapled hemorrhoidopexy versus doppler-guided hemorrhoidal artery ligation for grade III hemorrhoids. *Tech Coloproctol.* 2011;15(3):267–271.
14. De Nardi P, Capretti G, Corsaro A, et al. A prospective, randomized trial comparing the short- and long-term results of doppler-guided transanal hemorrhoid dearterialization with mucopexy versus excision hemorrhoidectomy for grade III hemorrhoids. *Dis Colon Rectum.* 2014;57(3):348–353.
15. Khubchandani IT. Internal sphincterotomy with hemorrhoidectomy does not relieve pain: a prospective, randomized study. *Dis Colon Rectum.* 2002;45(11):1452–1457.
16. Kanellos I, Zacharakis E, Christoforidis E, et al. Usefulness of lateral internal sphincterotomy in reducing postoperative pain after open hemorrhoidectomy. *World J Surg.* 2005;29(4):464–468.
17. Haas E, Onel E, Miller H, et al. A double-blind, randomized, active-controlled study for post-hemorrhoidectomy pain management with liposome bupivacaine, a novel local analgesic formulation. *Am Surg.* 2012;78(5):574–581.
18. Schmidt WK, Patou G, Joshi GP. Evaluating therapeutic benefit in postsurgical analgesia requires global assessment: an example from liposome bupivacaine in hemorrhoidectomy. *Hosp Pract.* 2012;(1995)40(1):160–165.
19. Rahimi M, Kazemeini AR, Pourtabatabaei N, et al. Comparison of topical anesthetic cream (EMLA) and diclofenac suppository for pain relief after hemorrhoidectomy: a randomized clinical trial. *Surg Today.* 2012;42(12):1201–1205.
20. Sim HL, Tan KY. Randomized single blind clinical trial of intradermal methylene blue on pain reduction after open diathermy haemorrhoidectomy. *Colorectal Dis.* 2014;16(8):O283–O287.
21. Ratnasingham K, Uzzaman M, Andreani SM, et al. Meta-analysis of the use of glyceryl trinitrate ointment after haemorrhoidectomy as an analgesic and in promoting wound healing. *Int J Surg.* 2010;8(8):606–611.
22. Mari FS, Nigri G, Dall'Oglio A, et al. Topical glyceryl trinitrate ointment for pain related to anal hypertonia after stapled hemorrhoidopexy: a randomized controlled trial. *Dis Colon Rectum.* 2013;56(6):768–773.
23. Patti R, Almasio PL, Arcara M, et al. Botulinum toxin vs. topical glyceryl trinitrate ointment for pain control in patients undergoing hemorrhoidectomy: a randomized trial. *Dis Colon Rectum.* 2016;49(11):1741–1748.
24. Perrotti P, Dominici P, Grossi E, et al. Topical nifedipine with lidocaine ointment versus active control for pain after hemorrhoidectomy: results of a multicentre, prospective, randomized, double-blind study. *Can J Surg.* 2010;53(1):17–24.
25. Silverman R, Bendick PJ, Wasvary HJ. A randomized, prospective, double-blind, placebo-controlled trial of the effect of a calcium channel blocker ointment on pain after hemorrhoidectomy. *Dis Colon Rectum.* 2005;48(10):1913–1916.
26. Amoli HA, Notash AY, Shahandashti FJ, et al. A randomized, prospective, double-blind, placebo-controlled trial of the effect of topical diltiazem on posthaemorrhoidectomy pain. *Colorectal Dis.* 2011;13(3):328–332.
27. Perera N, Liolitsa D, Iype S, et al. Phlebotonics for haemorrhoids. *Cochrane Database Syst Rev.* 2012;8:CD0004322.
28. Basile M, Gidaro S, Pacella M, et al. Parenteral troxerutin and carbazochrome combination in the treatment of post-hemorrhoidectomy status: a randomized, double-blind, placebo-controlled, phase IV study. *Curr Med Res Opin.* 2001;17(4):256–261.
29. Colak T, Akca T, Dirlik M, et al. Micronized flavonoids in pain control after hemorrhoidectomy: a prospective randomized controlled study. *Surg Today.* 2003;33(11):828–832.
30. La Torre F, Nicolai AP. Clinical use of micronized purified flavonoid fraction for treatment of symptoms after hemorrhoidectomy: results of a randomized, controlled, clinical trial. *Dis Colon Rectum.* 2004;47(5):704–710.
31. Filingeri V, Buonomo O, Sforza D. Use of Flavonoids for the treatment of symptoms after hemorrhoidectomy with radiofrequency scalpel. *Eur Rev Med Pharmacol Sci.* 2014;18(5):612–616.
32. Mlakar B, Kosorok P. Flavonoids to reduce bleeding and pain after stapled hemorrhoidopexy: a randomized controlled trial. *Wien Klin Wochenschr.* 2005;117(15-16):558–560.
33. Puigdollers A, Cisternas D, Azpiroz F. Postoperative pain after haemorrhoidectomy: role of impaired evacuation. *Colorectal Dis.* 2011;13(18):926–929.
34. Kecmanovic DM, Pavlov MJ, Ceranic MS, et al. Bulk agent plantago ovata after milligan-morgan hemorrhoidectomy with ligasure. *Phytother Res.* 2006;20(8):655–658.
35. Kecmanović D, Pavlov M, Ceranić M, et al. Plantago ovata (Laxomucil) after hemorrhoidectomy. *Acta Chir Iugosl.* 2004;51(3):121–123.
36. Gupta PJ, Heda PS, Kalaskar S, et al. Topical sucralfate decreases pain after hemorrhoidectomy and improves healing: a randomized, blinded, controlled study. *Dis Colon Rectum.* 2008;51(2):231–234.
37. Ala S, Saeedi M, Eshghi F, et al. Efficacy of 10% sucralfate ointment in the reduction of acute postoperative pain after open hemorrhoidectomy: a prospective, double-blind, randomized, placebo-controlled trial. *World J Surg.* 2013;37(1):233–238.
38. Ala S, Eshghi F, Enayatifard R, et al. Efficacy of cholestyramine ointment in reduction of postoperative pain and pain during defecation after open hemorrhoidectomy: results of a prospective, single-center, randomized, double-blind, placebo-controlled trial. *World J Surg.* 2013;37(3):657–662.
39. Nicholson TJ, Armstrong D. Topical metronidazole (10 percent) decreases posthemorrhoidectomy pain and improves healing. *Dis Colon Rectum.* 2004;47(5):711–716.
40. Ala S, Saeedi M, Eshghi F, Mirzabeygi P. Topical metronidazole can reduce pain after surgery and pain on defecation in postoperative hemorrhoidectomy. *Dis Colon Rectum.* 2008;51(2):235–238.
41. Eshghi F, Hosseinimehr SJ, Rahmani N, et al. Effects of Aloe vera cream on posthemorrhoidectomy pain and wound healing: results of a randomized, blind, placebo-control study. *J Altern Complement Med.* 2010;16(6):647–650.
42. Chang FL, Wu CT, Yeh CC, et al. Postoperative intramuscular dextromethorphan injection provides postoperative pain relief and decreases opioid requirement after hemorrhoidectomy. *Acta Anaesthesiol Sin.* 1999;37(4):179–183.
43. Lin SL, Chao PC, Yeh CC, et al. Oral slow release dextromethorphan premedication provides a pethidine spare effect on posthemorrhoidectomy pain management. *Acta Anaesthesiol Taiwan.* 2004;42(2):87–91.
44. Liu ST, Wu CT, Yeh CC, et al. Premedication with dextromethorphan provides posthemorrhoidectomy pain relief. *Dis Colon Rectum.* 2000;43(4):507–510.

45. Zuckermann M, Panconesi R, Scabicabarozzi I, et al. Clinical efficacy and tolerability of nimesulide compared with naproxen in the treatment of posthaemorrhoidectomy pain and inflammation. *Drugs*. 1993;46(Suppl 1):177–179.
46. Kisli E, Başer M, Güler O, et al. Comparison of the analgesic effect of betamethasone and diclofenac potassium in the management of postoperative haemorrhoidectomy pain. *Acta Chir Belg*. 2005;105(4):388–391.
47. Kilbride M, Morse M, Senagore A. Transdermal fentanyl improves management of postoperative hemorrhoidectomy pain. *Dis Colon Rectum*. 1994;37(11):1070–1072.
48. Hancke E, Lampinski M, Suchan K, et al. [Pain management after hemorrhoidectomy. Patient-controlled analgesia vs conventional pain therapy]. *Chirurg*. 2013;84(7):587–593.
49. Park SH, Mattson RH. Ornamental indoor plants in hospital rooms enhanced health outcomes of patients recovering from surgery. *J Altern Complement Med*. 2009;15(9):975–980.