

Azathioprine-associated acute myeloid leukemia in a patient with crohn's disease (about one case)

Abstract

Azathioprine is widely used in intestinal bowel disease (IBD) and is an essential element of the therapeutic management. This drug has a recognized potential carcinogenesis and mutagenesis in lymphoproliferative disorders and non-melanoma skin cancers. Several cohort studies have assessed the risk of myeloid neoplasms (MN), such as acute myeloid leukemia (AML) or myelodysplastic syndromes (MDS) in IBD patients exposed to thiopurine before or at the time of inclusion. We describe a case of acute leukemia following azathioprine therapy in a patient with Crohn's disease, this is a 30-year-old male with an ileocecal Crohn's disease who developed acute leukemia after 9 years of exposure to azathioprine.

Keywords: inflammatory bowel disease, crohn's disease, ulcerative colitis, azathioprine, acute myeloid leukemia, myelodysplastic syndromes, myeloid neoplasms

Volume 2 Issue 4 - 2015

Fahimi M, Badre W, Cohen I, Tahiri M, Haddad F, Hliwa W, Bellabah A

Department of Gastroenterology, University Hospital Ibn Rochd, Morocco

Correspondence: Fahimi Mina, Department of Gastroenterology, Ibn Rochd Hospital, Casablanca, Morocco
Email dr-fahimi-amina@hotmail.com

Received: June 14, 2015 | **Published:** August 07, 2015

Abbreviations: IBD, intestinal bowel disease; CD, crohn's disease; UC, ulcerative colitis; AZA, azathioprine; MN, myeloid neoplasms; AML, acute myeloid leukemia; MDS, myelodysplastic syndromes; ALL, acute lymphoid leukemia

Introduction

Azathioprine has well described hematologic side effects and rare cases of acute myeloid leukemia and myelodysplastic syndrome arising in the setting of azathioprine therapy in patients followed for IBD have been reported, We report a case of acute myeloid leukemia following azathioprine therapy in a patient with Crohn's disease (CD) in the 9th year of exposure to azathioprine 150mg daily (cumulative dose 492g).

Case report

A 30-year-old Moroccan male, without personal or family history of neoplasie disease, followed since 2006 for isolated ileocecal localization of Crohn's disease, CD was diagnosed by colonoscopy, imaging studies, and pathological examination. He was initially treated with mesalazine, while there were no remission, azathioprine has been administered since 2006 at a dose of 2,5mg /kg /day with good adherence to treatment and good clinical, biological and endoscopic improvement, regular monitoring of laboratory tests including complete blood count and inflammatory assessment showed no abnormality.

In September 2014, the patient was presented with a 2-month history of infectious syndrome with a fever of 40°C, dry cough, a feeling of heaviness in the left hypochondre in a context of weakening without transit disorders nor digestive or extra-digestive hemorrhage, that is why he was hospitalized, Clinical examination showed a patient in fairly good condition, PS = 0, mucocutaneous pallor, petechial lesions on both upper and lower limbs, a significant splenomegaly without palpable lymph nodes or other masses, biologic assessment underlined a normochromic normocytic anemia with a hemoglobin at 9g/dl, thrombocytopenia 60000/mm³, a standard rate of white cells = 8340/mm³, Neutrophils = 3940/mm³, Lymphocytes = 2730/mm³, Monocytes = 1,590/mm³, hypoalbuminemia to 22g /l, with a low TP to 54% with coagulation dosage factors showing vitamin K dependent

factors deficit, the complete infectious assessment performed revealed no infectious cause, A high CRP to 110mg/l.

On the light of the bicytopenia, the infectious syndrome, petechial purpura and impaired general condition, the diagnosis of hematologic malignancy was strongly suspected, a myelogram performed underlined very high cell wealth with presence of 25% blast cells MPO negative with dysplasia signs at granulocyte and erythrocyte colony in favor of acute myeloid leukemia, a cytogenetic study was performed showing a very complex karyotype. An initial clone (6 cells) with a 5 monosomy and trisomy 1 and 3 subclones derived from the first, 6q deletion is frequently described in the lymphoid proliferations, monosomy 5 found in all analyzed cells is described in the myelodysplastic syndrome, The association with 6q deletion enables to probably conclude to a MDS transformation into ALL (Figure 1). Hence azathioprine was to be stopped and the patient was administered probabilistic antibiotic therapy with ciprofloxacin and metronidazole and vitamin K cure with standardization of his homostasis tests, the patient died a week after diagnosis.

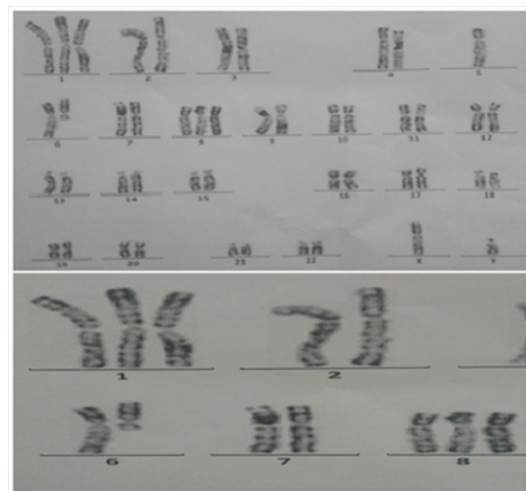


Figure 1 Complex karyotype: an initial clone (6 cells) with a 5 monosomy and trisomy 1 and 3 sub clones derived from the first, with 6q deletion.

Discussion

Azathioprine and 6-mercaptopurine are widely used in IBD and are essential in the therapeutic management.¹ In a French reference center, among Crohn's disease patients, the cumulative probability of receiving AZA 1 and 5 years after diagnosis were 40% and 71% respectively.² In the United Kingdom, thiopurine is used in 16% of patients with UC disease and 26% of patients with Crohn's disease, however, these drugs have a recognized potential carcinogenesis and mutagenesis in lymphoproliferative disorders and skin cancer non melanoma as far as both the whole dose and the treatment's duration. 7 Recent studies have shown an increased risk of lymphoproliferative disorders and skin cancer in IBD patients receiving thiopurine. In France, the annual incidence of AML in 2012 were 2.6 /100 000 for men and 2.3/100 000 for women, with 5-year relative survival of 19%.³ In IBD, Askling J et al.,⁴ showed AML risk increase of 1.8-times in patients with UC disease compared to the general population, but they could not analyze the immunosuppressive therapy impact on this risk.

The association between thiopurine and cancer in patients with IBD is complex. Indeed, due to its anti-inflammatory activity, thiopurine could reduce the risk occurrence of colorectal cancer, since chronic intestinal inflammation is now a clear risk factor for colonic neoplasia in case of IBD.⁵ However, thiopurine have a mutagenic potential and therefore intrinsic carcinogenic,⁶ which may lead to skin cancer development.⁷ Thiopurines could also give way to the development of clonal myeloid cells with repair systems of failed DNA.

The link between MN and thiopurine in patients with IBD is complex, including chronic inflammatory process and the treatment's intrinsic toxicity. This associated cancer risk has resulted in azathioprine being classified as genotoxic and a human carcinogen⁶ Although the carcinogenicity of thiopurines has been attributed to their immunosuppressive effects, comparative epidemiologic studies with other immune modulators also suggest a thiopurine-specific contribution to cancer risk. In particular, *in vitro* and animal investigations indicate that these agents are directly mutagenic.⁶ In this regard, human biomonitoring investigations have observed a significant increase in the frequency of mutant T cells following thiopurine treatment for transplant rejection and systemic lupus erythematosus, but the etiology of these increases was not discerned. To date, the specific mechanism(s) responsible for the *in vivo* carcinogenicity of thiopurine treatment has not been elucidated.

The signaling ways of phosphatidylinositol 3-kinase (PI3K), Akt (protein kinase B, PKB) and mammalian target of rapamycin (mTOR), involved in the IBD pathogenesis are frequently activated in AML.^{8,9} It is the same for the MAP ways (mitogen activated protein) kinase, both involved in LAM¹⁰ and IBD.¹¹ Meanwhile, thiopurines cause molecular lesions by 6-TGN integration in leukocytes DNA.¹² 6-TGN, more reactive than native nucleotides, lead to DNA methylation which is ultimately cytotoxic by a mechanism that depends on the ("mismatch repair system").¹³

Previous reports linking azathioprine therapy with secondary malignancies have proposed an increased risk with higher cumulative dose (>600 g) and duration of treatment (>5 years). The relatively low cumulative dose in both our patient and some previously published indicates that a subset of patients could have an increased sensitivity to the drug. One such mechanism may be reduced methylation of the drug by TPMT. TPMT follows a trimodal distribution of activity and alleles for low and high TPMT activity are inherited in an autosomal codominant fashion. About 88.6% of subjects have high activity, 11.1% intermediate activity, and 0.1% undetectable

activity. A link between low TPMT activity due to single nucleotide polymorphism and the risk of secondary AML/MDS with thiopurine therapy has previously been suggested.¹⁴ Thus low TPMT activity was demonstrated in children with acute lymphoblastic lymphoma exposed to 6 mercaptopurine who subsequently developed secondary AML or MDS. Thiopurine S-methyltransferase (TPMT) genotyping for mutations, and TPMT enzyme activity were not measured in our patient.

In Fabry et al.,¹¹ were the first to report five cases of AML in a cohort of 400 patients followed for UC.¹¹ Thereafter, nearly twenty cases have been published.¹² In a series of 734 patients with UC, Greenstein et al.¹⁵ found out an increased risk of AML over 8times compared to the general population.¹⁴ However, these studies are old and the number of reported cases was quite small, with 6 AML in the first and three in the second. In Askling et al.⁴ led out a cohort study to explore the association between hematological malignancies and IBD.¹³ AML's risk was increased in case of UC, but not in case of CD.¹³ In Anderson et al.¹⁶ have studied the MN risk among patients with autoimmune diseases.^{15,17} AML's risk was increased among 504 patients with UC, but not in the case of CD.⁴

In another study which is the first study to our knowledge to report MN incidence rates among patients treated with thiopurine for their IBD including 550 patients (380 CD and 170 UC) treated with 6-MP between 1969 and 1997 in an American reference center, 1 case of leukemia has been reported it was AML occurring in a 65year old female treated for 9years with 6-MP for a CD ileocolic. The incidence was 11 per 100,000 patient-years¹⁸ compared to 3.7 per 100,000 patient-years in the general population.¹⁹ These data are consistent with the results of the French national prospective cohort study called CESAME, having found an incidence of myeloid malignancy of 10 per 100,000 patient-years¹⁵ With MN increased risk in case of earlier use of thiopurine. Five cases of MN were recorded in this study, two AML and three MDS (three AREB1), four CD and indeterminate colitis. Of these five patients, one was administered thiopurine once diagnosed of MN, three had discontinued thiopurine therapy and had one has never received thiopurines. MN Diagnosis was suggested during the first year of follow up for one patient, during the second year for three patients and in the third year for one patient. For our patient diagnosis was made after 9years of follow-up for crohn's disease while the patient was still on treatment with AZA alone at a dose of 2mg/kg/day. In this study, the MN crude incidence rate was 10/100 000 patient-years.

These results are to be qualified because even if the risk is seven times higher in patients who received thiopurines compared to others, in absolute terms, the individual risk is only 1/10000 and must be weighed on the light of the expected benefit of treatment with thiopurine in IBD. The First myelodysplastic syndrome Cases in patients with IBD were reported in 1992.⁸ In a US cohort of 15 000 patients followed for an IBD, 25 incident cases of MDS were diagnosed between 1976 and 1997.⁸ In a population study published in 2009, the authors did not find any statistical link between MDS and IBD, with OR of 1.60 and 1.33 for CD and UC, respectively.¹⁷ In a Swedish cohort study that evaluated the relationship between MN and autoimmune diseases, patients with IBD had no more risk of developing MDS, with an OR of 1.5 for CD and 0.6 to 3,7 for UC.⁴ But to our knowledge, no studies have specifically studied the MDS risk in patients with IBD treated with thiopurine.

Beyond IBD, an increased risk of AML and SMD with a steady treatment with 6-MP / MTX was noted in a pediatric cohort of 1614

patients with 101 acute lymphocytic leukemia.^{20,21} Sixteen cases of AML or MDS were reported. A long term and high dose steady therapy with 6MP/MTX were associated with an increased risk of cancer.^{18,20}

Patients with IBD who have past thiopurine exposure are at increased risk for developing NM compared with the general population, even though the absolute risk to an individual patient is only 1/10,000 and needs to be balanced against the known benefits of thiopurines in the management of IBD. Returning to the relationship between TPMT genotype/phenotype and hematopoietic toxicity, further studies are required to define the leukemogenic risk in relation to TPMT genotypes.²² Although, the risk of secondary malignancy on azathioprine therapy generally appears to be low, subsets of patients with inflammatory disorders may have a substantially higher risk that could warrant the use of other treatments. Hence, large case-control or cohort studies are needed to determine the relative risk of malignancies for TPMT- low activity patients on thiopurine therapy.

Conclusion

The management of IBD is an important challenge for the gastroenterologist. The therapeutic objectives are to lead and keep on clinical remission, although getting mucosal healing seems increasingly inevitable. Thiopurines are recommended as first-line by learned societies to keep on remission in IBD. However, these treatments are associated with an increased risk of developing non melanoma skin cancer and myeloid disorders in case of IBD. Although the risk of developing AML is still 7 times higher in patients who received thiopurines compared to others, in absolute terms, the individual risk is only 1/10 000 and should be considered when prescribing Such treatments for IBD, although these results must be confirmed by other independent studies.

Acknowledgments

None.

Conflicts of interest

Author declares there are no conflicts of interest.

Funding

None.

References

- Dignass A, Lindsay JO, Sturm A, et al. Second European evidence-based consensus on the diagnosis and management of ulcerative colitis part 2: current management. *J Crohns Colitis*. 2012;6(10):991–1030.
- Peyrin-Biroulet L, Oussalah A, Williet N, et al. Impact of azathioprine and tumour necrosis factor antagonists on the need for surgery in newly diagnosed Crohn's disease. *Gut*. 2011;60(7):930–936.
- Maynadié M, Girodon F, Manivet-Janoray I, et al. Twenty-five years of epidemiological recording on myeloid malignancies: data from the specialized registry of hematologic malignancies of Cote d'Or (Burgundy, France). *Haematologica*. 2011;96(1):55–61.
- Askling J, Brandt L, Lapidus A, et al. Risk of haematopoietic cancer in patients with inflammatory bowel disease. *Gut*. 2005;54(2):617–622.
- Rutter M, Saunders B, Wilkinson K, et al. Severity of inflammation is a risk factor for colorectal neoplasia in ulcerative colitis. *Gastroenterology*. 2004;126(2):451–459.
- Nguyen T, Vacek PM, O'Neill P, et al. Mutagenicity and potential carcinogenicity of thiopurine treatment in patients with inflammatory bowel disease. *Cancer res*. 2009;69(17):7004–7012.
- Harwood CA, Attard NR, O'Donovan P, et al. PTCH mutations in basal cell carcinomas from azathioprine-treated organ transplant recipients. *Br J Cancer*. 2008;99(8):1276–1284.
- Martelli AM, Tazzari PL, Evangelisti C, et al. Targeting the phosphatidylinositol 3-kinase/Akt/mammalian target of rapamycin module for acute myelogenous leukemia therapy: from bench to bedside. *Curr Med Chem*. 2007;14(19):2009–2023.
- Geest CR, Coffey PJ. MAPK signaling pathways in the regulation of hematopoiesis. *J Leukoc Biol*. 2009;86(2):237–250.
- Korelitz BI, Mirsky FJ, Fleisher MR, et al. Malignant neoplasms subsequent to treatment of inflammatory bowel disease with 6-mercaptopurine. *Am J Gastroenterol*. 1999;94(11):3248–3253.
- Coskun M, Olsen J, Seidelin JB, et al. MAP kinases in inflammatory bowel disease. *Clin Chim Acta*. 2011;412(7–8):513–520.
- Warren DJ, Andersen A, Slordal L. Quantitation of 6-thioguanine residues in peripheral blood leukocyte DNA obtained from patients receiving 6-mercaptopurine-based maintenance therapy. *Cancer Res*. 1995;55(8):1670–1674.
- Karran P, Attard N. Thiopurines in current medical practice: molecular mechanisms and contributions to therapy-related cancer. *Nat rev Cancer*. 2008;8(1):24–36.
- Yenson PR, Forrest D, Schmiegelow K, et al. Azathioprine-associated acute myeloid leukemia in a patient with Crohn's disease and thiopurine S-methyltransferase deficiency. *Am J Hematol*. 2008;83(1):80–83.
- Greenstein AJ, Gennuso R, Sachar DB, et al. Extraintestinal cancers in inflammatory bowel disease. *Cancer*. 1985;56(12):2914–2921.
- Anderson LA, Pfeiffer RM, Landgren O, et al. Risks of myeloid malignancies in patients with autoimmune conditions. *Br J Cancer*. 2009;100(5):822–820.
- Ramadan SM, Fouad TM, Summa V, et al. Acute myeloid leukemia developing in patients with autoimmune diseases. *Haematologica*. 2012;97(6):805–817.
- Hemminki K, Li X, Sundquist K, et al. Cancer risk in hospitalized rheumatoid arthritis patients. *Rheumatology (Oxford)*. 2008;47(5):698–701.
- SEER Cancer Statistics Review. Surveillance, Epidemiology, and End Results Program—Turning Cancer Data into Discovery. (1975–2008).
- Schmiegelow K, Al-Modhwah I, Andersen MK, et al. Methotrexate/6-mercaptopurine maintenance therapy influences the risk of a second malignant neoplasm after childhood acute lymphoblastic leukemia: results from the NOPHO ALL-92 study. *Blood*. 2009;113(24):6077–6084.
- Kristinsson SY, Björkholm M, Hultcrantz M, et al. Chronic immune stimulation might act as a trigger for the development of acute myeloid leukemia or myelodysplastic syndromes. *J Clin Oncol*. 2011;29(21):2897–2903.
- Lopez A, Mounier M, Bouvier AM, et al. Increased risk of acute myeloid leukemias and myelodysplastic syndromes in patients who received thiopurine treatment for inflammatory bowel disease. *Clin Gastroenterol Hepatol*. 2014;12(8):1324–1329.