

# Endovascular procedure for diabetics with critical limb ischemic disease

**Keywords:** peripheral arterial obstructive disease, critical limb ischemia, endovascular procedure, Percutaneous transluminal angioplasty

**Abbreviations:** PAOD, peripheral arterial obstructive disease; CLI, critical limb ischemia; EP,

endovascular procedure; TASC, trans atlantic inter society consensus; PTA, percutaneous transluminal angioplasty; BTK, below the knee; ATK, above the knee

## Editorial

When peripheral arterial obstructive disease (PAOD) occurs with diabetes mellitus, is more likely to be conducive to critical limb ischemia (CLI) and amputation than in the absence of diabetes.<sup>1</sup> Recognition of the diabetic patient with CLI is the key of reduction amputations rate, with a team approach doing clinical and glucose control, pain relief, healing ulcers, limb loss prevention, increased survival and improved quality of life.<sup>1,2</sup> At the 1990s by pass revascularization was the only technique solution for distal arteries access.<sup>2</sup> A systematic review (12,779 patients with critical ischemia) noted that the endovascular procedure (EP) offered better results in outcomes mortality, amputation rates and amputation-free survival and in longer periods, no difference was found between surgery and EP.<sup>3</sup>

CLI, the most advanced form of PAOD, is defined according to the Trans-Atlantic Inter-Society Consensus (TASC) II as chronic ischemic rest pain or nonhealing ischemic lesions of the lower extremity with symptoms lasting for more than 2 weeks and an ankle systolic blood pressure of 50 mm Hg and / or toe systolic blood pressure of 30 mm Hg.<sup>4</sup> CLI is associated with a high risk of cardiovascular events including major amputation, and death.<sup>1-4</sup> Over the last 15 years, endovascular therapy has markedly evolved and become widely utilized<sup>5,6</sup> such that many authors now consider endovascular therapy as first-line therapy.<sup>4,6-12</sup> Percutaneous transluminal angioplasty (PTA) with adjunctive stenting is a well validated and increasingly used technology, and it is the technique most frequently employed for infrainguinal treatment.<sup>13</sup>

CLI due to diabetic arterial disease, characterized by multiple and below-the-knee (BTK) vessels, will become candidates for Endoluminal therapy patients as restoring adequate blood supply to the wound is essential, thus avoiding major amputations.<sup>14</sup> The range of technical endovascular revascularization possibilities for long tibial artery occlusions has recently increased considerably enabling anterograde Endoluminal or even sub-intimal recanalization of occluded segments in 80% of cases.<sup>14</sup> Ferraresi, et al.,<sup>15</sup> shown that concomitant PTA of above the knee (ATK) and BTK arteries is highly beneficial for limb salvage in patients with CLI, they also investigated outcomes in diabetic patients with CLI associated with isolated small BTK-vessel disease.<sup>15</sup> The limb salvage rate was 93%, after 1 year,

Volume 3 Issue 2 - 2016

Paulo Eduardo Ocke Reis<sup>1,2</sup>

<sup>1</sup>Department of Specialized and General Surgery, Fluminense Federal University, Brazil

<sup>2</sup>Vascular Clinic Ocke Reis, Rio de Janeiro, Brazil

**Correspondence:** Paulo Eduardo Ocke Reis, Department of Specialized and General Surgery, Fluminense Federal University, Rio de Janeiro, Brazil, Tel +55 21 2629 5000, Email vascular@pauloocke.com.br

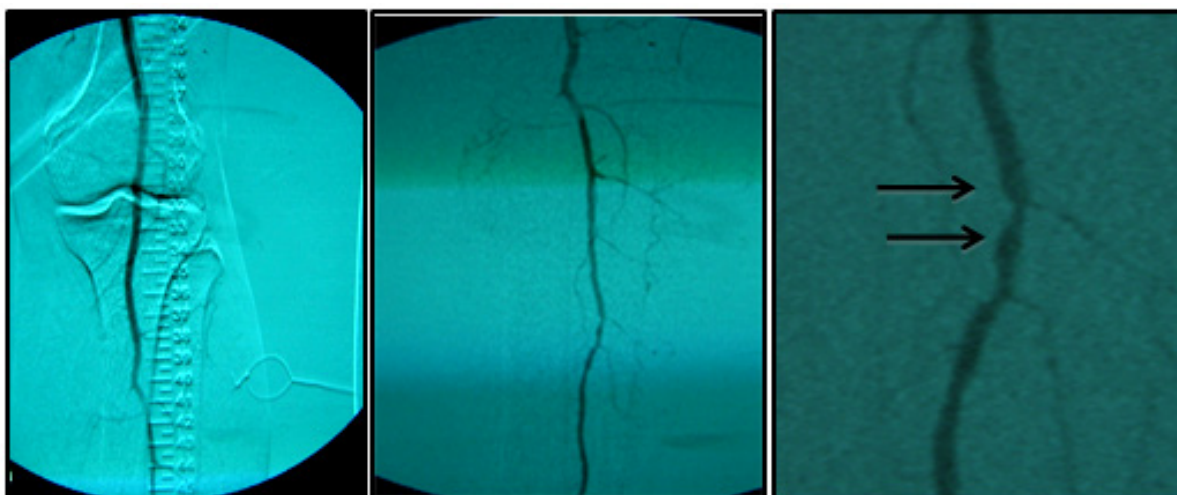
**Received:** June 28, 2016 | **Published:** July 06, 2016

target-vessel restenosis had occurred in 42% of the non-amputated limbs, nine patients (9%) had died because of medical conditions unrelated to PTA and three patients had undergone repeat PTA for recurrent CLI. In that selected patient population with ischemic diabetic foot and isolated BTK lesions, a successful endovascular procedure led to a high percentage of limb salvage at long-term follow-up.<sup>15</sup> Technical details of endovascular BTK revascularization must be conducted with indispensable care in patients with diabetes. Although difficult, the procedure can be effective through a detailed approach, a variety of tactics and techniques for endovascular revascularization and treatment of arterial occlusions increased allowing higher success rates with these greatly endoluminal procedures.<sup>2-9,11</sup> Technical success provided by EP has allowed the advance in new approach to treat critical PAOD, its highlights the feasibility, safety and efficacy to treat diabetics with CLI.

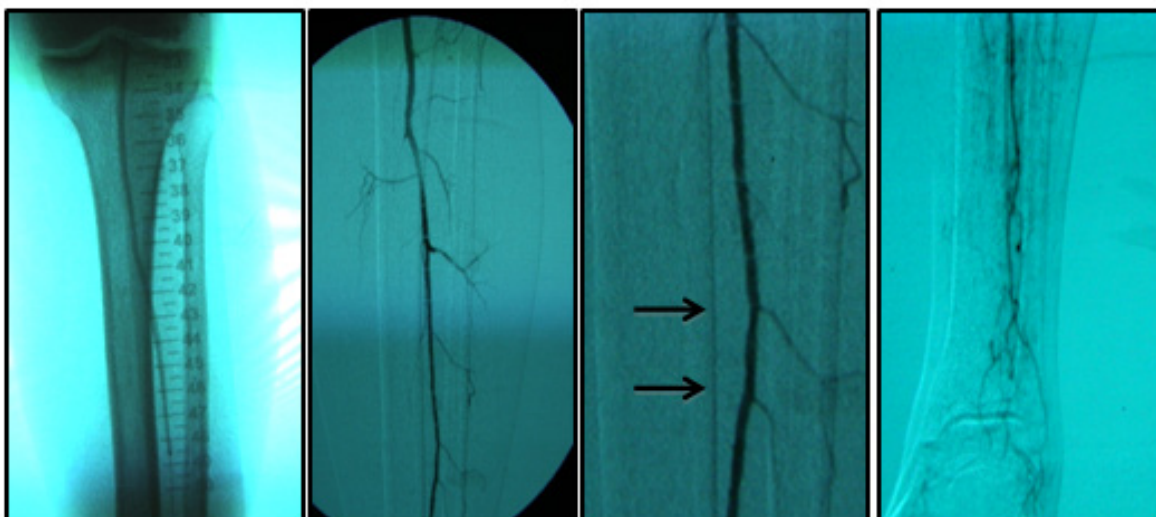
An example: A 77-year-old, diabetic woman, complaining of rest pain in her left leg and carrier ulceration on the left hallux. The physical examination showed absence of distal pulses in her left leg. Color Doppler ultrasound performed before treatment confirmed BTK critical lesions with no patency and a diagnosis of CLI.

Endovascular procedure was done with antegrade access in the ipsilateral common femoral artery, diagnostic angiography confirmed: Patency of the femoral-popliteal axis, occlusion of the posterior and anterior tibial arteries, two critical stenotic lesions in the fibular artery and revascularization of the dorsalis pedis and plantar arteries by the fibular artery. To treat the fibular critical atherosclerotic lesions were performed a percutaneous transluminal angioplasty using a 0.0018in. guidewire, catheter support and a catheter balloon (3,0x6 mm and 3,5x 15mm).

Final angiographic control showed patency of the fibular artery and dorsalis pedis, with direct flow for the first metatarsal artery, thus guaranteeing enough flow to heal the ulcer in six months after the procedure. In conclusion endovascular treatment has a high technical eligibility with good reported outcomes and represents an alternative for diabetics with CLI Disease.



**Figure 1:** Angiography from left to right showing femoral-popliteal axis, occlusion of the posterior and anterior tibial arteries, in detail two critical stenotic lesions in the fibular artery.



**Figure 2:** From left to right showing percutaneous transluminal BTK balloon angioplasty, and revascularization of the dorsalis pedis and plantar arteries by the fibular artery.

## Acknowledgments

None.

## Conflicts of interest

The author declares there is no conflicts of interest

## References

1. Coccheri S. Approaches to prevention of cardiovascular complications and events in diabetes mellitus. *Drugs*. 2007;67(7):997–1026.
2. Pomposelli FB, Kansal N, Hamdan AD, et al. A decade of experience with dorsalis pedis artery bypass: analysis of outcome in more than 1000 cases. *J Vasc Surg*. 2003;37(2):307–315.
3. Jones WS, Dolor RJ, Hasselblad V, et al. Comparative effectiveness of endovascular and surgical revascularization for patients with peripheral artery disease and critical limb ischemia: systematic review of revascularization in critical limb ischemia. *Am Heart J*. 2014;167(4):489–498.
4. Norgren L, Hiatt WR, Dormandy JA, et al. Inter-Society Consensus for the Management of Peripheral Arterial Disease (TASC II). *J Vasc Endovasc Surg*. 2007;45(Suppl S):S5–67.
5. Mills JL. Open bypass and endoluminal therapy: complementary techniques for revascularization in diabetic patients with critical limb ischemia. *Diabetes Metab Res Rev*. 2008;24(Suppl 1):S34–39.
6. Mills JL. Lower limb ischemia in patients with diabetic foot ulcers and gangrene: recognition, anatomic patterns and revascularization strategies. *Diabetes Metab Res Rev*. 2016;32(Suppl 1):239–245.
7. Faglia E, Dalla Paola L, Clerici G, et al. Peripheral angioplasty as the first-choice revascularization procedure in diabetic patients with critical limb ischemia: prospective study of 993 consecutive patients hospitalized and followed between 1999 and 2003. *Eur J Vasc Endovasc Surg*. 2005;29(6):620–627.
8. Dorros G, Jaff MR, Dorros AM, et al. Tibioperoneal (outflow lesion) angioplasty can be used as primary treatment in 235 patients with critical critical limb ischemia: five-year follow-up. *Circulation*. 2001;104(17):2057–2062.

9. Meloni M, Giurato L, Izzo V, et al. Long term outcomes of diabetic haemodialysis patients with critical limb ischemia and foot ulcer. *Diabetes Res Clin Pract.* 2016;116:117–122.
10. Uccioli L, Gandini R, Giurato L, et al. Long-term outcomes of diabetic patients with critical limb ischemia followed in a tertiary referral diabetic foot clinic. *Diabetes Care.* 2010;33(5):977–982.
11. Jämsén T, Manninen H, Tulla H, et al. The final outcome of primary infrainguinal percutaneous transluminal angioplasty in 100 consecutive patients with chronic critical limb ischemia. *J Vasc Interv Radiol.* 2002;13(5):455–463.
12. Hinchliffe R J, Brownrigg JRW, Andros G, J, et al. Effectiveness of revascularization of the ulcerated foot in patients with diabetes and peripheral artery disease: a systematic review. *Diabetes Metab Res Rev.* 2016;32(Suppl 1):136–144.
13. Markose G, Bolia A. Subintimal angioplasty in the management of lower limb ischemia. *J Cardiovasc Surg (Torino).* 2006;47(4):399–406.
14. Pernès JM, Auguste M, Borie H, et al. Infrapopliteal arterial recanalization: A true advance for limb salvage in diabetics. *Diagn Interv Imaging.* 2005;96(5):423–434.
15. Ferraresi R, Centola M, Ferlini M, et al. Long-term outcomes after angioplasty of isolated, below-the-knee arteries in diabetic patients with critical limb ischemia. *Eur J Vasc Endovasc Surg.* 2009;37(3):336–342.