

# Outcomes for extra-ocular/orbital sebaceous carcinoma of the head & neck

## Background

Sebaceous glands are holocrine adnexal components of the skin that are usually found in close association with hair follicles. Historically, malignancies of the ocular adnexa were felt to be more aggressive than extra-ocular lesions, having greater potential for local invasion and metastatic spread. Recent literature suggests that the prognosis for extra-ocular sebaceous carcinoma SC is similar to that of oculo-cutaneous lesions.

## Methods

We present 7 cases of extra-ocular malignancies arising from sebaceous glands in the head and neck. The cases of extra-orbital sebaceous cell malignancies in the world literature are also reviewed; their salient clinical, histology, and pathologic features are described (Figure 1-4).

Volume 2 Issue 2 - 2015

Majid Al Thobaiti, Marc Camilon, Gabriel Calzada, Peter Martin, Michael McNicoll, Young Oh, Mark Segal, Terry Y Shibuya

Department of Head and Neck Surgery, Southern California Permanente Medical Group, USA

**Correspondence:** Majid Al Thobaiti, Department of Head & Neck Surgery, Southern California Permanente Medical Group, USA, Tel 00966554999047, Email msa-thobaiti@hotmail.com

**Received:** October 31, 2014 | **Published:** June 06, 2015

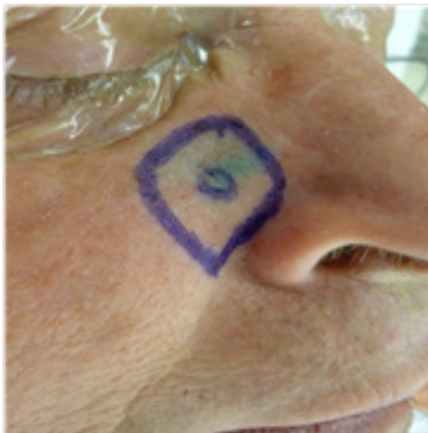

Figure 1 SC of cheek at time of resection after lymphoscintigraphic injection.

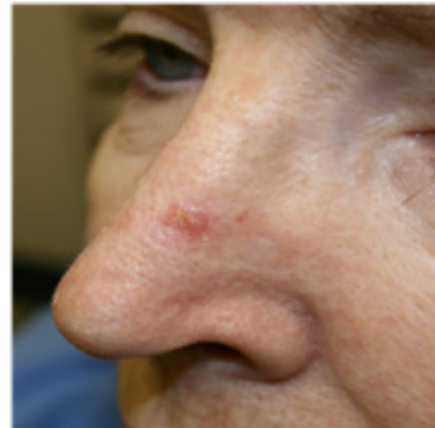


Figure 3 SC on the nasal dorsum.

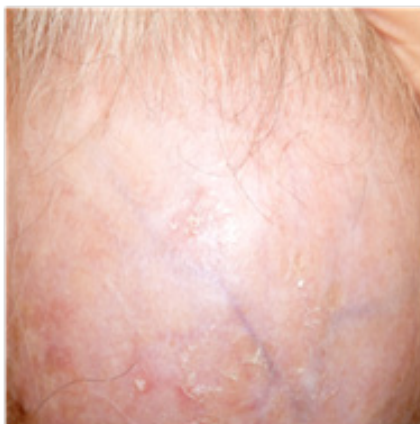

Figure 2 SC on the forehead.

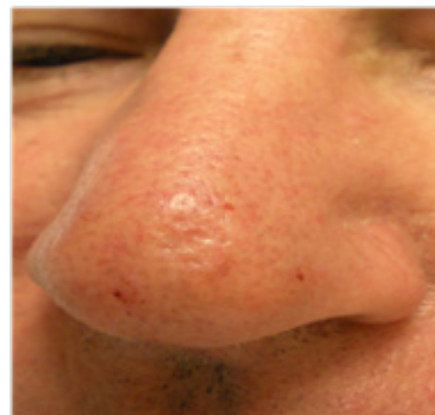

Figure 4 SC on the tip of the nose.

### Results

- a. Between 2008 and 2011, all cases of extra-ocular SC of the head & neck were identified. Retrospective chart review (Table 1) was performed and: age, sex, stage, location, SLNB, disease status, survival, correlation of disease status and SNLB.
- b. 7 Cases were identified where average age was 75 years old (65-85 years); with 4 Males and 3 Females.
- c. Classification includes 6 Stage I cancer and 1 Stage IV cancer.

- d. Extra-ocular SC locations: 2 cheek, 2 nose, 1 forehead, 1 neck, and 1 scalp (Table 2).
- e. Sentinel lymph node mapping was performed in 5 cases and biopsy was performed in 4 cases (Table 3).
- f. All patients are alive and disease free.
- g. A negative sentinel lymph node mapping or biopsy correlated with no evidence of metastatic disease in all cases.

**Table 1** Retrospective chart review

Patient #	Age	Sex	Stage	Location	Sentinal lymph node mapping	Biopsy or neck dissection	Procedure	Radiation	Disease status	Survival (Months)
1	85	F	I	Forehead	Yes	No	Wide excision of scalp CA, sentinal lymph node mapping	No	NED	18
2	69	M	I	Cheek	Yes	Yes	Right cheek CA resect and right neck sentinal node biopsy x 2	No	NED	18
3	65	M	I	Nose	Yes	No	Wide resection of nasal CA, sentinal node mapping	No	NED	30
4	75	F	I	Nose	Yes	Yes	Wide excision of nasal CA, sentinal lymph node bx	No	NED	42
5	79	M	I	Ear	Yes	No	Wide excision of left posterior ear skin CA and alloderm graft	No	NED	36
6	82	F	4	Cheek	No	Yes	Left cheekCA wide resect, left parotid, left ND zone 1-5	Yes	NED	19
7	68	M	I	Neck	No	Yes	Wide resection right neck CA and right neck dissection zone 2-5	No	NED	9

**Table 2** Extra-ocular SC locations at different stages.

Average age	74.7 Years
<b>Sex</b>	
Male	4
Female	3
<b>Stage</b>	
1	6
2	0
3	0
4	1
<b>Location</b>	
Cheek	2
Nose	2
Ear	1
Neck	1
Forehead	1

**Table 3** Sentinal lymph node mapping.

Sentinal lymph node mapping		Neck disease status		Post op radiation		Disease status	
Yes	5	Pathologically positive	1	Yes	1	NED	7
No	2	Pathologically negative	6	No	6	Average survival	24.6 months

## Conclusion

Extra-ocular sebaceous cell carcinoma is a very rare malignancy. Our hospital based series is one of the largest reported to date. Aggressive surgical management is recommended and the use of SLNB can help predict whether metastatic disease is present.

## Acknowledgments

None.

## Conflicts of interest

The author declares there is no conflict of interest.