

Diagnosis and management of serpiginous choroiditis

Abstract

Purpose: Serpiginous choroiditis (SC) is a rare, bilateral, idiopathic inflammatory disorder that causes geographic destruction of the retina and choroid often in healthy middle-aged patients. Symptoms include blurred vision, central and paracentral scotomas. SC is part of a group termed white dot syndromes which involves inflammation of the retina and choroid with the appearance of white dots in the fundus. SC requires a thorough workup prior to treatment to rule out other inflammatory autoimmune or infectious etiologies. Early stages are challenging to diagnose. Treatment includes corticosteroids and immunosuppressive therapy. The exact cause of Serpiginous Choroiditis is not known, yet HLA-B7 is typically positive indicating an autoimmune response in these patients. Choroidal neovascularization and cystoid macula edema are side effects, so close monitoring is important. This case presents a holistic clinical picture of SC to aid in better clinical diagnosis and understanding of this condition for the primary care eye clinician.

Results: Presentation of a young otherwise healthy 37-year-old male patient to our clinical service revealed a serpentine shaped retina presentation absent of anterior chamber or vitreous inflammation. Fundus photos, fluorescein angiography, and ocular coherence tomography revealed serpiginous choroiditis. Primary care workup to rule out systemic conditions was unremarkable. Initial treatment with monitoring included intravitreal triamcinolone 2 mg/0.05 mL OU with oral chlorambucil therapy immediately afterwards. Active lesions resolved over the next 3 weeks, yet visual acuity showed no improvement as the fovea was already involved. The goal of chlorambucil therapy for 3 months was to induce sustained remission.

Conclusion: Prognosis of SC is less favorable when the macula is involved (macular SC). Upon clinical presentation of serpiginous choroiditis, it is important to establish etiology of non-infectious autoimmune disorders or infectious disorders before classification of idiopathic SC and aggressive treatment to address underlying systemic conditions.

Keywords: serpiginous choroiditis, white dot syndrome, retinal inflammation, rare retinal diseases

Volume 12 Issue 3 - 2022

Jeanie C Lucy

Assistant Professor, Northwestern University, United States of America

Correspondence: Jeanie C Lucy, Assistant Professor, Northwestern University, Chicago College of Optometry, 555 Lacey Road, Downers Grove, IL 60515, USA, Tel 630 960-3928, Email jlc Lucy@northwestern.edu

Received: September 10, 2022 | **Published:** September 21, 2022

Introduction

Serpiginous choroiditis (SC) is a rare, idiopathic, bilateral inflammatory disorder that results in geographic destruction of the retina including the retinal pigment epithelium (RPE), and choriocapillaris which leaves scars.¹ Old SC scars are often areas of reactivation. The pathological course of SC presents as multiple recurrences at intervals of months to years. Primary care workup to rule out systemic conditions. SC is part of a group termed white dot syndromes which involves inflammation of the retina and choroid with the appearance of white dots in the fundus. Focal and diffuse accumulation of lymphocytes has been observed in the choroid. There are other features of SC indicative of an inflammatory process including sometimes yet not always an increased frequency of HLA-B7 in patients with SC.¹ The mean age at the time of initial diagnosis of SC in Caucasians is reported to be from 43.4 to 59.1 years, the average age is 30.3 years in other races and SC has been identified in patients as young as 11 years of age and as old as age 70.² Notably, SC has been observed in Asian, African American, Middle Eastern, Asian Indian, and Spanish patients.² SC is chronic, recurrent and progressive. There is a slight male predominance, but no racial predilection or consistent genetic factors have been associated with the disease.² Epidemiological studies indicate that the actual prevalence of SC in the general population is not well defined, but uveitis studies from clinical reporting practices, as well as from referral uveitis clinics, show that SC is rare.³ Overall in the United States, SC cases have been reported, as only 2.7% of the population.⁴

The highest percentages have been reported in India as 5.4% yet this may reflect tuberculosis-related choroiditis cases misclassified as SC.

Until the fovea is involved, patients are mostly asymptomatic, and they typically present with painless blurry vision and central or paracentral scotomas.⁵ Other ocular complications associated with SC include choroidal neovascularization (CNV), which accounts for about 20% of all cases, cystoid macular edema (CME), retinal vein occlusion, retinal vasculitis, and macular hole.⁵ Of the two types of serpiginous choroiditis, classic SC (CSC) makes up approximately 80% of cases. Classic demonstrates the characteristic bilateral asymmetric serpiginous (snakelike) or geographic yellow gray chorioretinal lesions that typically start at the peripapillary region and can extend into the macula.⁶ Macular SC (MSC) involves the macula and spares the peripapillary region.⁷ Macula SC should be differentiated from geographic atrophy, as seen in macular degeneration, or with macular ischemia associated with various vasculopathies.

Case report

A 37-year-old Asian male presented to the clinic for an annual eye exam due to blurry vision in both eyes at distance and near which had gotten progressively worse over the past week. The blur was constant and coupled with sensitivity to light especially while working at the computer. Last eye exam was 10 years ago in Pakistan. The patient works as an IT technical support person from home and reported being married with two small children. No family history or personal history of diabetes, hypertension, glaucoma or blindness. The patient

never smoked and had no previous injury to the eyes. The patient reported that his permanent resident was the United States and that he had not traveled outside of the United States over the past five years. When he did travel he went to Pakistan to visit family for a period of one month. Best corrected visual acuities were 20/30 OD & OS at distance and 20/30 OD & OS at near. Lids, lashes, conjunctiva and external ocular adnexa were all within normal limits. Eye pressures were 12mmHg OD and 13mmHg OS using Goldmann Applanation Tonometry and cup to disc ratios were .15/.15 OD and OS. Dilated fundus exam revealed bilateral asymmetric serpiginous (snakelike) geographic yellow gray chorioretinal lesions in the periphery that extended to the macula area.

Dilated fundus exam shows geographic punched out yellow gray chorioretinal lesions in both eyes (Figure 1). The OCT shows lesions primarily in the outer retinal layers and choriocapillaris with increased reflectivity localized to the outer retina and disruption of the photoreceptor bands. There are a few older lesions demonstrated as atrophy and RPE disruption (Figure 2). Primary Care workup included chest x-ray, complete blood count, comprehensive metabolic panel, Interferon gamma release assay TB testing, angiotensin-converting enzyme/lysozyme, rapid plasma testing, syphilis antibody test, and herpes simplex virus 1 and 2 antibodies. All tests were within normal limits. This patient was diagnosis with idiopathic serpiginous choroiditis (SC) with foveal involvement in both eyes. The patient was also co-managed with a retinal specialist. The treatment plan included intravitreal triamcinolone 2 mg/0.05 mL OU with oral chlorambucil therapy immediately afterwards Active lesion resolved over the next 3 weeks, yet visual acuity showed no improvement as the foveal was already involved. The goal of chlorambucil therapy for 3 months was to induce sustained remission in Figure 3& 4.

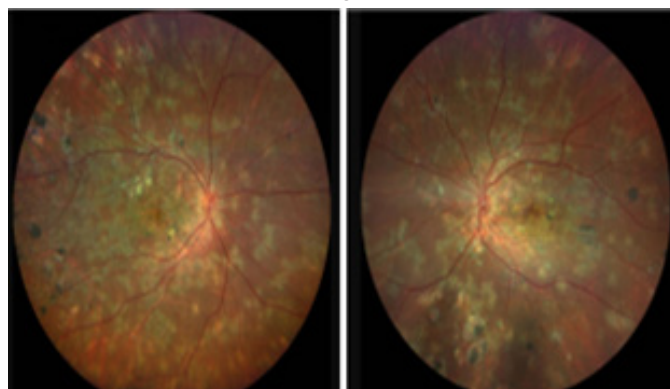


Figure 1 Right and left eye respectively show characteristic yellow-gray geographic lesions in both eyes.

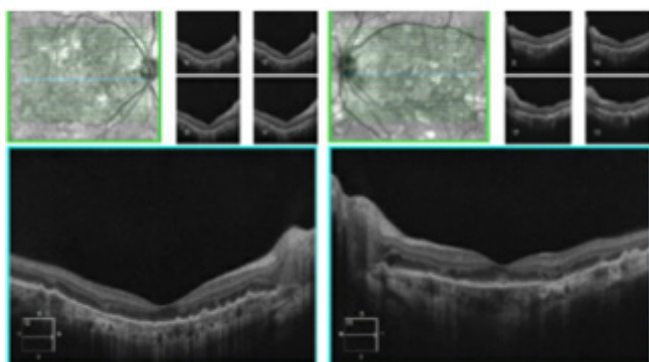


Figure 2 Imaging of the right and left eye shows complete retinal pigment epithelial and outer retinal atrophy and disruption with subfoveal involvement.

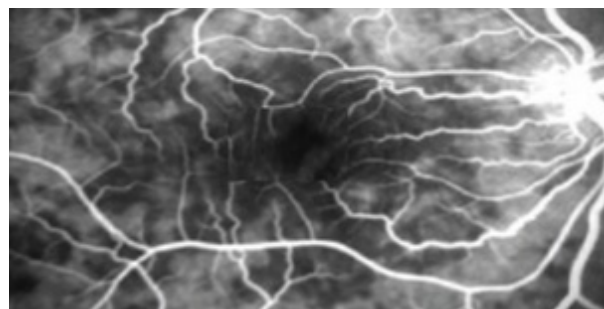


Figure 3 shows the right eye with hyperfluorescent lesions areas indicating acute active disease. Angiogram (FFA) indicative.

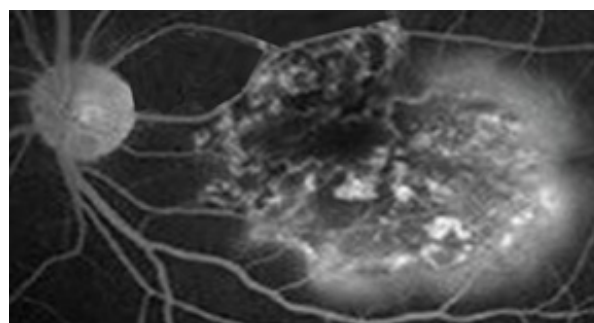


Figure 4 shows the left eye with scattered distinct lesion areas indicating acute active disease.

Discussion

Current criteria for serpiginous choroiditis include (1) choroiditis with an ameboid or serpentine shape; (2) characteristic imaging on fluorescein angiography or fundus autofluorescence; (3) absent to mild anterior chamber and vitreous inflammation; and (4) the exclusion of tuberculosis.⁸ This classification was developed by The Standardization of Uveitis Nomenclature (SUN) Working Group which is an international collaboration that has developed classification criteria for 25 of the most common uveitides using a formal approach to development and classification. Among the diseases studied was serpiginous choroiditis.⁹

Classifications

Serpiginous choroiditis has been classified into non-infectious, infectious types and idiopathic. This case represented idiopathic SC. Narrowing down etiology should include non-infectious autoimmune disorders and infectious disorders before a classification of idiopathic SC is assigned or aggressive treatment is initiated. Classifications, etiologies and morphological variations are mainly due to new advancements in molecular diagnosis. Classic serpiginous choroiditis (CLC) classifications are designated for etiologies that are autoimmune, and non-infectious. Serpiginous like choroiditis (SLC) and multifocal serpiginous choroiditis (MSC) are classifications used to denote subtypes of SC associated with infectious types.¹⁰

Non-infectious SC

Non-infectious cases of SC may include sarcoid, age-related macular degeneration, cancer, and spondyloarthropathies.

Infectious SC

Infectious etiologies include herpes simplex and zoster, toxoplasmosis, syphilis, multifocal choroiditis, acute posterior

multifocal placoid pigment epitheliopathy, and *Mycobacterium tuberculosis* (TB). Other differential diagnosis of the more atypical choroiditides include as histoplasmosis, posterior scleritis, reticulum cell sarcoma, lymphoid neoplasia, diffuse unilateral subacute neuroretinitis, and Lyme disease, or the more common idiopathic syndromes, such as the pachychoroidal disease spectrum, sarcoidosis, Vogt-Koyanagi-Harada syndrome, and sympathetic ophthalmia.¹¹ of the various infections, TB is the most common infectious organism implicated in etiopathogenesis of SLC. Therefore, in places where TB is endemic, it must be ruled out before aggressive ocular treatment is initiated.⁹

Treatment

Treatment protocol for serpiginous choroiditis remains controversial. Oral steroids remain the standard of care, yet there is often a need for immunosuppressive drugs in view of non-response, recurrence, or steroid-induced side effects.¹²⁻¹⁴ Cyclosporin A and prednisolone have been shown to be effective.¹⁵ Intravitreal corticosteroid injection has been found to be a promising alternative therapeutic option as compared to systemic therapy in CSC by inducing rapid remission with marginal systemic side effects. Antiviral and antituberculosis therapy has been used based on etiological association.¹²⁻¹⁴ It must be noted that success with immunosuppression, including alkylating agent therapy must be carried out with careful diagnosis of the disease due to its worsening of an infectious process.¹⁶

Outcomes

Even with treatment, the natural course of SC varies depending on how early treatment is initiated. Multiple recurrences of choroidal inflammation and progression over a period of months to years may eventually involve the fovea.¹⁷ The frequency of recurrences depends directly on the length of the follow up.¹⁷ About 50% of patients with SC are expected to have at least one recurrence in 5 years. It has been shown that in the absence of anti-inflammatory treatment, choroiditis can last up to 20 years or more, leaving extensive chorioretinal scarring and 88% of macula involvement. When the macula is involved there is a less favorable prognosis. CNV is the most dreaded and commonest complication associated with SC. The reported incidence of CNV in patients with SC ranges from 10% to 25%.^{18,19}

Conclusion

SC is a rare, recurrent, vision threatening, bilateral, mostly idiopathic disorder that can cause blindness. Tuberculosis has been named as the most common etiology in regions where it is endemic. In the United States it is much more rare, yet cases of SC may have been misdiagnosed. Newer imaging techniques and treatment options have helped to correctly diagnose this condition which may be cause of some emergence. As evolution of this condition takes place, therapeutic management must be cautioned with a thorough workup to rule out infections systemic conditions that could become worse after standard treatment.

Acknowledgements

None.

Funding

None.

Conflicts of interest

No conflicts.

References

- Henderly DE, Genstler AJ, Smith RE, et al. Changing patterns of uveitis. *Am J Ophthalmol.* 1987;103(2):131–136.
- Karagiannis DA, Sampat FV, Dowler J. Serpiginous choroidopathy with bilateral foveal sparing and good visual acuity after 18 years of disease. *Retina.* 2007;27(7):989–990.
- Ebrahimiadib N. A focus on the epidemiology of uveitis. *Ocul Immunol Inflamm.* 2018;26(1):2–16.
- Mirza RM, Lee MJ. White spot syndromes and related diseases. *Ryan's Retina.* 2018;79(1):1516–1561.
- Douglas AJ, Antoine PB, Ralph DL. The standardization of uveitis nomenclature (SUN) working group. Development of classification criteria for the uveitides. *Am J Ophthalmol.* 2021;228:126–133.
- Dutta Majumder P, Biswas J, Gupta A. Enigma of serpiginous choroiditis. *Indian J Ophthalmol.* 2019;67(3):325–333.
- Bansal R, Gupta A, Gupta V, Dogra M et al. Tubercular serpiginous like choroiditis presenting as multifocal serpiginoid choroiditis. *Ophthalmology.* 2012;119:2334–2342.
- Todd A, Piri N, Jusufbegovic D. Diagnosis and management of serpiginous choroiditis. *Eye Net Magazine.* 2019.
- Nazari Khanamiri H, Rao NA. Serpiginous choroiditis and infectious multifocal serpiginoid choroiditis. *Surv Ophthalmol.* 2013;58(3):203–232.
- M Cannel CA, Holland GN, Helm CJ, et al. Causes of uveitis in the general practice of ophthalmology. UCLA community based uveitis study group. *Am J Ophthalmol.* 1996;121(1):35–41.
- Gauthier A. Multifocal choroidopathy syndrome. *Medscape Drugs and Diseases.* 2021;1(22):1–5.
- Fonollosa A, Valsero S, Artaraz J, et al. Dexamethasone intravitreal implants in the management of tubercular multifocal serpiginoid choroiditis. *J Ophthalmic Inflamm Infect.* 2016;6(1):31.
- Jain L, Panda KG, Basu S. Clinical outcomes of adjunctive sustained-release intravitreal dexamethasone implants in tuberculosis-associated multifocal serpigenoid choroiditis. *Ocul Immunol Inflamm.* 2018;26(6):877–883.
- Agarwal A, Handa S, Aggarwal K, et al. The role of dexamethasone implant in the management of tubercular uveitis. *Ocul Immunol Inflamm.* 2018;26(6):884–892.
- Araujo AAQ, Wells AP, Dick AD, et al. Early treatment with cyclosporin in serpiginous choroidopathy maintains remission and good visual outcome. *British Journal of Ophthalmology.* 2000;84(9):979–982.
- Hooper PL, Kaplan HJ. Triple agent immunosuppression in serpiginous choroiditis. *Ophthalmology.* 1991;98(6):944–951.
- Munteanu G, Munteanu M, Zolog I. Serpiginous choroiditis – clinical study. *Oftalmology.* 2001;52(2):72–80.
- Abrez H, Biswas J, Sudharshan S. Clinical profile, treatment and visual outcome of serpiginous choroiditis. *Ocul Immunol Inflamm.* 2007;15(4):325–35.
- Kuo IC, Cunningham ET. Ocular neovascularization in patients with uveitis. *Int Ophthalmol Clin.* 2000;40(2):111–126.