

Comparison of astigmatism after phacoemulsification and extracapsular cataract extraction

Abstract

Objective: To compare astigmatism after phacoemulsification and extracapsular cataract extraction technique.

Method: It was a hospital-based cross-sectional study conducted at Zainab Medicare hospital Haroonabad from September 2018 to May 2019. A sample size of 80 patients having cataract, age 41 to 70 years was included in this study. Slit lamp examination was performed for anterior segment evaluation and astigmatism was determined with autorefractometry and keratometry.

Result: Phaco technique was more reliable. The means and the standard deviation of phaco post op astigmatism was 0.7860 ± 0.48880 and ECCE post op astigmatism was 3.6310 ± 1.96236 which indicated that the degree of astigmatism increases after extracapsular cataract extraction technique. The significant level was 0.00 which showed that the phaco technique is highly significant.

Conclusion: Corneal astigmatism was almost similar in two groups prior to surgery but after the cataract surgery the astigmatism significantly decreased after phacoemulsification group at 2 weeks follow-up, the results indicated that phaco may be considered superior to ECCE. No suturing is required in phaco and hence lesser chances of post op astigmatism.

Keywords: autorefractometer, extracapsular cataract extraction (ECCE), phacoemulsification, K readings, surgically induced astigmatism (SIA)

Volume 10 Issue 3 - 2020

Hafiza Humaira Yasmeen,¹ Iqra Khalil²¹University of Faisalabad, Pakistan²Aziz Fatima Hospital, Pakistan

Correspondence: Iqra Khalil, Aziz Fatima Hospital, House # 230-231 'Z' block Housing colony Haroonabad, Pakistan, Tel 0332-7070326, Email Dr.iqrakhalil@gmail.com

Received: February 25, 2020 | **Published:** June 26, 2020

Introduction

Astigmatism is an imperfection in the curvature of eye's cornea or lens. Normally, the Cornea and lens are smooth and curved equally in all directions. This helps to focus light rays sharply onto the retina. Due to astigmatism there is blur or distorted vision. Cataract surgery has undergone various advances since it evolved from ancient couching to the modern phacoemulsification cataract surgery. Surgically induced astigmatism is one of the most common complications after cataract surgery. The introduction of sutureless corneal incision has gained increasing popularity worldwide, because it offers several advantages over the traditional sutured limbal incision and scleral tunnel. A clear corneal incision has the benefit of being bloodless and having an easy approach, but surgically induced astigmatism (SIA) is still a concern.¹ Cataract surgery with implantation of an intraocular lens (IOL) is the most common surgical procedure. Over the past years, surgical technique has evolved from standard extracapsular to micro incision without suture. These progresses have allowed cataract surgery to be a less invasive procedure, with better and more predictable refractive results. So that, most patients have increased expectations about cataract surgery result.² Standard extracapsular cataract extraction (ECCE) involves the removal of a part of anterior capsule, manual expression of the nucleus through a large incision (9-10 mm) and aspiration of cortex, leaving behind the intact posterior capsule. The intraocular lens is inserted between the anterior and posterior capsule. Since the incision is large and 5-7 sutures are put to close it, there is some amount of astigmatism after healing and thus,

Visual improvement takes longer time following removal of the sutures. The removal of sutures is done after the three month of the surgery and vision is rechecked. Phaco is the most common

technique of cataract surgery. It involves the use of a machine with an ultrasonic hand piece equipped with a titanium or steel tip. The tip vibrates at ultrasonic frequency and the lens material is emulsified. Fragmentation into smaller pieces makes emulsification easier as well as the aspiration of cortical material. After the Phacoemulsification of the lens nucleus, a dual irrigation-aspiration probe is used to aspirate out the remaining peripheral cortical materials. The surgery is performed through a small cornea scleral wound (2.2-3.2 mm). The intraocular lens is folded and inserted using a lens injector through the small wound. Due to the small size of the incision and two-level openings, no suture is required. The healing process of wound is fast and the rehabilitation time is less. There is very little astigmatism and thus, visual improvement is faster allowing the patient to return to his work after few days.³ With increasing age, the horizontal corneal meridian becomes more curved than the vertical meridian leading to or increasing existing against-the-rule (ATR) astigmatism. Thus, there is an ATR shift in astigmatism with age. Placing an incision on the vertical meridian (superior approach) for a cataract patient with preoperative ATR astigmatism may cause further flattening of the already flatter vertical meridian and a corresponding steepening to the same degree of the already steeper horizontal meridian leading to high postoperative corneal astigmatism. Hence, the choice of the location of incision for these groups of patients is important.⁴

Research methodology

This was cross sectional study conducted at zainab Medicare hospital Haroonabad from September 2018 to May 2019. 80 patients (30 were male and 50 were female) included in this study of the age group between 41-70 years by non-probability convenient sampling technique. Patients having cataract with mild (0.5-0.75DC) degree

pre op corneal astigmatism were included. Patients with lid deformity (entropion and ectropion), corneal opacity, pterygium, uveitis, retinal diseases and glaucoma were excluded. This study involved the Performa having some measurements to predict the pre and post surgical astigmatism. Autorefractometer plus Keratometer used to measured the astigmatism before and after the cataract surgery. Data was analyzed using SPSS 20.0 software.

Results

The results of this study showed that the phacoemulsification leads to a better and more stable visual acuity due to negligible post surgical astigmatism. The total number of studied patients were 80, 30 (37.5%) were male and 50 (62.5%) were female. Individuals were grouped in 41-50 years, 51-60 years, and 61-70 years. The value of astigmatism was measured in four categories i.e. normal degree is less than 1, low degree ranges from 1-2, moderate degree 2-4 and high degree is greater than 4.

Age description

Table 1 This table showed that the 20 patients (25.0%) are between the 41-50 age group, 23 patients (28.8%) are between the 51-60 and 37 patients (46.3%) are between the age group of 61-70 years. This variation in graph indicated that the frequency of cataract increases with age.

Table 1 Age description

	Frequency	Percent
41-50	20	25
51-60	23	28.8
61-70	37	46.3
Total	80	100

Astigmatism categorization

Comparison between phaco pre op astigmatism and phaco post op astigmatism. The degree of astigmatism was measured in four categories i.e normal degree of astigmatism, low degree of astigmatism, moderate degree of astigmatism and higher degree of astigmatism. Normal degree is less than 1, low degree ranges from 1-2 moderate degree ranges from 2-4 degree and high degree is greater than 4.

Bar chart showed that the 19 patients have normal degree of astigmatism pre operatively while post operatively the no of patients increased up to 31. 15 patients have low degree of astigmatism pre operatively while decreases up to 9 patients posts operatively and 2 patients have moderate degree of astigmatism pre operatively which eliminates post operatively. This indicates that the astigmatic error decreased after phacoemulsification technique.

Comparison between ECCE pre op astigmatism and ECCE post op astigmatism

The value of astigmatism was measured in four categories i.e. normal degree is less than 1, low degree ranges from 1-2, moderate degree 2-4 and high degree is greater than 4. This bar chart showed that the 14 patients have normal degree of astigmatism pre operatively while no patients have normal degree of astigmatism post operatively,

19 patients shows the low degree of astigmatism pre operatively which decrease to 8 postoperatively, 5 patients have moderate degree of astigmatism pre operatively which increase up to 19 patients postoperatively and 2 patients have severe astigmatism which increase up to 13 patients postoperatively. This indicates that the value of astigmatism increases after ECCE technique.

Paired samples statistics

This table shows the association between phaco and ECCE in two pairs. 1st pair consist of phaco pre op and phaco post op astigmatism while the 2nd pair consists of ECCE pre op and post op astigmatism.

Descriptive statistics

Table 2 This table showed that the mean and standard deviation of pre and post phaco astigmatism as 1.3190±0.79160 pre-operative phaco and post-operative phaco is .7860±.48880 which indicate that the astigmatism reduced after the phaco emulsification technique. And pre and post ECCE astigmatism as 1.5743±.90099 pre operatively and 3.6310±1.96236 post operatively shows that the astigmatism increases after the extra capsular cataract extraction due to sutures. The mean and standard deviation increases from ECCE pre op to ECCE post op.

Table 2 Descriptive statistics

	Mean	N	Std. deviation	P(value)
Pair 1 phaco pre astigmatism	1.319	40	0.7916	0
Phaco post astigmatism	0.786	40	0.4888	
Pair 2 ECCE Pre op astigmatism	1.5743	40	0.90099	0.001
ECCE Post astigmatism	3.631	40	1.96236	

which indicates that the astigmatic error increases in ECCE and decreases in phacoemulsification technique. This table also showed the correlation between phaco pre and post op astigmatism and ECCE pre and post op astigmatism and the significant level in phaco pre and post operatively is 0.000 and pre and post operatively in ECCE is 0.001. Which indicates phaco is more superior to ECCE. The value of astigmatism decreases post operatively in phacoemulsification while the value of astigmatism increases post operatively in extracapsular cataract extraction. This showed that the phaco technique is more reliable and clinically superior to ECCE.⁵⁻¹⁰

Association between post phaco and post ECCE

ANOVA test was applied to check the association post operatively in phacoemulsification and extracapsular cataract extraction. Table 3 This table shows that the means and the standard deviation of phaco post op astigmatism as .7860±.48880 and ECCE post op astigmatism as 3.6310±1.96236 which indicated that the degree of astigmatism increases after extra capsular cataract extraction technique. The astigmatism after phacoemulsification is minimum or negligible. Table 4, this table shows that the significant level between the post operatively phaco astigmatism and post operatively ECCE astigmatism is .00 which indicates that the phaco technique is highly significant. Thus the phacoemulsification technique is more reliable and superior to extra capsular cataract extraction (Figures 1&2).

Table 3 Anova

	Mean	Std. deviation	Std. error
Phaco post op astigmatism	0.786	0.4888	0.07729
ECCE post op astigmatism	3.631	1.96236	0.3101028
Total	2.2085	2.01696	0.2255

Table 4 Significant level between the post operatively phaco astigmatism and post operatively ECCE astigmatism

Data	Sum of squares	Df	Mean square	F	Sig.
Between groups	161.881	1	161.881	79.164	0
Within Groups	159.501	78	2.045		
Total	321.381	79			

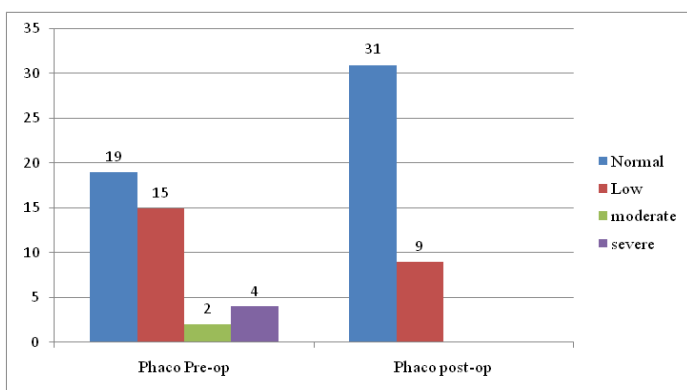


Figure 1 Phaco pre op astigmatism and phaco post op astigmatism.

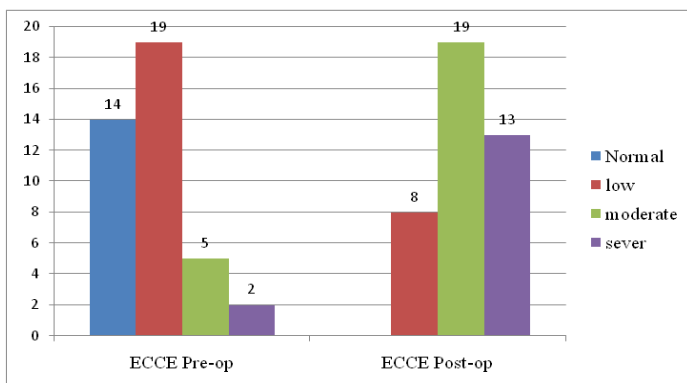


Figure 2 ECCE pre op astigmatism and ECCE post op astigmatism.

Discussion

Eye is the most important sense organ of the body used for vision. 80% information about environment received through the eye. Astigmatism is irregularly shaped or sometimes because of the curvature of the lens inside the eye. It is a type of refractive error in which the eye does not focus light evenly on the retina. This results in the distorted or blurred vision at any distance. Cornea and lens focus light rays sharply onto the retina. Cataract surgery has undergone various advances since it was evolved from ancient couching to the modern phacoemulsification cataract. Surgically induced astigmatism (SIA) remains one of the most common complications. Cataract surgery with implantation of an intraocular lens (IOL) is the most

common surgical procedure. Standard ECCE involves the removal of a part of anterior capsule, manual expression of the nucleus through a large corneoscleral incision (9-10 mm) and aspiration of Cortex, leaving behind the intact posterior capsule. The intraocular lens is inserted between the anterior and posterior capsule and sutures are put to closed the wound. Phaco is the most common technique of cataract surgery performed under local anaesthesia. It involves the use of a machine with an ultrasonic hand piece equipped with a titanium or steel tip. The surgery is performed through a small corneoscleral wound (2.2-3.2 mm). The intraocular lens is folded and inserted using a lens injector through the small wound. Due to the small size of the wound and two level openings in the wound, no suture is required. The healing process of wound is fast and the rehabilitation time is less. There is no/very little astigmatism and thus, visual improvement is faster. Veronica et al. (2016) investigated the changes of cataract induced astigmatism caused by the incision after cataract surgery may be calculated to achieve better visual outcome. SIA could be determined as the difference between preoperative and postoperative keratometry 5. Results of study by Veronica agreed with my results in such a way that corneal incision causes the astigmatism and phacoemulsification require smaller incision with the less post surgical astigmatism. A study was conducted by on the effect of incision size on early postoperative visual rehabilitation after cataract surgery and intraocular lens implantation 151 cataract patients were randomly assigned intraocular lens inserted through 3.5 mm incision 5x6 mm oval optic lens inserted through 5.6 mm incision at one week postoperatively follow up, 62 % of 3.5 mm incision cases had uncorrected visual acuity of 20/40, 33 % of 5.5 mm and 43% of 6.5 mm incision cases. The 3.5mm incision case had significant less total keratometric cylinder than other cases all the postoperative examination and less surgically induced cylinder at two days and one week post operatively. The 5.5 mm and 6.5 mm cases did not differ significantly in visual acuity or astigmatism at any examination 6. This study favors to my study strongly.¹¹⁻¹³

Conclusion

My study indicates that in terms of astigmatism, Phacoemulsification is clinically superior to ECCE and phaco must be preferred over ECCE in order to achieve desired post op outcomes. Phaco require a smaller incision with the expected advantages of less post surgical astigmatism, corneal astigmatism is almost similar in two groups prior to surgery. The mean keratometric cylinder which is similar in to groups pre-operatively was significantly less in phaco than in the conventional ECCE groups at 2 weeks follow up, The means and the standard deviation of phaco post op astigmatism was .7860 ±.48880 and ECCE post op astigmatism was 3.6310±1.96236 which indicated that the degree of astigmatism increases after extra capsular cataract extraction technique, the significant level between the posts operatively phaco astigmatism and post operatively ECCE astigmatism is .00 which indicates that the phaco technique is highly significant. None of the eye in phacoemulsification group requires removal of sutures for higher corneal astigmatism. Thus, surgical incision affects the vision and cause astigmatism.

Acknowledgments

None.

Funding

The author has no financial/property interests to disclose.

Conflicts of interest

Author declares that there is no conflict of interest.

References

1. Nikose A, Saha D, Laddha P, et al. Surgically induce astigmatism after phacoemulsification by temporal clear corneal and superior clear corneal approach: a comparison. *Clinical Ophthalmology*. 2018;12:65–70.
2. Garcia Lopez V, Garcia Lopez C, de Juan V, et al. Analysis of cataract surgery induced astigmatism: Two polar methods comparison. *Journal of Optometry*. 2017;10(4):252–257.
3. T Thevi C. Outcome of phacoemulsification and extracapsular cataract extraction: A study in a district hospital in Malaysia. *Malays Fam Physician*. 2014;9(2):41–7.
4. Arthur E, Sadik A, Kumah D, et al. Postoperative Corneal and Surgically Induced Astigmatism following Superior Approach Manual Small Incision Cataract Surgery in Patients with Preoperative Against-the-Rule Astigmatism. *Journal of Ophthalmology*. 2016. p. 1–7.
5. Kawahara A, Takayanagi Y. Comparison of refractive and keratometric astigmatism after microincision cataract surgery. *Journal of Cataract & Refractive Surgery*. 2017;43(8):1050–1053.
6. El-Maghraby A, Anwar M, El-Sayyad F, et al. Effect of incision size on early postoperative visual rehabilitation after cataract surgery and intraocular lens implantation. *Journal of Cataract & Refractive Surgery*. 1993;19(4):494–498.
7. Theodoulidou S, Asproudis I, Kalogeropoulos C, et al. The role of sideport incision in astigmatism change after cataract surgery. *Clinical Ophthalmology*. 2015. p. 1421.
8. Wei Y, Chen W, Su P, et al. The influence of corneal wound size on surgically induced astigmatism after phacoemulsification. *Journal of the Formosan Medical Association*. 2012;111(5):284–289.
9. Kavitha K, Kishore A, Reddy G, et al. Comparative study of surgically induced astigmatism in superior versus temporal incision in small incision cataract surgery case. *International Journal of Research in Medical Sciences*. 2015. p. 3027–3031.
10. Ravindran NVL, George T. Comparison of surgically induced astigmatism in corneo-scleral and clear corneal incision in phacoemulsification. *International Journal of Research in Medical Sciences*. 2015. p.3812–3818.
11. Kavitha K, Kishore A, Reddy G, et al. Comparative study of surgically induced astigmatism in superior versus temporal incision in small incision cataract surgery case. *International Journal of Research in Medical Sciences*. 2015. p.3027–3031.
12. Patil P, Radhakrishnan O, Rajappa N, et al. Evaluation and comparison of surgically induced astigmatism between phacoemulsification and small incision cataract surgery. *Sudanese Journal of Ophthalmology*. 2013;5(2):67.
13. Tejedor J, Pe´rez-Rodríguez J. Astigmatic Change Induced by 2.8-mm Corneal Incisions for Cataract Surgery. *Investigative Ophthalmology & Visual Science*. 2009;50(3):989.