

# Clinical peculiarities in challenging cases of atypical retinitis pigmentosa: a case series and review of the literature

## Abstract

We report three distinct cases who presented initially as age-related macular degeneration, intermediate uveitis, and cystoid macular edema respectively. They were later diagnosed to have atypical retinitis pigmentosa. Clinical presentation, full field perimetry, fundus photography, electroretinography, fundus fluorescein angiography and optical coherence tomography are described in detail for all three patients. The course of their disease and treatment during the period of observation are discussed with complete photo-documentation. Since the fundus may appear clinically normal in such cases, the diagnosis may be missed. So, these cases pose a diagnostic challenge to the ophthalmologist.

**Keywords:** age-related macular degeneration, atypical retinitis pigmentosa, cystoid macular edema, uveitis

Volume 8 Issue 3 - 2018

Saurabh Deshmukh, Hemalata Deka, Harsha Bhattacharjee, Dipankar Das, Krati Gupta  
Sri Sankaradeva Nethralaya, India

**Correspondence:** Saurabh Deshmukh, DNB Ophthalmology Resident, National Board of Education, India Sri Sankaradeva Nethralaya, 96, Basistha Road, Beltola, Guwahati, Assam, India, Tel +91-80850-55990, Email dr.saurabh89@gmail.com

**Received:** June 08, 2018 | **Published:** June 20, 2018

## Introduction

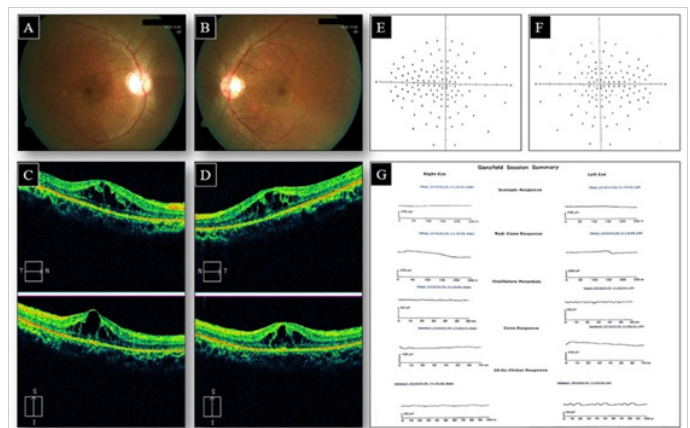
Retinitis pigmentosa (RP) is a heterogeneous group of inheritable disorders affecting photoreceptors and retinal pigment epithelium (RPE) which gradually leads to nyctalopia and visual field constriction. Typical features include pigmentation (bony spicules), waxy optic disc pallor and arteriolar attenuation.<sup>1</sup> Atypical RP is a subtype of RP where these typical features are absent. So, diagnosing these cases purely on the basis of ophthalmoscopic findings is more difficult than typical RP cases since fundus examination may be unremarkable and the diagnosis may be missed.<sup>2</sup> Thus, these cases pose a diagnostic challenge to the ophthalmologist. We report here three well-documented challenging cases of atypical RP; in all cases, the initial diagnosis was either age-related macular degeneration (ARMD) or intermediate uveitis or cystoid macular edema (CME). To the best of our knowledge, this case series is first of its kind in Indian literature.

## Case reports

### Case 1

A 21-year-old male presented with diminution of vision (DOV) in both eyes for four years. On examination, his best corrected visual acuity (BCVA) was 20/40 in both eyes (OU). Anterior segment biomicroscopy and intraocular pressure (IOP) were normal with no relative afferent pupillary defect (RAPD) while fundus examination revealed a dull foveal reflex, CME and RPE defects OU (Figure 1A) (Figure 1B). Optical coherence tomography (OCT) confirmed CME, subfoveal intraretinal cysts OU with a central subfoveal mean thickness of 446µm in the right eye (OD) and 436µm in the left eye (OS) (Figure 1C) (Figure 1D). The patient was started on oral acetazolamide 250mg every 8 hourly. No CME reduction or VA improvement was observed after treatment. On subsequent visit vessel attenuation was observed, so atypical RP was suspected and the patient was advised full field 120-point Humphrey perimetry (HVF) and electroretinography (ERG). A full-field HVF demonstrated residual central visual field

OU (Figure 1E), (Figure 1F). ERG showed flat line response in both photopic and scotopic phases OU (Figure 1G). Pedigree analysis showed no genetic correlation.

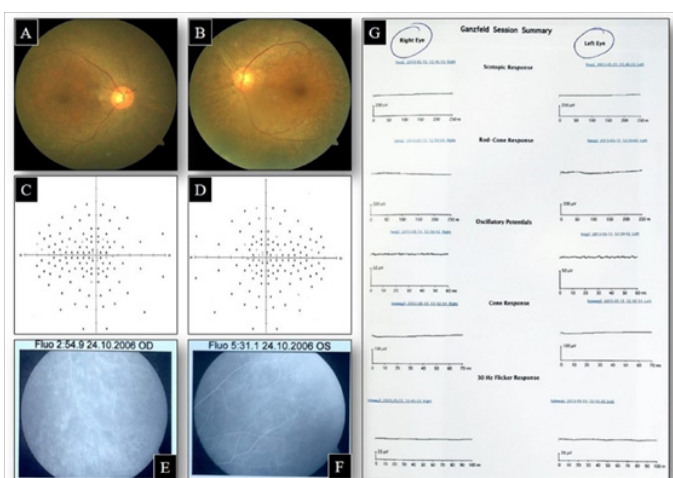


**Figure 1** Colour fundus images OD (A) and OS (B) showing dull greyish foveal reflex suggestive of Cystoid Macular Oedema with vascular attenuation OU. OCT macula OD (C) and OS (D) showed intraretinal cystic spaces suggestive of CME in both eyes with CSMT of 446µm OD and 436µm OS. Full-field 120-point HVF OD (E) and OS (F) showing residual central visual field. ERG OD and OS (G) showing an extinguished response.

### Case 2

A 50-year-old female presented with painless progressive DOV and floaters OD for 1 month. Her BCVA was 20/50 OD and 20/20 OS. Anterior segment slit lamp examination was unremarkable with normal IOP. Fundus examination revealed vitritis, snow banking with optic disc edema. So, a diagnosis of intermediate uveitis with optic disc involvement OD was made. The patient was advised Complete Blood Count (CBC), Erythrocyte Sedimentation Rate (ESR), antinuclear antibodies (ANA), Venereal Disease Research Laboratory (VDRL) test, Mantoux skin test, chest X-ray and serum angiotensin converting enzyme (ACE). ESR was raised; CBC and ACE levels

within normal limit and rest of the tests were negative. So, the patient was started on pulse intravenous methylprednisolone (1gm daily for 3 days) followed by oral steroids (1gm/kg bodyweight) in a tapering dose. On the subsequent visit, the vision improved to 20/32 OD with the resolution of disc edema. The patient was on regular follow up thereafter. About three years after the initial attack of uveitis, during a routine follow up visit, the fundus examination revealed arteriolar narrowing with RPE defects which was photo documented (Figure 2A) (Figure 2B). The full-field HVF showed a residual small central island of vision OU (Figure 2C) (Figure 2D). Fundus fluorescein angiography (FFA) showed patchy hyperfluorescence due to window defects in the areas of RPE defects (Figure 2E) (Figure 2F). ERG showed a barely detectable response OU (Figure 2G). Family history was not significant. Thus, the patient was diagnosed to have atypical RP which initially presented as intermediate uveitis.



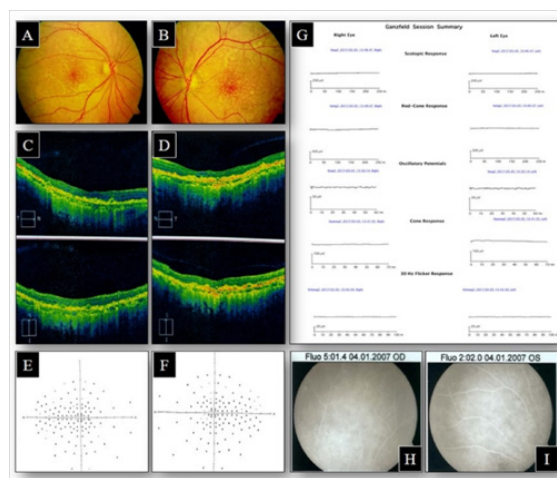
**Figure 2** Colour fundus photographs at follow up after resolution of optic disc swelling OD (A) and OS (B) showing few RPE defects at the macula OU. Full-field 120-point HVF showing loss of peripheral visual field OU (C) and (D). FFA OD (E) and OS (F) showing RPE defects at the periphery. ERG OU (G) showing an extinguished response.

### Discussion

RP is a diverse group of heritable retinal diseases which receives its characteristic name from the pigment epithelial alterations which occur in the mid-periphery of the retina. Most cases have the presence of these characteristic peripheral pigmentary changes thereby making the diagnosis of RP straightforward. But in atypical RP cases, fundus examination may be unremarkable because of the absence of the characteristic pigmentary changes, particularly during the early stages of the disease. These cases with absent pigmentation could represent an extreme pattern of RP.<sup>3</sup> In all the three cases reported herein, the only red flag sign which made us think of RP as a differential diagnosis was vessel narrowing or attenuation. CME is a known complication and seen in 10-20% of patients of RP.<sup>4</sup> The first case presented initially with CME and later diagnosed as RP. For CME secondary RP, carbonic anhydrase inhibitors are considered a mainstay treatment, but many cases do not respond, as seen in our case.<sup>5</sup> Other treatment modalities include intravitreal triamcinolone injection and intravitreal anti-vascular endothelial growth factor.<sup>6</sup>

### Case 3

A 62-year-old female presented with a history of painless, progressive DOV OU accompanied by nyctalopia, first noticed at age 30. She was diagnosed elsewhere to have ARMD. Her BCVA was 20/80 OD and 20/50 OS. Anterior segment slit lamp examination was unremarkable, with normal IOP. Fundus examination showed small clusters of drusens in macular area with narrowing of arterioles OU (Figure 3A) (Figure 3B). Pedigree analysis showed no genetic correlation. OCT showed hyper-reflective irregular nodules beneath the RPE, located on or within the Bruch membrane suggestive of early ARMD (Figure 3C) (Figure 3D). HVF full field analysis showed restricted visual field OU (Figure 3E) (Figure 3F) and ERG showed a flat response (Figure 3G) and. FFA revealed RPE defects in the posterior pole (Figure 3H) (Figure 3I). So, a diagnosis of atypical RP with early ARMD was made.



**Figure 3** Colour fundus images OD (A) and OS (B) showing small clusters of drusens in macular area OU. OCT macula OD (C) showing typical cuticular drusen with saw tooth appearance and OS (D) showing combined typical and atypical cuticular drusen. Full-field 120-point HVF OD (E) and OS (F) showing the preserved central island in both eyes. ERG OU (G) showing an extinguished response. FFA OD (H) and OS (I) showing RPE defects at the periphery.

Our second patient initially diagnosed as intermediate uveitis because of the presence of vitritis and pars planitis. A similar case was reported by Szabo et al.,<sup>7</sup> in which the diagnosis was eventually made on the basis of ERG response. Therefore, the clinicians should be alert to various manifestations of RP, including mild inflammation, to avoid possible confusion with uveitis. The third case is atypical because it presented with early ARMD and later diagnosed as RP. Sarraf et al.,<sup>8</sup> suggested that there could be a currently unidentified gene mutation that could be responsible for both forms of retinal degeneration, that is, ARMD and RP. Management of the patient with atypical RP includes periodic comprehensive eye examinations with the best possible spectacle prescription, threshold visual fields to monitor progress, and sun filters to block shorter wavelength light when necessary. Low vision aids can be of great help to these patients and use of a simple pen torch to overcome dark adaptation difficulties. Gene therapy and retinal implants are under research across various centers around the world. Many techniques, surgical procedures, and medications have been used, but none has proved to be valuable at this point. It is thus very important to counsel these patients and educate

them on the nature of the disease and its prognosis. This case series thus highlights the potential of atypical RP to mimic other ocular disorders.

## Acknowledgements

We would like to thank Sri Kanchi Sankara Health and Educational Foundation, Guwahati, India.

## Conflict of interest

The author declares that there is no conflict of interest.

## References

1. Natarajan S. Retinitis pigmentosa: A brief overview. *Indian J Ophthalmol*. 2011;59(5):343–346.
2. Tong JM, Chan CK, Leung DY. Retinitis pigmentosa sine pigmento masquerading as normal tension glaucoma. *J Curr Glaucoma Pract*. 2009;3(2):60–61.
3. Hatta M, Hayasaka S, Kato T, et al. Retrobulbar optic neuritis and rhegmatogenous retinal detachment in a fourteen-year-old girl with retinitis pigmentosa sine pigmento. *Ophthalmologica*. 2000;214(2):153–155.
4. Ozdemir H, Karacorlu M, Karacorlu S. Intravitreal triamcinolone acetonide for treatment of cystoid macular oedema in patients with retinitis pigmentosa. *Acta Ophthalmol Scand*. 2005;83(2):248–251.
5. Apushkin MA, Fishman GA, Grover S, et al. Rebound of cystoid macular edema with continued use of acetazolamide in patients with retinitis pigmentosa. *Retina*. 2007;27(8):1112–1118.
6. Moustafa GA, Moschos MM. Intravitreal aflibercept (Eylea) injection for cystoid macular edema secondary to retinitis pigmentosa - a first case report and short review of the literature. *BMC Ophthalmol*. 2015;15:44.
7. Szabo E, Brichova M, Liskova P, et al. Retinitis pigmentosa mimicking uveitis. A case report. *Cesk Slov Oftalmol*. 2013;69(1):32–36.
8. Sarraf D, Salib DM, Jain A, et al. The coexistence of age-related macular degeneration and retinitis pigmentosa in three unrelated families. *Semin Ophthalmol*. 2007;22(3):155–161.